


Research Article

Hepatoprotective Effects of Ajwa Seed Oil Against CCl₄-Induced Acute Liver Injury in Mice

Abdulrahman A. Aljabri^{1,*}, Turki Hathal Alfahaidi¹, Amer Fadhi Alarawi¹,
Suhayb W. Alamri¹, Faris S. Alnezary², Mohammed H. Alsubhi¹,
Ammar Abdulraheem Bahauddin¹, Abdulrahman G. Alharbi¹, Heba M. Zahid^{3,4},
Lujain A. Almohammadi¹, Bandar D. Alrehaili¹, Heba Eltahir¹

¹Department of Pharmacology and Toxicology, College of Pharmacy, Taibah University, 41477 Madinah, Saudi Arabia

²Department of Pharmacy Practice, College of Pharmacy, Taibah University, 41477 Madinah, Saudi Arabia

³Department of Clinical Laboratory Sciences, College of Applied Medical Sciences, Taibah University, 41477 Madinah, Saudi Arabia

⁴Health and Life Research Center, Taibah University, 41477 Madinah, Saudi Arabia

*Correspondence: ajjabri@taibahu.edu.sa (Abdulrahman A. Aljabri)

Academic Editor: Mehmet Ozaslan

Submitted: 11 December 2025 Revised: 25 February 2026 Accepted: 10 March 2026 Published: 24 April 2026

Abstract

Background: As a major metabolic organ, the liver is constantly exposed to toxic substances. Although the flesh and seeds of Ajwa dates have been established to have antioxidant and anti-inflammatory properties, the hepatoprotective potential of Ajwa seed oil (ASO) against CCl₄-induced damage has yet to be ascertained. **Methods:** Twenty-four adult male mice were randomly assigned to one of four groups (n = 6 per group): control (oral saline for 12 days), CCl₄-treated [saline for 12 days plus a single dose of CCl₄ dissolved in corn oil 1:1 (1 mL/kg)], CCl₄ + ASO (100 mg/kg ASO administered daily for 12 days, followed by CCl₄), and CCl₄ + silymarin (100 mg/kg silymarin administered daily for 12 days, followed by CCl₄). Blood and liver samples were collected 24 h after CCl₄ administration for biochemical and histological analyses. **Results:** ASO treatment substantially reduced CCl₄-induced liver damage by restoring normal serum liver enzyme levels (alanine aminotransferase, aspartate aminotransferase, and lactate dehydrogenase; $p < 0.05$), lowering elevated levels of cholesterol and triglycerides, and increasing albumin levels ($p < 0.05$). The treatment significantly reduced lipid peroxidation, as evidenced by decreased malondialdehyde levels ($p < 0.0001$), and concurrently restored the total antioxidant capacity. Histological analysis revealed the preservation of liver architecture, reduced collagen deposition, and maintenance of glycogen storage ($p > 0.05$). **Conclusion:** Our findings in this study revealed that ASO has beneficial hepatoprotective effects against CCl₄-induced injury, which can be attributed largely to its antioxidant properties, as evidenced by restored total antioxidant capacity and reduced lipid peroxidation. Anti-inflammatory mechanisms may also contribute, as suggested by the histological reduction in inflammatory cell infiltration; however, direct measurement of inflammatory biomarkers warrants investigation in future studies.

Keywords: Ajwa seed oil; hepatoprotective; carbon tetrachloride; oxidative stress; liver injury

1. Introduction

As a major metabolic organ, the liver plays pivotal roles in detoxification, protein synthesis, and the regulation of glucose levels [1]. However, although the liver has unique regenerative capacities, the excessive consumption of alcohol or drugs and ingestion of other environmental xenobiotics can potentially cause severe hepatic damage, including hepatic fibrosis, cirrhosis, and hepatocellular carcinoma [2,3]. Oxidative stress and inflammation have been established to be the primary factors contributing to the induction and propagation of liver injury, and thus suppressing these events may provide the key to controlling and mitigating their damaging effects [4–6].

A mounting body of evidence indicates that different types of liver injury can be prevented using antioxidant-rich natural products, owing to their capacities to eliminate oxidative stress and hence suppress inflammatory re-

sponses [7–9]. In recent years, a growing number of studies have specifically demonstrated the hepatoprotective potential of plant-derived oils, phenolic extracts, and flavonoid-rich fractions in experimental models of liver toxicity [10, 11]. These phytoingredients have been shown to attenuate CCl₄-induced hepatotoxicity through multiple mechanisms, including activation of the Nrf2/Keap1 antioxidant signaling pathway, suppression of NF- κ B-mediated pro-inflammatory cytokine production, and inhibition of lipid peroxidation [12,13]. Furthermore, comparative investigations have established that several plant-derived compounds confer hepatoprotection comparable to that of silymarin, the clinical reference standard, supporting their potential as accessible and well-tolerated alternatives [14,15]. Ajwa (*Phoenix dactylifera*) seed oil (ASO) has emerged as a particularly promising therapeutic candidate. ASO contains notable amounts of phenolic compounds, flavonoids, and essential fatty acids, which contribute to combating ox-



oxidative stress, cytokine production, and an imbalance in hepatic enzymes [10,16]. The oil has been shown to reduce lipid peroxidation, promote antioxidant enzyme activity, and restore histopathological features of the liver following petrochemical-induced liver damage [17].

Carbon tetrachloride (CCl₄) is often used experimentally to induce hepatic injury in animals for evaluation of the hepatoprotective properties of drugs of interest. The toxicity induced by CCl₄ is associated with the generation of trichloromethyl free radicals, which contribute to oxidative damage, lipid peroxidation, and death of hepatic cells [18,19]. In this study, we assessed the capacity ASO to confer protection against CCl₄-induced acute liver damage, with the efficacy being compared with that of silymarin, a well-established hepatoprotective drug [20]. Collectively, the findings of this study will contribute to enhancing our understanding of the properties of ASO as a source of antioxidants in managing liver injury and thereby augment the growing body of evidence on the potential use of natural products as hepatoprotective agents.

2. Materials and Methods

2.1 Animals

Twenty-four adult male BALB/c mice were selected from the animal house facility at the College of Pharmacy, Taibah University, Madinah. Prior to the initiation of experimental procedures, the mice were habituated for 1 week under controlled environmental conditions (25 ± 2 °C, 12-h light/dark cycle) with unrestricted access to standard animal chow and water. The project was ethically approved by the research ethics committee of the College of Pharmacy- Taibah University (Project Reference Number COPTU-REC-122-20250128) and complied with both national and internationally recognized standards for the care and management of laboratory animals, including the ARRIVE guidelines (Animal Research: Reporting of *In Vivo* Experiments) and the Guide for the Care and Use of Laboratory Animals (8th edition, National Research Council, 2011).

2.2 Experimental Design

The experimental design was adapted from established CCl₄-induced hepatotoxicity models [18,19] and our previous work with date seed oil [21], with modifications specific to our objectives

The 24 mice were randomly assigned to one of the following four groups (n = 6 per group). Group 1 mice (serving as controls) received saline orally for 12 consecutive days. Group 2 mice received saline for 12 days, and 2 h after the final dose, the mice were administered CCl₄ in corn oil (1:1) via intraperitoneal injection (1 mL/kg). Group 3 mice received a daily oral dose of ASO (100 mg/kg) for 12 days, followed by a single intraperitoneal dose of CCl₄ (1 mL/kg) 2 h after the final dose. The 100 mg/kg dosage was selected based on preliminary dose-assessment stud-

ies (evaluating doses ranging from 50 to 200 mg/kg) conducted in our laboratory and previously published research [21]. This dose has been shown to provide substantial antioxidant activity in rodent models in the absence of any marked toxicity. Group 4 mice received a daily oral dose of silymarin (100 mg/kg) for 12 days, followed by a single CCl₄ injection 2 h after the final dose. At 24 h post-CCl₄ administration, the animals were humanely euthanized under anesthesia induced with ketamine (100 mg/kg IP) and xylazine (10 mg/kg IP). Euthanasia was performed using a gradual-fill CO₂ procedure in accordance with institutional and international guidelines. Cervical dislocation was applied as a secondary physical method to ensure death. Blood was collected by intracardiac puncture, and serum was subsequently separated. Liver samples were collected and rinsed in saline, and thereafter divided into two portions, one of which was used for tissue homogenization to measure the level of malondialdehyde (MDA) and total antioxidant (TAO) activity and the other for histopathological investigation.

A 12-day pre-treatment period was selected based on the previously established time considered necessary for the bioactive constituents of ASO to reach steady-state tissue levels and optimize the efficacy of endogenous antioxidant defense systems in hepatic tissue [21,22]

2.3 Chemicals and Reagents

CCl₄ was obtained from Sigma-Aldrich and silymarin was sourced from Indena (Settala, Italy). Unless otherwise stated, all other chemicals and reagents were procured from Sigma-Aldrich.

2.4 ASO Extraction

Botanical Authentication: Ajwa dates (*Phoenix dactylifera* L., family Arecaceae) were acquired from a certified local supplier in Al-Madinah Al-Munawwarah, Saudi Arabia. Ripe whole fruits free from any irregularities, infections or damage were selected and cleaned for the purpose of seed collection. Following a previously described procedure [21], the seeds were thoroughly cleaned to eliminate any remaining fruit pulp, followed by washing and drying at moderate heat. Thereafter, the seeds were ground into a fine powder, which was maintained at 4 °C prior to use.

Having initially been sifted, the date seed powder was extracted overnight in a sealed container by mixing 20 g of powder with 500 mL of methanol at 40 °C on a magnetic stirrer. This extraction process was performed a total of three times, following which, the solvent was evaporated using a Soxhlet apparatus over 6 h, with an oil yield of approximately 8% relative to the seed powder dry weight.

2.5 Measurements of Serum Biomarkers

Serum was separated from clotted samples of blood collected from mice by centrifuging at 3000 ×g for 15 min.

Table 1. Semi-quantitative histopathological scoring.

| Parameter | Control | CCl ₄ | CCl ₄ + ASO | CCl ₄ + Silymarin |
|------------------------------|-----------|------------------|------------------------|------------------------------|
| Hepatocellular necrosis | 0.2 ± 0.1 | 2.8 ± 0.2** | 0.4 ± 0.1# | 0.3 ± 0.1# |
| Inflammatory infiltration | 0.3 ± 0.1 | 2.6 ± 0.3** | 0.5 ± 0.2# | 0.4 ± 0.1# |
| Sinusoidal congestion | 0.1 ± 0.1 | 2.4 ± 0.2** | 0.3 ± 0.1# | 0.3 ± 0.1# |
| Vacuolar degeneration | 0.2 ± 0.1 | 2.7 ± 0.3** | 0.4 ± 0.1# | 0.4 ± 0.2# |
| Early collagen accumulation* | 0.3 ± 0.1 | 2.3 ± 0.2** | 0.5 ± 0.1# | 0.4 ± 0.1# |
| Glycogen content | 2.9 ± 0.1 | 0.4 ± 0.2** | 2.7 ± 0.2# | 2.8 ± 0.1# |
| Total pathology score | 1.1 ± 0.3 | 12.8 ± 0.9** | 2.1 ± 0.4# | 2.0 ± 0.3# |

*Collagen accumulation observed at 24 hours post-CCl₄ administration represents an acute-phase extracellular matrix response and early hepatic stellate cell activation, not established fibrosis. True hepatic fibrosis requires repeated or chronic CCl₄ exposure over several weeks. This parameter is therefore interpreted as an early fibrogenic signal, and the term ‘collagen deposition’ is used descriptively to reflect Masson’s trichrome staining findings rather than to imply frank fibrosis. Values represent mean ± SEM (n = 6). ***p* < 0.05 vs. control group; #*p* < 0.05 vs. CCl₄ group.

The serum levels of triglycerides (TG; Cat. No. TR210), total cholesterol (Cat. No. CH200), albumin (Cat. No. AB362), alanine aminotransferase (ALT; Cat. No. AL146), aspartate aminotransferase (AST; Cat. No. AS3804), and lactate dehydrogenase (LDH; Cat. No. LD2980) were assessed using commercially available kits in accordance with the manufacturer’s instructions (Randox®, Randox Labs, UK). Levels of the products of lipid peroxidation in serum (quantified as MDA: cat. no. MD-2529; Bio-Diagnostic) and TAO activity (cat. no. TA-2513; Bio-Diagnostic) were measured according to the manufacturer’s instructions. It should be noted that the TAO values reported throughout the Results and Discussion sections were derived exclusively from this TA-2513 assay, which quantifies total antioxidant capacity colorimetrically based on the ability of the sample to inhibit the oxidation of a reference substrate.

2.6 Histology

Extracted liver tissues were initially fixed overnight in 10% formalin (w/v in phosphate-buffered saline) at 4 °C. Tissues underwent conventional histological processing prior to being fixed in paraffin and sectioned at a thickness of 5 µm. Sections were deparaffinized, rehydrated in a graded alcohol series, and stained with hematoxylin and eosin (H&E) to assess overall liver morphology and with Masson’s trichrome to determine collagen deposition and fibrosis. Stained sections were examined under a light microscope to assess differences in hepatocellular damage and structural changes among the experimental groups.

Histopathological Scoring System

Liver tissue sections were evaluated by a blinded, board-certified pathologist using a semi-quantitative scoring system. Histopathological parameters were scored from 0 to 3 as follows: 0 = absent/normal, 1 = mild, 2 = moderate, and 3 = severe. The assessed parameters included hepatocellular necrosis, inflammatory cell infiltration, sinusoidal congestion, vacuolar degeneration, and collagen deposition in Masson’s trichrome-stained sections.

Glycogen content in PAS-stained sections was scored using a reverse scale: 0 = severe depletion, 1 = mild depletion, 2 = moderate retention, and 3 = abundant/normal glycogen.

Total histopathological scores were calculated by summing the individual parameter scores for each animal. For each parameter, at least 10 random high-power fields (×400 magnification) per section were examined, and the mean score was recorded for statistical analysis (Table 1).

2.7 Statistical Analysis

All data are expressed as the means ± standard error of the mean (SEM) derived from six animals per group. The data were initially assessed for normality and homogeneity of variance using the Shapiro–Wilk test and Levene’s test, respectively. Statistical comparisons between groups were performed using a one-way analysis of variance (ANOVA) followed by Tukey’s post hoc test for multiple pairwise comparisons when ANOVA indicated significant differences. A *p*-value of less than 0.05 was considered statistically significant. All statistical analyses were performed using GraphPad Prism version 10.4.1. software (GraphPad Software, San Diego, CA, USA).

3. Results

3.1 Effects of ASO on Serum Liver Biomarkers

To assess hepatocyte integrity, the levels of ALT, AST, and LDH were measured in the serum of blood collected from mice in the different treatment groups. Compared with levels detected in the control group mice, treatment with CCl₄ was observed to promote significant increases in the levels of serum ALT, AST, and LDH (*p* < 0.0001; Fig. 1). In response to the administration of ASO, we detected significant reductions in the elevated levels of ALT, AST, and LDH induced by CCl₄, effectively restoring these enzymes to levels that did not differ significantly from those in the healthy control mice and the silymarin-treated

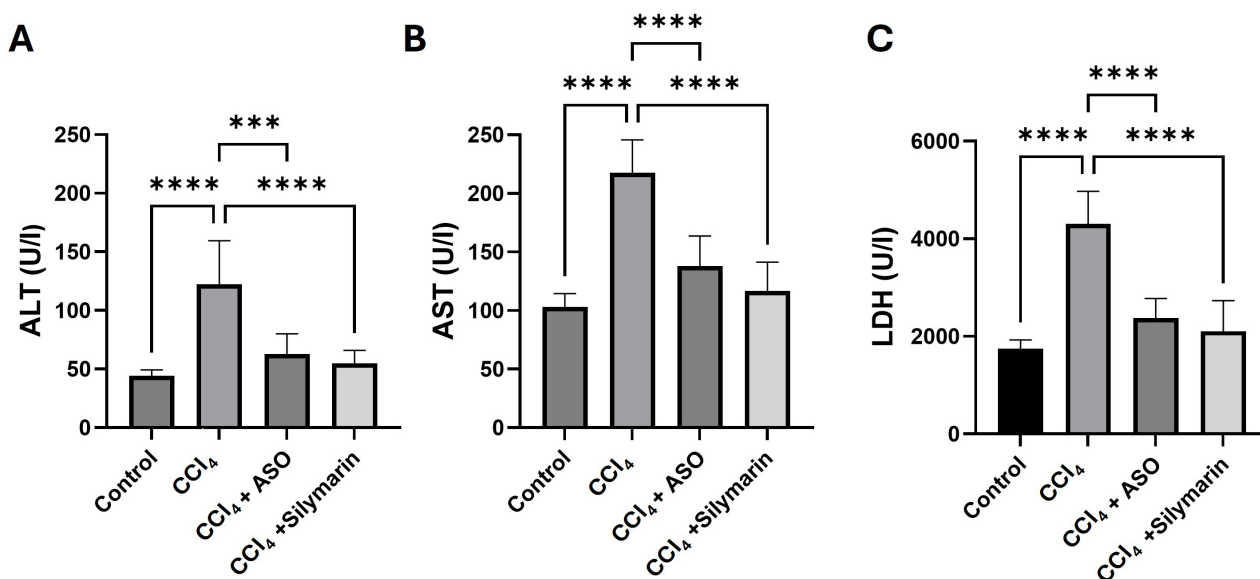


Fig. 1. Effects of ASO on serum liver biomarkers. (A–C) Serum biomarkers of different treatment groups. Data are presented as the means \pm SEM (n = 6). *** $p < 0.001$ and **** $p < 0.0001$ between the indicated groups. U, units; ALT, alanine aminotransferase; AST, aspartate aminotransferase; LDH, lactate dehydrogenase; ASO, Ajwa seed oil.

mice ($p > 0.05$ for both comparisons; Fig. 1), thereby indicating the complete normalization of liver enzyme markers.

3.2 Effects of ASO on Serum Cholesterol, Triglycerides, and Albumin

Serum levels of cholesterol, triglycerides, and albumin, which are widely examined as biomarkers indicative of hepatocellular injury and impaired synthetic function, were measured to determine the effects of different treatments on liver biosynthetic capacity. Administration of CCl₄ led to marked increases in the levels of blood cholesterol and triglyceride ($p < 0.0001$; Fig. 2) and, conversely, a significant reduction in the levels of albumin ($p < 0.0001$; Fig. 2). Treatment with ASO was found to reverse these CCl₄-induced elevations in serum cholesterol and triglycerides, as well as the reductions in albumin levels ($p < 0.05$ vs. CCl₄ group; Fig. 2). Importantly, the values obtained for ASO-treated mice did not significantly differ from those recorded for healthy controls or the silymarin-treated mice ($p > 0.05$), thereby indicating that ASO conferred hepatoprotection comparable with that obtained using silymarin and contributed to a complete normalization of these parameters.

3.3 Effects of ASO on Lipid Peroxidation and Hepatic Antioxidant Capacity

Serum MDA levels, a well-established biomarker of lipid peroxidation, were measured to assess the degree of CCl₄-induced oxidative stress in hepatic tissue. Relative to the control mice, the administration of CCl₄ was observed to promote marked increases in serum levels of MDA ($p < 0.0001$; Fig. 3), whereas treatment with ASO was found

to reverse this higher production of MDA to levels that did not differ significantly from those in mice in the control and silymarin-treated groups ($p > 0.05$ for both comparisons; Fig. 3), indicating a successful normalization of lipid peroxidation to baseline levels.

To assess the antioxidant defence capacity of liver, we also determined the levels of TAO activity in mouse sera. CCl₄ treatment was observed to result in a significant depletion in TAO activity, reflecting the heightened level of oxidative stress ($p < 0.001$; Fig. 3). Activity levels were, nevertheless, effectively restored in response to ASO treatment when compared with levels in the CCl₄-treated mice, with activities comparable to those in the control and silymarin-treated groups ($p > 0.05$ for both comparisons; Fig. 3). These findings thus provide evidence to indicate that ASO is effective in reducing the CCl₄-induced oxidative damage to liver function.

3.4 Histopathological Examination of Liver Tissue

3.4.1 H&E Staining of Liver Tissues

To examine the histoarchitecture and structural integrity of liver tissues, we prepared hematoxylin- and eosin-stained sections from liver tissues collected from mice in the different treatment groups. Tissues obtained from the control mice were observed to have a normal morphology and architecture, with well-preserved hepatocytes (Fig. 4A). In contrast, tissues obtained from the CCl₄-treated mice showed evidence of substantial damage, including portal inflammation, venous congestion, and fatty changes, including hepatocyte vacuolization and fatty droplet accumulation (Fig. 4B). Comparatively, tissues derived from mice treated with either ASO or silymarin were characterized by

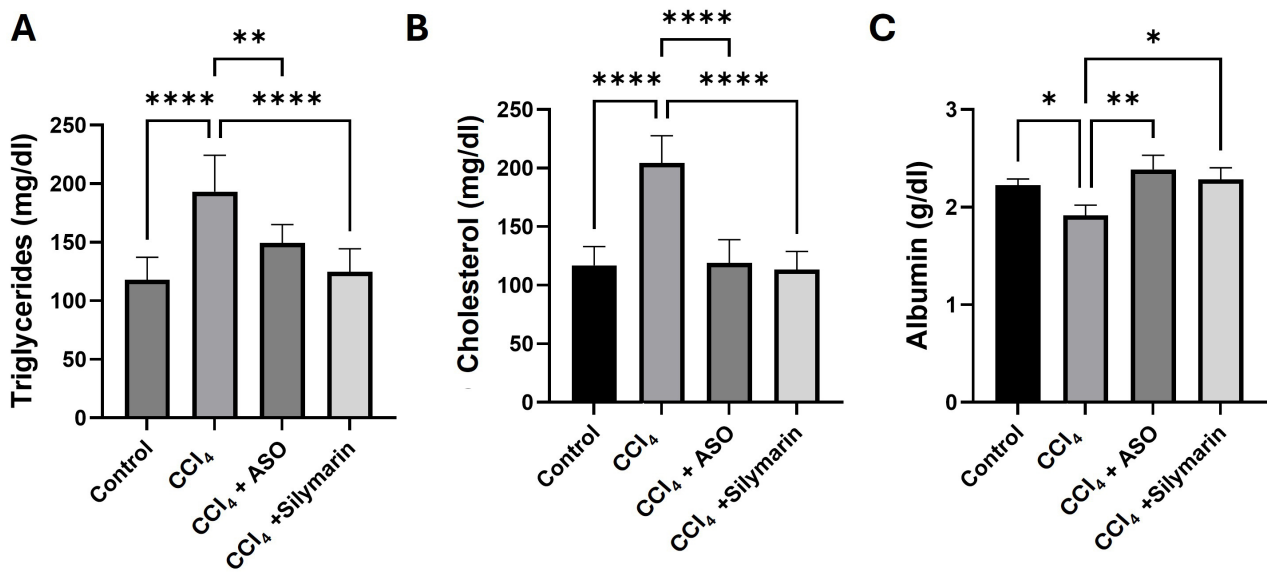


Fig. 2. Effects of ASO on serum cholesterol, triglycerides, and albumin levels. (A–C) Serum biomarkers in different treatment groups. Data are presented as the means \pm SEM ($n = 6$). * $p < 0.05$, ** $p < 0.01$, and **** $p < 0.0001$ between the indicated groups.

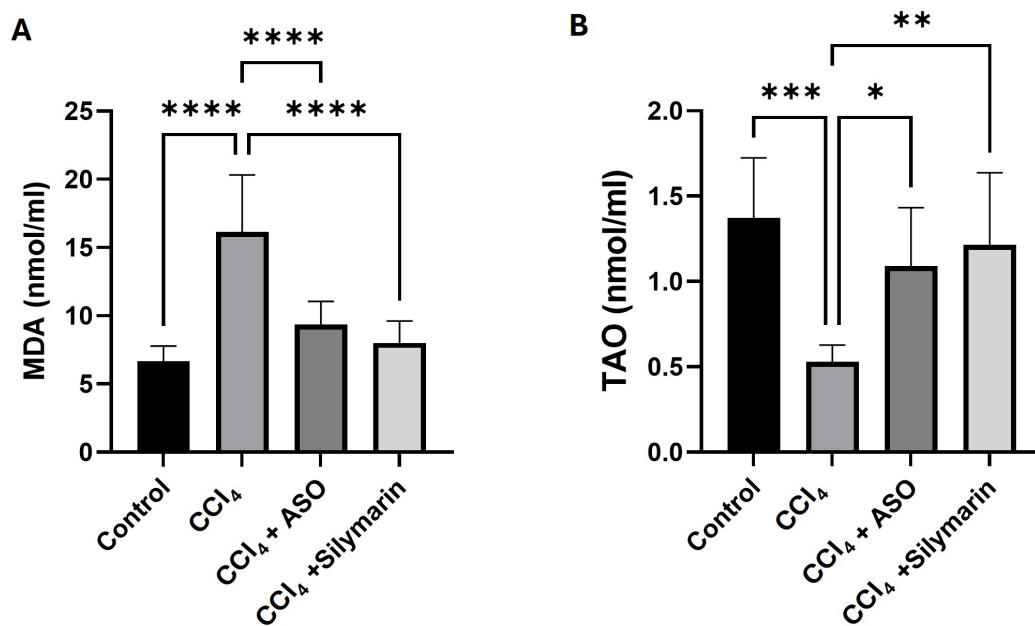


Fig. 3. Effects of ASO on serum malondialdehyde (MDA) levels and total antioxidant (TAO) activity. (A,B) Serum biomarkers for the different treatment groups. Data are presented as the means \pm SEM for each treatment group ($n = 6$). * $p < 0.05$, ** $p < 0.01$, *** $p < 0.001$ and **** $p < 0.0001$ compared with the vehicle control group.

a marked amelioration of the CCl₄-induced liver damage, with hepatic architecture restored to virtually normal levels (Fig. 4C,D).

3.4.2 Masson's Trichrome Staining of Liver Tissue

To assess the effects on the different treatments on collagen fiber deposition and fibrosis, we performed Masson's trichrome staining. Sections of tissues obtained from the control mice were characterized by a limited accumulation

of collagen and an intact liver architecture (Fig. 5A). Comparatively, tissues obtained from CCl₄-treated mice showed evidence of a substantial deposition of collagen, the development of fibrous septa, and an altered liver architecture (Fig. 5B). Notably the administration of both ASO and silymarin contributed to marked reductions in collagen deposition and also restored the aberrant hepatic architecture (Fig. 5C,D).

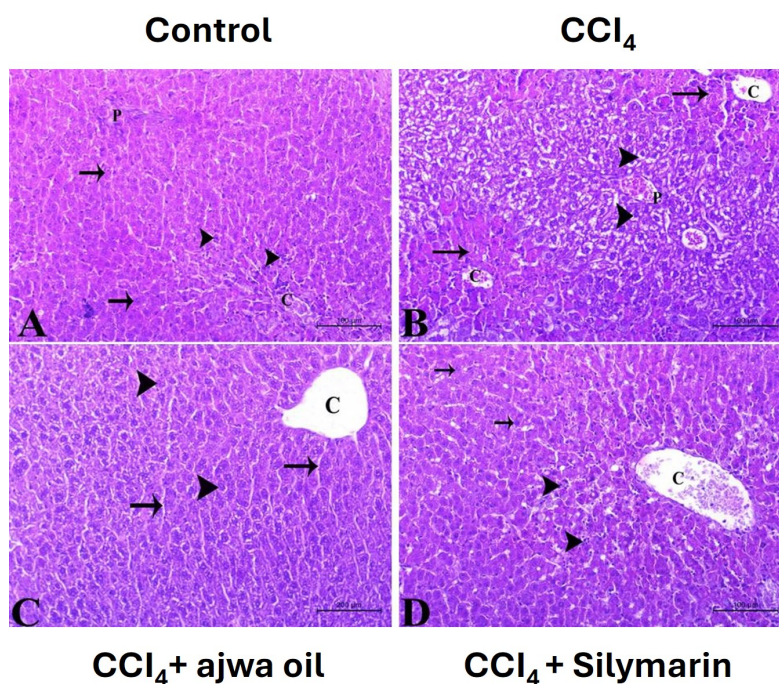


Fig. 4. Photomicrographs of hematoxylin- and eosin-stained sections used to assess the histological architecture of liver tissues in mice in the different treatment groups ($\times 200$ magnification). (A) Control group specimen showing a typical hepatic tissue architecture, with a central vein (c) and normal hepatocytes (arrowheads) arranged in hepatic cords, interspersed with hepatic sinusoids (arrows) containing phagocytic cells, and a normal portal region (p). Scale bar = 100 μm . (B) Tissue obtained from a mouse treated with CCl_4 showing a disorganized structure, with congested blood vessels, vacuolated hepatocytes (arrowheads) with signs of degenerate and dilated congested blood sinusoids. The hepatocytes (arrow) around the central vein (c) appear to have a normal orientation and structure. Scale bar = 100 μm . (C) CCl_4 -treated mice administered ASO showing normal hepatic tissue with a central vein (c), normal hepatocytes (arrowhead) in hepatic cords separated by hepatic sinusoids (arrow). Scale bar = 200 μm . (D) CCl_4 -treated mice administered silymarin showing normal hepatic tissue with normal hepatocytes (arrow), blood sinusoids (arrowhead) with hyperplasia of phagocytic cells, and a congested central vein. Scale bar = 100 μm .

3.4.3 Periodic Acid-Schiff Staining of Liver Tissues

Periodic acid-Schiff (PAS) staining was used to identify glycogen and determine hepatocyte functional integrity. Whereas liver sections prepared for control animals revealed normal hepatocyte glycogen levels (Fig. 6A), those from the CCl_4 -administered mice showed reductions in the intensity of PAS staining, indicative of a depletion in glycogen caused by hepatocellular injury (Fig. 6B). Administration of ASO or silymarin restored glycogen reserves, as indicated by an enhanced intensity of PAS staining (Fig. 6C,D).

Table 1 summarizes the semi-quantitative histopathological scores for all evaluated parameters. ASO treatment significantly reduced all CCl_4 -induced pathological changes ($p < 0.05$), with scores comparable to those of the control and silymarin-treated groups ($p > 0.05$). Notably, the collagen accumulation scored in this acute model reflects an early fibrogenic response rather than established fibrosis, given the single-dose 24-hour experimental timeline.

4. Discussion

The liver, as a key metabolic organ, is continuously exposed to multiple chemicals and is consequently particularly prone to oxidative stress. In this regard, CCl_4 , a well-established hepatotoxic agent, is widely used in experimental models to induce liver damage and fibrosis [18,19]. Although the flesh and seeds of Ajwa dates have been demonstrated to have antioxidant and anti-inflammatory properties [10,16], the hepatoprotective effects of ASO against CCl_4 -induced liver damage has yet to be assessed. In this study, we accordingly sought to determine the protective effects of ASO against CCl_4 -induced hepatotoxicity in mice using biochemical and histological techniques.

CCl_4 -treated mice were observed to have sustained substantial liver damage, characterized by elevated levels of serum parameters such as ALT, AST, LDH, cholesterol, and triglyceride, as well as reductions in albumin levels, which are features indicative of hepatocellular damage and compromised liver functions. CCl_4 also perturbed hepatic oxidative status, depleting total antioxidant capacity and in-

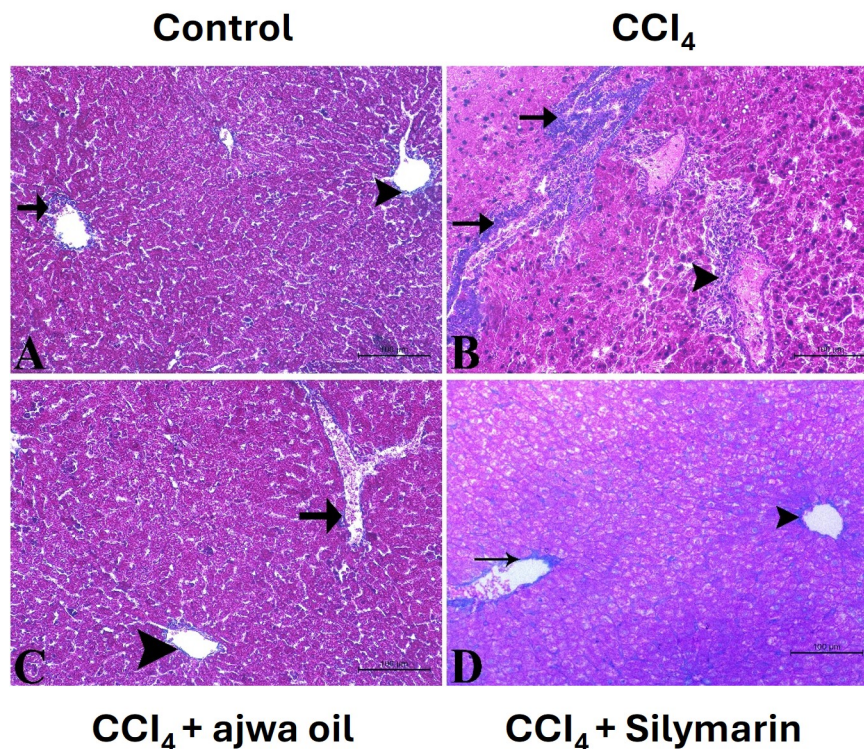


Fig. 5. Photomicrographs of liver tissue sections stained with Masson's trichrome for assessment of collagen deposition in mice in the different treatment groups (magnification $\times 200$). (A) Control mouse: normal hepatic architecture with fine collagen fibers surrounding the central vein (arrowhead) and portal vessels (arrow). Scale bar = 100 μm . (B) CCl_4 -treated mouse: extensive periportal and pericentral fibrosis with massive condensation of fibrous tissue around the portal area (arrow) and central vein (arrowhead). Scale bar = 100 μm . (C) CCl_4 + ASO-treated mouse: marked attenuation of fibrosis with fine collagen fibers around the central vein (arrowhead) and portal vessels (arrow), comparable to the control. Scale bar = 100 μm . (D) CCl_4 + silymarin-treated mouse: similar attenuation of fibrosis with fine collagen deposition around the portal vessels (arrow), indicating a hepatoprotective efficacy comparable to that observed following ASO treatment. Scale bar = 100 μm . Note: The visible differences in staining intensity among panels reflect technical differences in tissue processing and not differential therapeutic efficacy (see quantitative analysis in Table 1).

ducing lipid peroxidation, thereby contributing to heightened levels of oxidative stress. Moreover, histological analyses revealed structural damage to liver tissues, characterized by cellular degeneration, elevated levels of collagen deposition, and a depletion of glycogen, changes that are consistent with liver injury and early fibrosis and are frequently seen in the study of hepatotoxicity [5,18].

The administration of ASO was found to ameliorate CCl_4 -induced liver damage at both the biochemical and histological levels, contributing to a normalization of the serum concentrations of ALT, AST, LDH, lipids, and albumin, whilst restoring hepatic antioxidant capacity. Similarly, histological evaluations of liver tissues obtained from ASO-treated mice revealed reductions in CCl_4 -induced hepatocellular injury and fibrosis [22]. Furthermore, PAS staining revealed that mice receiving ASO were characterized by a well-preserved hepatic architecture with reductions in the depletion of glycogen, thereby providing evidence of the hepatoprotective efficacy of this oil.

To a large extent, the observed hepatoprotective effects of ASO can be attributed to its antioxidant properties. In this regard, previous studies have reported that the antioxidant activities of ASO are associated with its phenolic and flavonoid contents [23]. Antioxidant-rich compounds have previously been shown to protect against the hepatocellular damage induced by oxidative stress [8,9], mitigating oxidative stress in hepatocytes, facilitating cellular recovery, and minimizing the evidence of intoxication. The hepatotoxicity attributable to CCl_4 is primarily mediated via the generation of reactive oxygen species, leading to oxidative stress [6,24], causing lipid peroxidation, membrane damage, DNA damage, and inflammation [5,18]. The amelioration of liver damage markers and reduction in the indicators of fibrosis observed in ASO-treated mice provides evidence that this oil facilitates hepatoprotection via mechanisms associated with the elimination of free radicals [25].

Chronic administration of hepatotoxic agents such as CCl_4 can induce hepatic damage via activation of hepatic

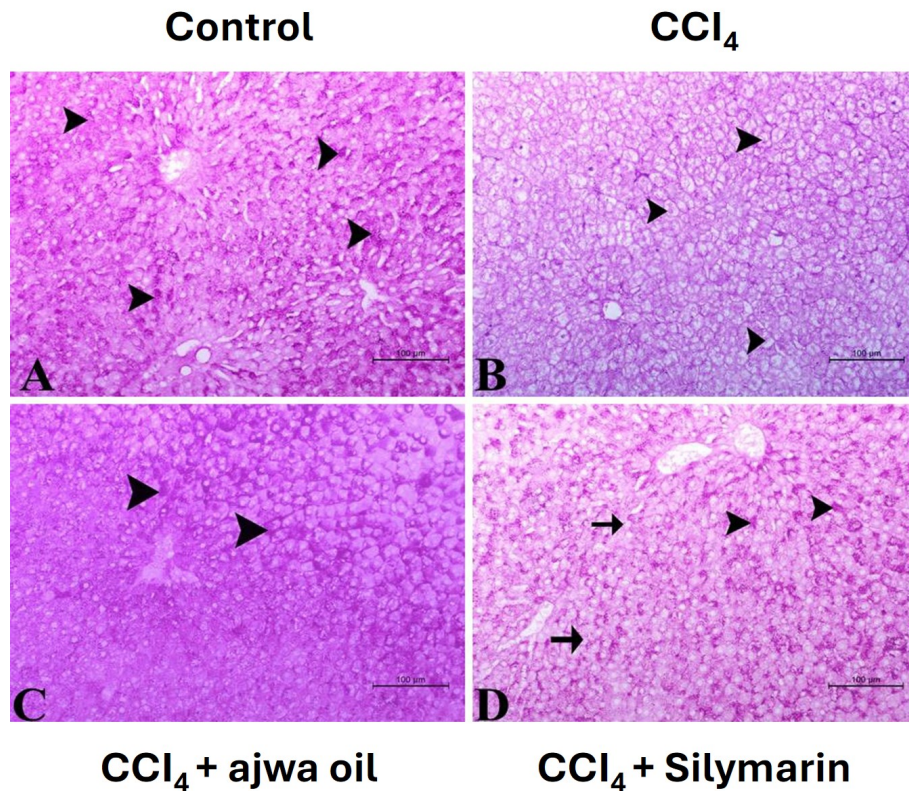


Fig. 6. Photomicrographs of liver sections stained with periodic acid-Schiff (PAS) for assessment of glycogen storage. (A) Section from a control mouse showing pronounced PAS staining of hepatocytes (arrowhead). Scale bar = 100 μm . (B) Section from a CCl_4 -treated mouse showing minimal PAS staining of hepatocytes (arrowhead). Scale bar = 100 μm . (C) Section from a CCl_4 + Ajwa seed oil-treated mouse showing strong PAS staining of hepatocytes (arrowhead). Scale bar = 100 μm . (D) Section from a CCl_4 + silymarin-treated mouse showing moderate to strong PAS staining of hepatocytes (arrowhead), with a few hepatocytes showing weaker staining (arrow). Scale bar = 100 μm .

stellate cells that promote collagen synthesis and deposition, resulting in liver fibrosis [26]. Although established hepatic fibrosis typically develops following repeated or chronic CCl_4 exposure rather than a single acute dose, the elevated collagen deposition observed at 24 hours in our model represents an early fibrogenic response, likely reflecting acute hepatic stellate cell activation and extracellular matrix remodeling rather than true fibrosis. The ability of ASO to attenuate this early collagen deposition suggests a potential anti-fibrogenic effect that warrants validation in chronic CCl_4 models with repeated dosing over several weeks [27].

In addition to the aforementioned conditions, by mediating the release of different pro-inflammatory cytokines at the site of injury, oxidative stress also plays a key role in inducing inflammation, as has previously been reported with respect to CCl_4 -induced liver damage [19]. The protective effects of ASO could thus also be explained in terms of its capacity to replenish endogenous antioxidant capacity and scavenge free radicals, thereby ameliorating the inflammatory response and preventing the progression of fi-

brosis [16]. These findings are consistent with a growing body of recent literature demonstrating that phenolic-rich plant extracts and seed oils ameliorate CCl_4 -induced hepatotoxicity through Nrf2 pathway activation, restoration of glutathione-dependent antioxidant enzymes, and suppression of NF- κ B-driven cytokine release [12,13]. Notably, several recent studies have reported comparable hepatoprotective efficacy between natural phytoingredients and silymarin in acute CCl_4 models, lending support to our present findings [14,15].

On the basis of our findings in this study and those reported in the existing literature, we propose a multi-faceted mechanism for the hepatoprotective effects of ASO against CCl_4 -induced liver injury. Firstly, it is assumed that the phenolic compounds and flavonoids identified in ASO (gallic acid, catechin, epicatechin, and ferulic acid) act as direct free radical scavengers, neutralizing the trichloromethyl radicals generated by the metabolism of CCl_4 . Secondly, ASO appears to enhance the efficacy of endogenous antioxidant defense systems, as evidenced by the restoration of total antioxidant capacity, potentially mediated via an upreg-

ulation of antioxidant enzymes such as superoxide dismutase, catalase, and glutathione peroxidase. Thirdly, the high contents of unsaturated fatty acids (particularly oleic and linoleic acids) in ASO may contribute to stabilizing hepatocyte membranes and reduce the levels of lipid peroxidation, as indicated by a significant reduction in serum MDA levels. Fourthly, it is plausible that the anti-inflammatory properties of ASO are associated with a suppression of the production of pro-inflammatory cytokine and inhibition of inflammatory cell infiltration into hepatic tissues. Finally, the reductions in collagen deposition observed in ASO-treated mice indicate that this oil may prevent hepatic stellate cell activation, thereby inhibiting the early stages of fibrogenesis. Consequently, future studies employing molecular pathway analysis, including assessments of Nrf2 signaling, NF- κ B activation, and specific cytokine profiles, could provide valuable insights for confirming and further elucidating these proposed mechanisms.

Our finding that with respect to all evaluated parameters, the observed efficacy of ASO was comparable to that of the reference hepatoprotective agent silymarin, is particularly relevant. Specifically, ASO-treated animals showed no significant difference from those treated with silymarin regarding the levels of liver enzymes, lipid profiles, oxidative stress markers, and histological features ($p > 0.05$ for all comparisons), whereas both treatments contributed to improvements in these parameters compared with CCl₄-treated mice ($p < 0.05$). These findings thus provide a clear indication of the therapeutic potential of ASO and compelling evidence for its development as a natural hepatoprotective agent, potentially offering a safer and more accessible alternative to synthetic hepatoprotective drugs.

5. Study Limitations

Although in this study we utilized multiple complementary methods to assess liver damage and protection, encompassing biochemical indicators, oxidative stress parameters, and comprehensive histological examinations, there are certain limitations that should be acknowledged.

Notably, we primarily examined the preventive effects of ASO administered prior to exposing mice to CCl₄, rather than assessing its therapeutic potential subsequent to the induction of liver damage. A key limitation of this study is the use of a single-dose acute CCl₄ model with tissue collection at 24 hours. True hepatic fibrosis, characterized by progressive collagen cross-linking and fibrous septum formation, requires repeated or chronic CCl₄ administration typically over 4–8 weeks. Therefore, the collagen deposition observed in this study should be interpreted as an early fibrogenic signal rather than established fibrosis, and the anti-fibrotic claims of ASO must be validated using a chronic liver injury model. Moreover, the molecular mechanisms underlying the hepatoprotective effects of ASO, including specific signaling pathways, gene expression profiles, and detection of the bioactive compounds associated

with these effects, have yet to be thoroughly elucidated. For example, we did not examine the levels of inflammatory cytokine or markers of hepatic stellate cell activation, which would contribute to enhancing our understanding of the anti-inflammatory and anti-fibrotic mechanisms of ASO. Similarly, we have yet to address dose–response relationships or potential adverse effects associated with the prolonged administration of ASO.

In further research, it will be necessary to focus on evaluating the therapeutic efficacy of ASO in established liver injury models, conduct studies on chronic administration, perform detailed mechanistic investigations, and assess the safety profile of this oil for potential clinical translation.

6. Conclusion

In this study, we established that ASO has notable hepatoprotective effects against CCl₄-induced liver damage, as evidenced by a normalization of serum biochemical markers and restoration of hepatic architecture. The observed improvements in oxidative stress markers and histological features highlight the potential utility of ASO as a promising natural therapeutic agent for protecting the liver against oxidative stress-induced damage and subsequent fibrosis. Further studies are required to elucidate the molecular mechanisms underlying ASO-mediated hepatoprotective effects and to evaluate its long-term efficacy using chronic liver injury models.

Availability of Data and Materials

The datasets used and analyzed during the current study are available from the corresponding author on reasonable request.

Author Contributions

THA, AFA, SWA, and FSA performed the experiments, critically revised the manuscript, and approved the final version. MHA, LAA, and AGA contributed to data analysis, revised the manuscript, and approved the final version. HMZ, AAB, and BDA, contributed to results interpretation, critically revised the manuscript, and approved the final version. AAA and HE performed experiments, wrote the original draft, and approved the final manuscript. All authors read and approved the final manuscript. All authors have participated sufficiently in the work and agreed to be accountable for all aspects of the work.

Ethics Approval and Consent to Participate

The research obtained ethical clearance from the Research Ethics Committee of the Faculty of Pharmacy at Taibah University in Madinah, Kingdom of Saudi Arabia (Project Reference Number COPTU-REC-122-20250128). Animal experiments adhere to the 3Rs principle: substitution, reduction, and optimization.

Acknowledgment

Not applicable.

Funding

This research received no external funding.

Conflict of Interest

The authors declare no conflict of interest.

References

- [1] Szabo G, Petrasek J. Inflammasome activation and function in liver disease. *Nature Reviews. Gastroenterology & Hepatology*. 2015; 12: 387–400. <https://doi.org/10.1038/nrgastro.2015.94>.
- [2] Jia C. Advances in the regulation of liver regeneration. *Expert Review of Gastroenterology & Hepatology*. 2011; 5: 105–121. <https://doi.org/10.1586/egh.10.87>.
- [3] Dey A, Cederbaum AI. Alcohol and oxidative liver injury. *Hepatology (Baltimore, Md.)*. 2006; 43: S63–S74. <https://doi.org/10.1002/hep.20957>.
- [4] Biswas SK. Does the Interdependence between Oxidative Stress and Inflammation Explain the Antioxidant Paradox? *Oxidative Medicine and Cellular Longevity*. 2016; 2016: 5698931. <https://doi.org/10.1155/2016/5698931>.
- [5] Jaeschke H, Gores GJ, Cederbaum AI, Hinson JA, Pessayre D, Lemasters JJ. Mechanisms of hepatotoxicity. *Toxicological Sciences: an Official Journal of the Society of Toxicology*. 2002; 65: 166–176. <https://doi.org/10.1093/toxsci/65.2.166>.
- [6] Mohi-Ud-Din R, Mir RH, Sawhney G, Dar MA, Bhat ZA. Possible Pathways of Hepatotoxicity Caused by Chemical Agents. *Current Drug Metabolism*. 2019; 20: 867–879. <https://doi.org/10.2174/1389200220666191105121653>.
- [7] Rates SM. Plants as source of drugs. *Toxicon: Official Journal of the International Society on Toxinology*. 2001; 39: 603–613. [https://doi.org/10.1016/s0041-0101\(00\)00154-9](https://doi.org/10.1016/s0041-0101(00)00154-9).
- [8] Datta S, Aggarwal D, Sehrawat N, Yadav M, Sharma V, Sharma A, *et al.* Hepatoprotective effects of natural drugs: Current trends, scope, relevance and future perspectives. *Phytotherapy: International Journal of Phytotherapy and Phytopharmacology*. 2023; 121: 155100. <https://doi.org/10.1016/j.phymed.2023.155100>.
- [9] Casas-Grajales S, Muriel P. Antioxidants in liver health. *World Journal of Gastrointestinal Pharmacology and Therapeutics*. 2015; 6: 59–72. <https://doi.org/10.4292/wjgpt.v6.i3.59>.
- [10] Mesalam NM, Aldhumri SA, Gabr SA, Ibrahim MA, Al-Mokaddem AK, Abdel-Moneim AME. Putative abrogation impacts of Ajwa seeds on oxidative damage, liver dysfunction and associated complications in rats exposed to carbon tetrachloride. *Molecular Biology Reports*. 2021; 48: 5305–5318. <https://doi.org/10.1007/s11033-021-06544-1>.
- [11] Almohmadi NH, Aldhalmi AK, Zahran M, Alhassani WE, Felemban SG, El-Nabtity SM, *et al.* Hepatoprotective efficacy of *Lagenaria siceraria* seeds oil against experimentally carbon tetrachloride-induced toxicity. *Open Veterinary Journal*. 2024; 14: 2016–2028. <https://doi.org/10.5455/OVJ.2024.v14.i8.31>.
- [12] Abdelaziz DHA, Ali SA. The protective effect of Phoenix dactylifera L. seeds against CCl₄-induced hepatotoxicity in rats. *Journal of Ethnopharmacology*. 2014; 155: 736–743. <https://doi.org/10.1016/j.jep.2014.06.026>.
- [13] Gao W, Guo L, Yang Y, Wang Y, Xia S, Gong H, *et al.* Dissecting the Crosstalk Between Nrf2 and NF-κB Response Pathways in Drug-Induced Toxicity. *Frontiers in Cell and Developmental Biology*. 2022; 9: 809952. <https://doi.org/10.3389/fcell.2021.809952>.
- [14] Zhou J, Zheng Q, Chen Z. The Nrf2 Pathway in Liver Diseases. *Frontiers in Cell and Developmental Biology*. 2022; 10: 826204. <https://doi.org/10.3389/fcell.2022.826204>.
- [15] Buzdar JA, Shah QA, Khan MZ, Zaheer A, Shah T, Ataya FS, *et al.* Hepatoprotective effects of olive leaf extract against carbon tetrachloride-induced oxidative stress: in vivo and in-silico insights into the Nrf2-NFκB pathway. *Journal of Molecular Histology*. 2025; 56: 42. <https://doi.org/10.1007/s10735-024-10325-y>.
- [16] Mallhi TH, Qadir MI, Ali M, Ahmad B, Khan YH, Rehman A. Review: Ajwa date (Phoenix dactylifera)- an emerging plant in pharmacological research. *Pakistan Journal of Pharmaceutical Sciences*. 2014; 27: 607–616.
- [17] Ragab AR, Elkablawy MA, Sheik BY, Baraka HN. Antioxidant and Tissue-Protective Studies on Ajwa Extract: Dates from Al-Madinah Al-Monwarah, Saudia Arabia. *Journal of Environmental and Analytical Toxicolog*. 2012; 3: 1000163. <https://doi.org/10.4172/2161-0525.1000163>.
- [18] Recknagel RO, Glende EA, Jr, Dolak JA, Waller RL. Mechanisms of carbon tetrachloride toxicity. *Pharmacology & Therapeutics*. 1989; 43: 139–154. [https://doi.org/10.1016/0163-7258\(89\)90050-8](https://doi.org/10.1016/0163-7258(89)90050-8).
- [19] Weber LWD, Boll M, Stampfl A. Hepatotoxicity and mechanism of action of haloalkanes: carbon tetrachloride as a toxicological model. *Critical Reviews in Toxicology*. 2003; 33: 105–136. <http://doi.org/10.1080/713611034>.
- [20] Vargas-Mendoza N, Madrigal-Santillán E, Morales-González A, Esquivel-Soto J, Esquivel-Chirino C, Garcia-Luna Y González-Rubio M, *et al.* Hepatoprotective effect of silymarin. *World Journal of Hepatology*. 2014; 6: 144–149. <https://doi.org/10.4254/wjh.v6.i3.144>.
- [21] Eltahir HM. Date Seed Oil Possesses a Protective Effect Against Paracetamol-induced Hepatotoxicity. *Zagazig Journal of Pharmaceutical Sciences*. 2024; 33: 31–40. <https://doi.org/10.21608/zjps.2024.277776.1061>.
- [22] Rasool M, Iqbal J, Malik A, Ramzan HS, Qureshi MS, Asif M, *et al.* Hepatoprotective Effects of Silybum marianum (Silymarin) and Glycyrrhiza glabra (Glycyrrhizin) in Combination: A Possible Synergy. Evidence-based Complementary and Alternative Medicine: ECAM. 2014; 2014: 641597. <https://doi.org/10.1155/2014/641597>.
- [23] Assirey EA. The chemical composition, total phenolic and antioxidant content of four date palm saudi cultivars. *Journal of Taibah University for Science*. 2021; 15: 282–287. <https://doi.org/10.1080/16583655.2021.1978805>.
- [24] Berger ML, Bhatt H, Combes B, Estabrook RW. CCl₄-induced toxicity in isolated hepatocytes: the importance of direct solvent injury. *Hepatology (Baltimore, Md.)*. 1986; 6: 36–45. <https://doi.org/10.1002/hep.1840060108>.
- [25] Cohen-Naftaly M, Friedman SL. Current status of novel antifibrotic therapies in patients with chronic liver disease. *Therapeutic Advances in Gastroenterology*. 2011; 4: 391–417. <https://doi.org/10.1177/1756283X11413002>.
- [26] Meyer DH, Bachem MG, Gressner AM. Modulation of hepatic lipocyte proteoglycan synthesis and proliferation by Kupffer cell-derived transforming growth factors type beta 1 and type alpha. *Biochemical and Biophysical Research Communications*. 1990; 171: 1122–1129. [https://doi.org/10.1016/0006-291x\(90\)90801-s](https://doi.org/10.1016/0006-291x(90)90801-s).
- [27] Gambhir S, Vyas D, Hollis M, Aekka A, Vyas A. Nuclear factor kappa B role in inflammation associated gastrointestinal malignancies. *World Journal of Gastroenterology*. 2015; 21: 3174–3183. <https://doi.org/10.3748/wjg.v21.i11.3174>.