

Correction

**Correction: Youniszad et al. Postoperative Atrial Fibrillation After CABG: Inflammatory Mechanisms, Predictive Factors, and Emerging Interventions. The Heart Surgery Forum. 2026, 29(5), 48976**

Muhammad Ghani Youniszad<sup>1,†</sup>, Pengbo Liu<sup>1,†</sup>, Yongzhi Deng<sup>2,\*</sup>

<sup>1</sup>Department of Cardiovascular Surgery, The Affiliated Hospital of Shanxi Medical University, Shanxi Cardiovascular Hospital (Institute), Shanxi Clinical Medical Research Center for Cardiovascular Disease, 030024 Taiyuan, Shanxi, China

<sup>2</sup>Department of Cardiovascular Surgery, Shanxi Cardiovascular Hospital (Institute), The Affiliated Hospital of Shanxi Medical University, Shanxi Clinical Medical Research Center for Cardiovascular Disease, 030024 Taiyuan, Shanxi, China

\*Correspondence: [olympicschina@163.com](mailto:olympicschina@163.com) (Yongzhi Deng)

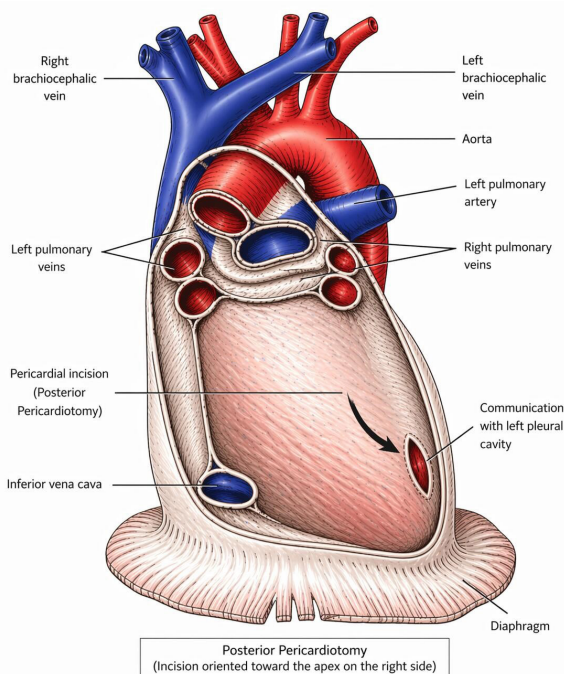
†These authors contributed equally.

Academic Editor: Giuseppe Santarpino

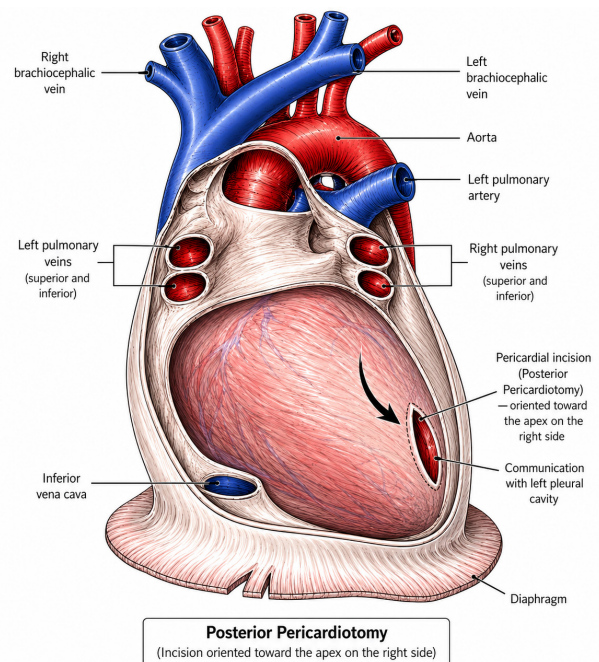
Submitted: 4 June 2026 Accepted: 15 June 2026 Published: 30 June 2026

The authors would like to correct Fig. 3 of Postoperative Atrial Fibrillation After CABG: Inflammatory Mechanisms, Predictive Factors, and Emerging Interventions [1], as errors in the indication and description in Fig. 3. The authors declare that these corrections do not change the result or conclusion of this paper. We sincerely apologize for having this error in the article, and apologize for any inconvenience caused. The authors have provided a corrected version of Fig. 3 here:

**The original Fig. 3:**



**The corrected Fig. 3:**



**Fig. 3. Artist’s representation of the posterior pericardiotomy.** The black arrow illustration of posterior pericardiotomy showing a pericardial incision near the left atrium and pulmonary vein openings, enabling drainage of pericardial fluid and reducing the risk of postoperative atrial fibrillation.

This has been corrected as of June 4, 2026. The authors apologize for these errors.

**Author Contributions**

Not applicable.

**Fig. 3. Artist’s representation of the posterior pericardiotomy (black arrow).** The red arrow illustration of posterior pericardiotomy showing a pericardial incision near the left atrium and pulmonary vein openings, enabling drainage of pericardial fluid and reducing the risk of postoperative atrial fibrillation.

## **Ethics Approval and Consent to Participate**

Not applicable.

## **Acknowledgment**

Not applicable.

## **Funding**

This research received no external funding.

## **Conflicts of Interest**

The authors declare no conflicts of interest.

## **References**

- [1] Youniszad MG, Liu P, Deng Y. Postoperative Atrial Fibrillation After CABG: Inflammatory Mechanisms, Predictive Factors, and Emerging Interventions. *The Heart Surgery Forum*. 2026; 29: 48976. <https://doi.org/10.31083/HSF48976>