International Journal of Pharmacology

Int. J. Pharmacol. **2026**; 22(7): 57416
https://doi.org/10.31083/IJP57416

Research Article

Effects of Ceftazidime–Avibactam Pretreatment on Ovarian Injury and Serum Anti-Müllerian Hormone Levels in a Rat Model of Cecal Ligation and Puncture-Induced Sepsis

Sümeyye Akyüz[1,*], Necip Gökhan Taş[1], Murat Günay[2], Nezahat Kurt[2], Hakan Gökalp Taş[3], Fikret Altındağ[4]

[1]Department of Medical Microbiology, Faculty of Medicine, Erzincan Binali Yildirim University, 24100 Erzincan, Turkiye
[2]Department of Biochemistry, Faculty of Medicine, Erzincan Binali Yildirim University, 24100 Erzincan, Turkiye
[3]Department of Anesthesiology and Reanimation, Faculty of Medicine, Erzincan Binali Yildirim University, 24100 Erzincan, Turkiye
[4]Department of Histology and Embryology, Faculty of Medicine, Van Yuzuncu Yıl University, 65080 Van, Turkiye
*Correspondence: sumeyye_sfl@hotmail.com (Sümeyye Akyüz)
Academic Editor: Dalia O. Saleh
Submitted: 25 August 2026 Revised: 1 October 2026 Accepted: 13 October 2026 Published: 19 November 2026

Abstract

Background: Sepsis-associated inflammation and oxidative stress may contribute to ovarian injury. Therefore, this study aimed to investigate the effects of ceftazidime–avibactam (CZA) pretreatment on ovarian injury, inflammatory and oxidative stress markers, and serum anti-Müllerian hormone (AMH) levels in rats 24 hours after cecal ligation and puncture (CLP), a model of sepsis. **Methods:** A total of 24 adult female Wistar rats were randomly assigned to four groups (n = 6 per group): sham, CZA-only, CLP-induced sepsis, and CZA-pretreated CLP. Rats in the CZA-only and CZA-pretreated CLP groups received intraperitoneal CZA at 250 mg/kg once daily for seven consecutive days before the sham or CLP procedure, respectively. Sepsis was induced using the CLP procedure. Ovarian injury was evaluated using biochemical, histopathological, and immunohistochemical analyses, and serum AMH concentrations were also measured. Continuous biochemical variables were analyzed using one-way analysis of variance (ANOVA) followed by Tukey's honestly significant difference (HSD) test for pairwise comparisons. Additional two-sided exact permutation tests with Holm adjustment were performed as sensitivity analyses for selected ovarian tissue biomarkers. Histopathological and immunohistochemical scores were analyzed at the animal level using two-sided exact permutation tests, with Holm adjustment for pairwise comparisons. **Results:** Compared with the sham group, rats in the CLP group had higher serum and ovarian tissue levels of interleukin-1 beta (IL-1β), interleukin-6 (IL-6), and tumor necrosis factor-alpha (TNF-α), along with increased ovarian tissue malondialdehyde (MDA) levels. Furthermore, ovarian tissue glutathione (GSH) and glutathione reductase (GR) levels were decreased in the CLP group, as were serum AMH concentrations. Compared with the CLP group, the CZA-pretreated CLP group exhibited lower serum IL-1β and IL-6 levels, decreased ovarian tissue IL-1β, IL-6, TNF-α, and MDA levels, and elevated ovarian tissue GSH, GR, and serum AMH levels at 24 hours. Serum TNF-α levels did not differ significantly between these groups. Histopathological assessments revealed lower scores for vascular dilation and hyperemia, edema, apoptosis, and necrosis, as well as reduced caspase-3 and TNF-α staining intensity scores in the CZA-pretreated CLP group (Holm-adjusted $p = 0.013$ for each comparison). **Conclusions:** In this rat model, seven days of pretreatment with CZA before CLP was associated with reduced ovarian injury and immunohistochemical staining scores, more favorable ovarian biochemical findings, and higher serum AMH levels at 24 hours. Further evaluation is required to determine whether these findings can be translated into human clinical practice; direct extrapolation is not currently warranted. In addition, whether these effects are attributable to properties beyond the antibacterial effects of CZA or would occur with treatment initiated after sepsis onset remains unknown.

Keywords: ceftazidime; avibactam; sepsis; ovarian reserve; anti-Müllerian hormone

1. Introduction

Sepsis occurs when the body's response to an infection becomes dysregulated and causes tissue damage and organ dysfunction severe enough to threaten life [1]. During sepsis, the excessive release of proinflammatory cytokines, endothelial dysfunction, microcirculatory impairment, and oxidative stress can damage many organs, including the gonads [2]. Of the available experimental models used to induce sepsis in rats, the cecal ligation and puncture (CLP) model is considered to be one of the most clinically relevant, as it induces polymicrobial peritonitis and reproduces several features of human sepsis. These features include persistently elevated high-mobility group box 1 protein levels, hyperdynamic circulation, systemic inflammation, and multiple organ injury [3].

The pool of quiescent primordial follicles is a key determinant of ovarian reserve, and an important determinant of reproductive lifespan. Premature loss of this follicle pool can diminish future reproductive potential and may lead to premature ovarian insufficiency [4]. Diminished ovarian reserve is characterized by reduced reproductive potential

Copyright: © 2026 The Author(s). Published by IMR Press.
This is an open access article under the CC BY 4.0 license.

Publisher's Note: IMR Press stays neutral with regard to jurisdictional claims in published maps and institutional affiliations.

and an overall decrease in response to ovarian stimulation among women of reproductive age relative to age-matched peers [5]. Experimental studies have indicated that endotoxemia and sepsis may cause ovarian injury associated with inflammatory, oxidative, and apoptotic changes [6,7].

Preantral and small antral follicles secrete anti-Müllerian hormone (AMH) through their granulosa cells. Circulating AMH is used as an ovarian reserve-related biomarker and has been linked to the ovarian response to stimulation in women undergoing *in vitro* fertilization (IVF) [8,9]. Evaluating serum AMH alongside ovarian biochemical and histopathological findings may therefore provide complementary information regarding ovarian injury and ovarian reserve based on changes in levels of specific biomarkers.

Effective sepsis care necessitates the prompt administration of an antimicrobial agent active against the causative pathogen, as treatment delays are associated with poorer outcomes [10]. Ceftazidime–avibactam (CZA), which combines ceftazidime with the non-β-lactam β-lactamase inhibitor avibactam, is included in treatment guidance for selected infections caused by carbapenem-resistant Enterobacterales and difficult-to-treat resistant *Pseudomonas aeruginosa* [11]. Its activity against Gram-negative organisms has supported its use in serious infections, including complicated intra-abdominal and urinary tract infections [12,13].

Whether CZA pretreatment can modulate ovarian injury during sepsis has not been established. In this study, we therefore examined ovarian biochemical changes, histopathology, immunohistochemical staining, and serum AMH levels 24 hours after CLP modeling in rats pretreated with CZA to address this gap in knowledge.

2. Materials and Methods

2.1 Animals and Housing

Twenty-four adult female Wistar albino rats aged 10–12 weeks and weighing 225–250 g were obtained from the Experimental Animals Application and Research Center of Erzincan Binali Yıldırım University, Erzincan, Türkiye. Rats were housed in groups of six under controlled conditions (22 ± 2 °C, relative humidity: 50–60%) with a 12-hour light/12-hour dark cycle and unrestricted access to standard laboratory feed and water. During the seven-day acclimatization period, vaginal smears were collected daily to monitor estrous cyclicity. Only animals exhibiting a regular 4–5-day estrous cycle during this period were included in the study. All animal care and experimental procedures were conducted in accordance with the Guide for the Care and Use of Laboratory Animals and relevant institutional guidelines. The study protocol was approved by the Erzincan Binali Yıldırım University Animal Experiments Local Ethics Committee (approval date: 27 March 2025; decision no.: 14). The study has been reported in accordance with the ARRIVE 2.0 guidelines, and the completed ARRIVE Essential 10 checklist can be found in the **Supplementary Material**.

2.2 Drugs and Chemicals

The drugs used in this study were ketamine hydrochloride (Ketalar®, Pfizer Inc., New York, NY, USA), xylazine hydrochloride (Rompun®, Bayer AG, Leverkusen, Germany), and ceftazidime–avibactam (Zavicefta®, ACS Dobfar S.p.A., Tribiano, Milan, Italy). CZA was reconstituted with sterile water for injection immediately before administration.

2.3 Experimental Groups

A computer-generated random sequence was used to assign the 24 female Wistar albino rats to four groups (n = 6 per group): sham (SG), ceftazidime–avibactam alone (CZA), cecal ligation and puncture (CLP), and CZA pretreatment followed by CLP (CCLP). The experimental protocol, which had received ethical approval, specified the inclusion of six rats per group, with that number having been selected in consideration of the Reduction principle of the 3Rs (replacement, reduction, and refinement). No formal a priori sample-size or power calculation was performed. No single primary outcome was prespecified; serum AMH, ovarian biochemical markers, and histopathological and immunohistochemical findings were evaluated as study outcomes. All treatment and surgical procedures for each group are presented in Table 1.

2.3.1 Sham Group (SG)

For seven consecutive days, each rat received a daily intraperitoneal injection of sterile 0.9% NaCl (0.5 mL). On the final day, anesthesia was induced, the abdominal area was shaved and disinfected with povidone–iodine, and a 2 cm midline incision was made approximately 2 cm above the genital papilla. The cecum was exteriorized and gently manipulated without ligation or puncture, returned to the abdominal cavity, and the incision was closed in two layers.

2.3.2 Ceftazidime–Avibactam-Only Group (CZA)

For seven consecutive days, rats were given freshly prepared CZA by intraperitoneal injection once daily (250 mg/kg in 0.5 mL, consisting of 200 mg/kg ceftazidime and 50 mg/kg avibactam). On the final day, a sham laparotomy was performed as described for the SG, without ligation or puncture of the cecum.

2.3.3 Cecal Ligation and Puncture Group (CLP)

Rats underwent the CLP procedure without CZA pretreatment. Following induction of anesthesia, the abdominal area was shaved and disinfected with povidone–iodine. A 2 cm midline incision was made approximately 2 cm above the genital papilla, and the cecum was exteriorized. The cecum was ligated immediately distal to the ileocecal valve using a 4-0 silk suture. The cecal contents were gen-

Table 1. Experimental groups and procedures performed.

Group	n	Treatment	Surgical procedure
SG (Sham)	6	Intraperitoneal (i.p.) administration of 0.5 mL 0.9% NaCl for 7 days	Laparotomy with cecum isolation; no ligation or puncture performed
CZA	6	Intraperitoneal (i.p.) administration of ceftazidime–avibactam (250 mg/kg) for 7 days	Laparotomy with cecum isolation; no ligation or puncture performed
CLP	6	No drug administered	Cecal ligation and double puncture using an 18-gauge needle, followed by abdominal closure
CCLP	6	Intraperitoneal (i.p.) administration of ceftazidime–avibactam (250 mg/kg) for 7 days	Cecal ligation and double puncture using an 18-gauge needle, followed by abdominal closure

SG, Sham group; CLP, Sepsis group; CZA, Ceftazidime–avibactam alone; CCLP, CZA + Sepsis group; i.p., intraperitoneal.

tly moved toward the distal portion, which was then punctured twice using an 18-gauge needle. After the cecum was repositioned within the abdomen, the incision was sutured in two layers. The rats were then observed for 24 hours following this procedure to allow the septic response to develop.

2.3.4 CZA-Pretreated CLP Group (CCLP)

For seven consecutive days before the CLP procedure, rats were given freshly prepared CZA by intraperitoneal injection once daily (250 mg/kg in 0.5 mL, consisting of 200 mg/kg ceftazidime and 50 mg/kg avibactam). On the final day, the same surgical procedure described for the CLP group was performed, and the animals were monitored for 24 hours.

The CZA dose was extrapolated from the recommended adult dose per administration of 2.5 g, consisting of 2.0 g ceftazidime and 0.5 g avibactam, assuming a body weight of 60 kg [14]. Using body surface area normalization and the human-to-rat conversion factors (Km = 37 for humans and Km = 6 for rats), the calculated rat-equivalent dose was approximately 257 mg/kg [15]. Therefore, a total dose of 250 mg/kg, consisting of 200 mg/kg ceftazidime and 50 mg/kg avibactam at a 4:1 ratio, was administered intraperitoneally. Because no established repeated CZA pretreatment protocol was available for CLP-induced ovarian injury, CZA was administered once daily for seven consecutive days as an exploratory preconditioning regimen.

2.4 Anesthesia

Anesthesia was induced via the intraperitoneal administration of ketamine hydrochloride (Ketalar®, 50 mg/mL; 40 mg/kg) and xylazine hydrochloride (Rompun®, 2%, 20 mg/mL; 10 mg/kg). Before surgery, adequate anesthesia was confirmed when the rats remained immobile in the supine position and did not respond to a skin or toe pinch.

2.5 Sample Collection and Euthanasia

Twenty-four hours after the sham or CLP procedure, animals were anesthetized with ketamine hydrochloride (40 mg/kg, intraperitoneal (i.p.)) and xylazine hydrochloride (10 mg/kg, i.p.). While the rats remained under anesthesia, blood was obtained by cardiac puncture. The animals then underwent cervical dislocation, after which the ovaries were harvested. After collection, the whole left ovary from each rat was immersed in 10% neutral-buffered formalin for histopathology and immunohistochemistry. In addition, the whole right ovary from each rat was stored at −80 °C for subsequent biochemical analysis. Bacterial burden, blood and peritoneal cultures, lactate levels, leukocyte counts, and hemodynamic parameters were not assessed. The experimental endpoint was 24 hours after surgery; survival beyond this time point was not assessed.

2.6 Preparation of Serum and Ovarian Tissue Samples

2.6.1 Serum Sample Preparation

Blood was collected in serum tubes and allowed to rest at room temperature for 30 min to permit clot formation. After centrifugation at 1500 ×g for 10 min, serum was divided into aliquots and stored at −80 °C for subsequent use to measure levels of interleukin-1 beta (IL-1β), interleukin-6 (IL-6), tumor necrosis factor-alpha (TNF-α), and AMH.

2.6.2 Ovarian Tissue Homogenate Preparation

The right ovary from each animal was used for biochemical analyses. Approximately 50 mg of ovarian tissue was weighed and homogenized on ice in 1 mL of ice-cold phosphate-buffered saline (PBS; pH 7.4; Loba Chemie Pvt. Ltd., Mumbai, India) using an OV5 homogenizer (VELP Scientifica, Usmate Velate, Italy). Following centrifugation of the homogenates (5000 ×g, 15 min, 4 °C), the supernatants were retained for the assays of IL-1β, IL-6, TNF-α, malondialdehyde (MDA), glutathione (GSH), and glutathione reductase (GR).

Concentrations calculated from the standard curves were corrected for the homogenate volume and applicable dilution factors, followed by subsequent normalization to the wet weight of the ovarian tissue. Results were expressed as nmol/g tissue for MDA, µg/g tissue for GSH, and ng/g tissue for GR. Absorbance readings were taken using a Multiskan Sky microplate spectrophotometer (Thermo Fisher Scientific).

2.7 Biochemical Analyses

2.7.1 Study Area

Biochemical analyses of IL-1β, IL-6, TNF-α, MDA, GSH, and GR were performed at the Research and Development Laboratory of the Faculty of Medicine, Erzincan Binali Yıldırım University. Serum AMH measurements were performed at the Biochemistry Laboratory of Erzincan Binali Yıldırım University Mengücek Gazi Training and Research Hospital.

2.7.2 Measurement of IL-6, IL-1β, and TNF-α

IL-1β, IL-6 and TNF-α concentrations in serum and ovarian tissue homogenates were measured using the following commercially available rat sandwich enzyme-linked immunosorbent assay (ELISA) kits, according to the manufacturers' instructions: Rat IL-1β ELISA Kit (BT LAB, Cat. No. E0119Ra); Rat IL-6 ELISA Kit (BT LAB, Cat. No. E0135Ra); and Rat TNF-α ELISA Kit (BT LAB, Cat. No. E0764Ra). Absorbance was recorded at 450 nm, and final concentrations were determined by fitting the data to corresponding standard curves. The reported analytical sensitivities were 0.08 ng/mL for IL-1β, 0.052 ng/L for IL-6, and 2.51 ng/L for TNF-α. The manufacturer-reported intra-assay and inter-assay coefficients of variation were <8% and <10%, respectively. All tissue concentrations were corrected for dilution and homogenate volume and normalized to the wet weight of the ovarian tissue.

2.7.3 Measurement of MDA, GSH, and GR

MDA, GSH, and GR levels in ovarian homogenates were determined with the respective rat ELISA kits from BT LAB (MDA, E0156Ra; GSH, EA0113Ra; GR, E1085Ra), following the manufacturer's protocols. Absorbance was recorded at 450 nm with a microplate reader, and final concentrations were determined by fitting the data to corresponding standard curves. The reported analytical sensitivities were 0.01 nmol/mL for MDA, 10.25 mg/L for GSH, and 0.24 ng/mL for GR. The manufacturer-reported intra-assay and inter-assay coefficients of variation were <8% and <10%. After correction for dilution and homogenate volume, the results were normalized to ovarian wet weight and expressed as nmol/g tissue for MDA, µg/g tissue for GSH, and ng/g tissue for GR.

2.7.4 Serum AMH

Serum AMH was quantified with a rat ELISA kit (Hangzhou Eastbiopharm Co., Ltd., Hangzhou, China; Cat. No. CK-E90200) following the manufacturer's protocol. Absorbance was recorded at 450 nm and used to determine AMH concentrations based on the kit's standard curve, with results reported in ng/mL. According to the manufacturer, the assay's analytical sensitivity was 0.05 ng/mL, and its measurement range extended from 0.1 to 40 ng/mL.

2.8 Histopathological Examination

Ovarian samples were preserved in 10% neutral-buffered formalin and processed into paraffin blocks using standard histological procedures. A microtome was used to cut 5 µm sections, which were then stained with hematoxylin and eosin (H&E), followed by analysis with a light microscope (Olympus BX53; Olympus Corporation, Tokyo, Japan).

For each animal, five ovarian sections were selected using a systematic random sampling approach. Two non-overlapping microscopic fields were chosen per section, for 10 total fields per animal. Each microscopic field was evaluated independently to assess vascular dilatation and hyperemia, edema, apoptotic morphology, and necrosis. The severity of each finding was determined and assigned a score of 0 (absent or normal), 1 (mild), 2 (moderate), or 3 (severe). The 10 fields per animal were then averaged together for each of these findings to obtain a single score per animal. All evaluations were performed by an experienced histopathologist who examined coded slides in a random order while blinded to group assignment.

2.9 Immunohistochemical Examination

Tissues were fixed in 10% buffered formaldehyde and embedded in paraffin following standard histological processing. A microtome was used to cut sections with a thickness of 4 µm from paraffin blocks onto poly-L-lysine-coated slides. The sections were then deparaffinized and rehydrated. To inhibit endogenous peroxidase activity, they were incubated in 3% hydrogen peroxide (H_2O_2) for 10 minutes. Antigen retrieval was performed twice by heating the slides in citrate buffer (pH 6.1) in a microwave oven to prevent nuclear antigen masking. To block nonspecific binding, a protein block solution was applied and incubated for 10 minutes.

Primary antibodies used were specific for caspase-3 (Santa Cruz Biotechnology, sc-65497, 1:50) and TNF-α (Santa Cruz Biotechnology, sc-52746, 1:50). These primary antibodies were applied to the tissue sections, which were then kept in a humidified chamber at 4 °C overnight. After washing with PBS, slides were sequentially incubated with a biotinylated goat anti-polyvalent secondary antibody (reactive against mouse and rabbit IgGs; Ready-to-Use, Host: Goat; Thermo Fisher Scientific, USA, Cat. No. TP-060-HL) and a streptavidin–peroxidase conjugate, each for 10 minutes. Immunoreactivity was visualized with 3,3′-diaminobenzidine (DAB), followed by counterstaining of the sections with Mayer's hematoxylin. Slides were examined under a light microscope (Olympus BX53, Japan).

For each marker, five ovarian sections per animal were evaluated. Two non-overlapping microscopic fields were randomly selected from each section, yielding 10 fields per animal for each marker. Staining intensity for caspase-3 and TNF-α was graded as "–" (0, negative), "+" (1, weak), "++" (2, moderate), or "+++" (3, strong). For each marker,

the 10 field scores were averaged to obtain one score per animal. The same histopathologist described in Section 2.8 evaluated the coded slides in random order while blinded to group assignment.

2.10 Statistical Analysis

For each biochemical outcome, results are presented as the group means and standard deviation (SD). Distributional normality was assessed using the Shapiro–Wilk test, while Levene's test was used to examine variance equality. Overall differences among the four experimental groups were assessed using one-way analysis of variance (ANOVA), followed by Tukey's honestly significant difference (HSD) test for pairwise comparisons. As an additional sensitivity analysis, two-sided exact permutation tests were performed for ovarian tissue GSH, IL-1β, and TNF-α due to deviations from normality. Pairwise comparisons were based on differences in group means, with Holm adjustment across six comparisons per biomarker. IBM SPSS Statistics 25.0 for Windows (IBM Corp., Armonk, NY, USA) was used for biochemical statistical analyses. The threshold of significance was defined by a p-value < 0.05.

Histopathological and immunohistochemical findings were scored from 0–3. For each finding or marker, the scores from 10 microscopic fields were averaged to obtain one value per animal, with each animal as the unit of analysis. Animal-level scores are reported as mean ± SD. Overall differences among the four groups were assessed with the Kruskal–Wallis test. Two-sided exact permutation tests comparing animal-level mean scores were used for the six pairwise group comparisons. The resulting p-values were adjusted separately for each finding or marker using the Holm method. These score analyses were performed using Python 3.12.14 (Python Software Foundation, Beaverton, OR, USA) and SciPy 1.17.0 (SciPy community, https://scipy.org/). After adjusting for multiple comparisons, p-values < 0.05 were deemed statistically significant.

3. Results

No animal deaths or exclusions occurred during the experimental period; therefore, all 24 rats were included in the final analyses.

3.1 Biochemical Findings

Serum IL-1β, IL-6, TNF-α, and AMH levels for all four groups are presented in Table 2. These analyses revealed lower AMH levels in the CLP group as compared to the SG group, while higher AMH levels were noted in the CCLP group relative to the CLP group. MDA, GSH, GR, IL-1β, IL-6, and TNF-α levels in ovarian tissue samples are presented in Table 3.

Compared with the SG group, animals subjected to CLP exhibited significantly increased serum IL-1β, IL-6, and TNF-α levels. In ovarian tissue samples, CLP significantly increased IL-1β, IL-6, TNF-α, and MDA levels, whereas it decreased GSH and GR levels. Compared with the CLP group, the CCLP group exhibited lower serum IL-1β and IL-6 levels and more favorable values for all measured ovarian tissue biochemical parameters. Although the CCLP group exhibited lower serum levels of TNF-α relative to the CLP group, this difference was not statistically significant. The changes in ovarian tissue MDA, GSH, and GR levels are illustrated in Fig. 1. In additional sensitivity analyses, two-sided exact permutation tests with Holm adjustment were performed for ovarian tissue GSH, IL-1β, and TNF-α. The CLP versus CCLP comparisons remained statistically significant for all three biomarkers (Holm-adjusted $p = 0.026$ for GSH and $p = 0.013$ for both IL-1β and TNF-α). These findings supported the principal pairwise results obtained using Tukey's HSD test.

3.2 Histopathological Findings

The tissue architecture of ovarian sections from the SG group was largely preserved, with low scores for vascular dilation and hyperemia, edema, apoptosis, and necrosis. In the CLP group, marked vascular dilation and hyperemia were observed, together with interstitial edema and more prominent morphological features of apoptosis and necrosis. Scores for all four findings were higher in the CLP group as compared to the SG group (Holm-adjusted $p = 0.013$ for each comparison). The CCLP group presented with less pronounced vascular and interstitial changes and lower apoptosis and necrosis scores relative to the CLP group (Holm-adjusted $p = 0.013$ for each comparison). Scores in the CZA-only group did not differ significantly from those in the SG group for any of the four findings. Overall differences among the four groups were observed for vascular dilatation and hyperemia (Kruskal–Wallis $H = 19.918$), edema ($H = 19.476$), morphological features consistent with apoptosis ($H = 20.308$), and necrosis ($H = 19.851$; all $p < 0.001$). Group scores and Holm-adjusted pairwise comparisons are presented in Table 4, and representative ovarian tissue images are shown in Fig. 2.

3.3 Immunohistochemical Staining for Caspase-3 and TNF-α

Caspase-3 and TNF-α staining intensity scores were higher in the CLP group relative to the SG group (Holm-adjusted $p = 0.013$ for both). Compared with the CLP group, the CCLP group exhibited lower scores for both caspase-3 and TNF-α (Holm-adjusted $p = 0.013$ for both). The CCLP group also presented with higher scores than the SG group for caspase-3 ($p = 0.019$) and TNF-α ($p = 0.013$). Neither staining score differed significantly between the CZA and SG groups. Overall differences among the four groups were observed for caspase-3 (Kruskal–Wallis $H = 19.039$, $p < 0.001$) and TNF-α staining intensity scores ($H = 20.162$, $p < 0.001$). Group scores and Holm-adjusted pairwise comparisons are presented in Table 5, and representative ovarian tissue images are shown in Fig. 3.

Table 2. Serum cytokine and anti-Müllerian hormone levels across the experimental groups.

Parameter	Experimental groups (n = 6/group)				*p*-values					
	SG (1)	CLP (2)	CCLP (3)	CZA (4)	1 - 2	1 - 3	1 - 4	2 - 3	2 - 4	3 - 4
IL-6 (ng/L)	3.18 ± 0.37	5.20 ± 0.50	4.08 ± 0.61	3.19 ± 0.60	**<0.001**	**0.037**	1.000	**0.008**	**<0.001**	**0.039**
IL-1β (ng/mL)	7.07 ± 1.32	13.26 ± 1.94	9.59 ± 1.86	6.98 ± 1.10	**<0.001**	0.056	1.000	**0.004**	**<0.001**	**0.046**
TNF-α (ng/L)	63.80 ± 5.86	79.56 ± 8.76	71.65 ± 11.02	61.36 ± 8.86	**0.027**	0.433	0.963	0.427	**0.009**	0.214
AMH (ng/mL)	0.35 ± 0.04	0.27 ± 0.03	0.34 ± 0.03	0.34 ± 0.04	**0.006**	0.985	0.999	**0.013**	**0.008**	0.996

Data are presented as mean ± standard deviation (SD; n = 6 animals per group). Pairwise *p*-values represent the six comparisons indicated by the group numbers in the column headings. Overall group differences were assessed using one-way analysis of variance (ANOVA), followed by Tukey's HSD test for pairwise comparisons. Statistically significant *p*-values ($p < 0.05$) are shown in bold. SG, sham group; CLP, cecal ligation and puncture group; CCLP, CZA-pretreated CLP group; CZA, ceftazidime–avibactam-only group; IL, interleukin; TNF, tumor necrosis factor; AMH, anti-Müllerian hormone.

Table 3. Ovarian tissue cytokine, oxidative stress, and antioxidant parameters across the experimental groups.

Parameter	Experimental groups (n = 6/group)				*p*-values					
	SG (1)	CLP (2)	CCLP (3)	CZA (4)	1 - 2	1 - 3	1 - 4	2 - 3	2 - 4	3 - 4
MDA (nmol/g)	37.06 ± 3.71	52.35 ± 3.86	42.83 ± 3.87	39.35 ± 5.20	**<0.001**	0.114	0.782	**0.004**	**<0.001**	0.494
GSH (μg/g)	545.73 ± 89.70	296.40 ± 58.09	424.05 ± 41.66	511.17 ± 69.07	**<0.001**	**0.024**	0.808	**0.017**	**<0.001**	0.143
GR (ng/g)	873.12 ± 52.65	707.88 ± 36.30	854.60 ± 57.24	863.08 ± 50.45	**<0.001**	0.916	0.985	**<0.001**	**<0.001**	0.991
IL-1β (ng/g)	397.40 ± 62.17	503.60 ± 33.31	422.67 ± 12.41	382.27 ± 29.38	**<0.001**	0.675	0.904	**0.008**	**<0.001**	0.299
IL-6 (pg/g)	142.23 ± 17.37	255.52 ± 28.82	154.44 ± 23.97	156.16 ± 22.76	**<0.001**	0.807	0.738	**<0.001**	**<0.001**	0.999
TNF-α (ng/g)	6.27 ± 0.54	8.02 ± 0.70	6.46 ± 0.62	6.32 ± 0.75	**<0.001**	0.960	0.999	**0.003**	**0.001**	0.984

Data are presented as mean ± standard deviation (SD; n = 6 animals per group). Pairwise *p*-values correspond to the group numbers in the column headings. Overall group differences were assessed using one-way ANOVA, followed by Tukey's HSD test for pairwise comparisons. Statistically significant *p*-values ($p < 0.05$) are shown in bold. SG, sham group; CLP, cecal ligation and puncture group; CCLP, CZA-pretreated CLP group; CZA, ceftazidime–avibactam-only group; MDA, malondialdehyde; GSH, glutathione; GR, glutathione reductase; IL, interleukin; TNF, tumor necrosis factor.

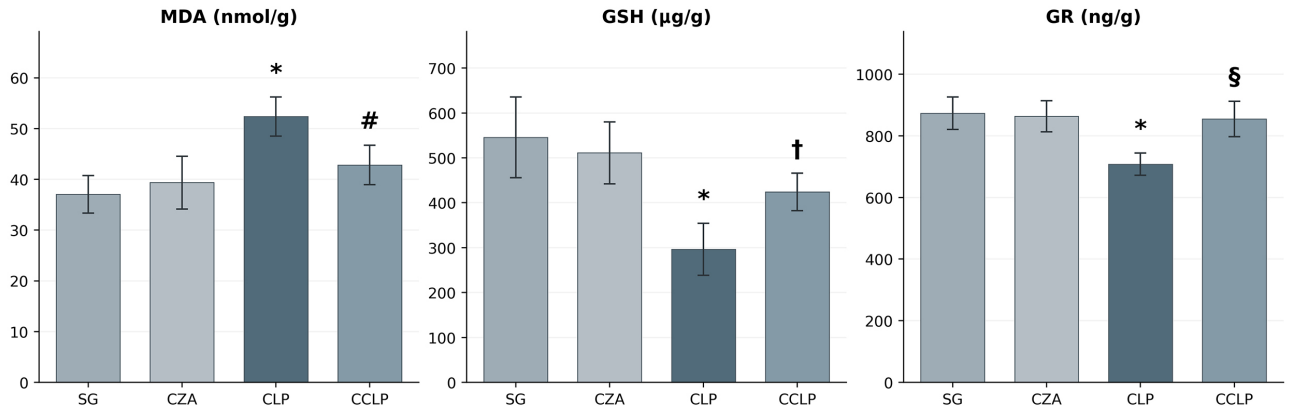

Fig. 1. Intergroup comparison of malondialdehyde (MDA), glutathione (GSH), and glutathione reductase (GR) levels. Values are presented as mean ± standard deviation (SD; n = 6/group). Statistical comparisons were performed using one-way ANOVA followed by Tukey's HSD test. $^{*}p < 0.001$ vs. SG; $^{\#}p = 0.004$ vs. CLP for MDA; $^{\dagger}p = 0.017$ vs. CLP for GSH; $^{\S}p < 0.001$ vs. CLP for GR. SG, sham group; CLP, cecal ligation and puncture group; CCLP, CZA-pretreated CLP group; CZA, ceftazidime–avibactam-only group.

4. Discussion

Sepsis develops when the host response to infection becomes dysregulated and results in life-threatening organ dysfunction [1]. In 2017, an estimated 48.9 million people developed sepsis worldwide, with an estimated 11.0 million sepsis-related deaths, accounting for about 20% of all deaths that year [16]. Tissue injury in sepsis arises through interactions between inflammatory and vascular processes: IL-6, IL-1β, and TNF-α contribute to the inflammatory response, while endothelial barrier damage, disturbed microvascular blood flow, and reactive oxygen species (ROS) generation further impair tissue function [2]. In the present study, ovarian inflammatory and oxidative stress markers

Table 4. Histopathological scores and pairwise comparisons among the experimental groups.

	Experimental groups (n = 6/group)				*p*-values*					
Histopathological finding	SG (1)	CLP (2)	CCLP (3)	CZA (4)	1 - 2	1 - 3	1 - 4	2 - 3	2 - 4	3 - 4
Dilatation and hyperemia	0.30 ± 0.11	2.80 ± 0.18	0.90 ± 0.30	0.43 ± 0.15	**0.013**	**0.013**	0.232	**0.013**	**0.013**	**0.026**
Edema	0.37 ± 0.15	2.90 ± 0.17	0.87 ± 0.10	0.47 ± 0.24	**0.013**	**0.013**	0.576	**0.013**	**0.013**	**0.022**
Apoptosis	0.23 ± 0.15	2.83 ± 0.20	2.03 ± 0.15	0.40 ± 0.13	**0.013**	**0.013**	0.145	**0.013**	**0.013**	**0.013**
Necrosis	0.27 ± 0.16	2.83 ± 0.08	0.93 ± 0.30	0.37 ± 0.15	**0.013**	**0.013**	0.489	**0.013**	**0.013**	**0.013**

Histopathological findings were graded semi-quantitatively as follows: − (0), normal; + (1), mild damage; ++ (2), moderate damage; and +++ (3), severe damage. For each finding, scores from ten microscopic fields were averaged to obtain one score per animal. Values are presented as mean ± standard deviation (n = 6 animals per group). **p*-values were obtained from two-sided exact permutation tests for pairwise comparisons and adjusted using the Holm method across six comparisons for each finding. Bold *p*-values indicate an adjusted $p < 0.05$. SG, sham group; CZA, ceftazidime–avibactam-only group; CLP, sepsis group; CCLP, CZA-pretreated CLP group.

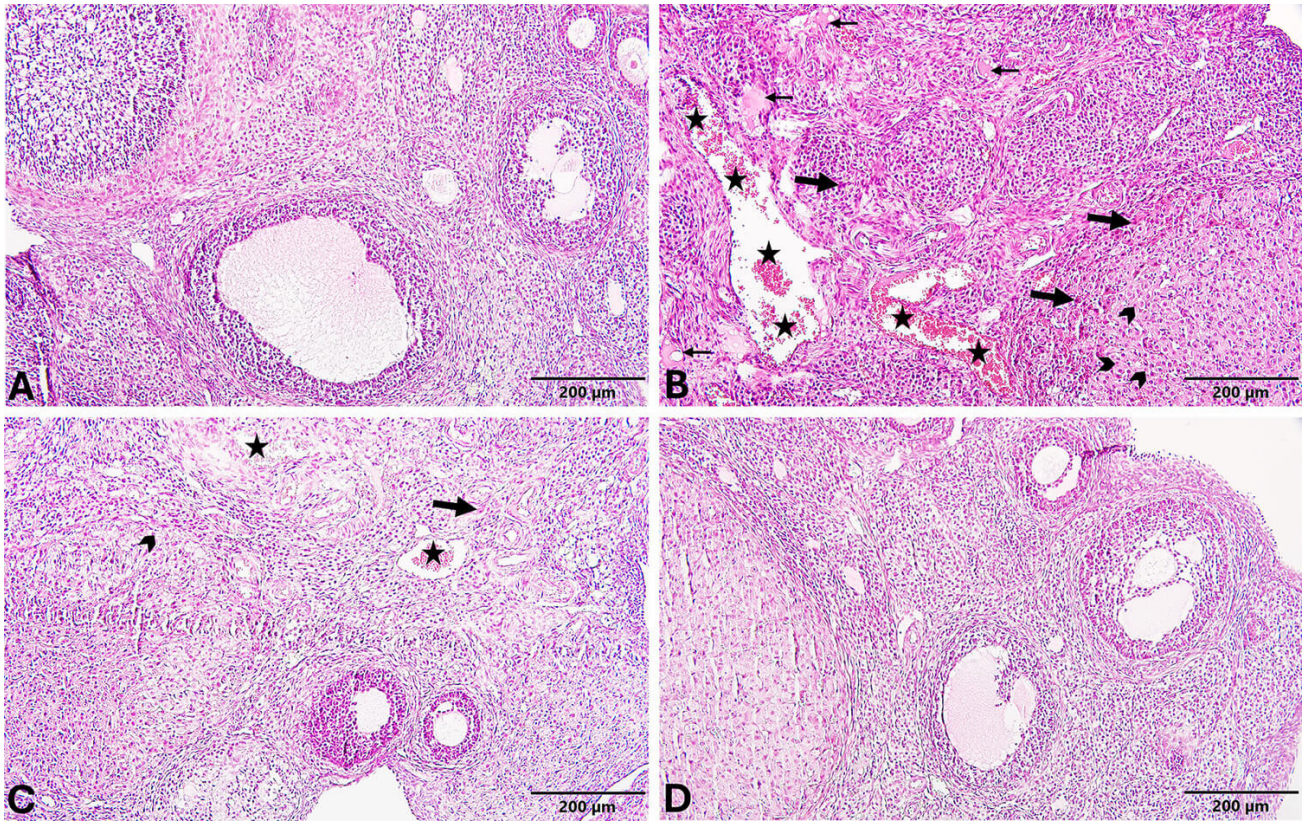

Fig. 2. Ovarian histopathology after ceftazidime–avibactam pretreatment and CLP modeling. Representative ovarian histology after H&E staining: (A) Sham group, (B) CLP group, (C) CLP group pretreated with CZA, and (D) CZA-only group. Ovarian architecture was largely preserved in the sham (A) and CZA-only (D) groups. The CLP group (B) exhibited vascular dilatation and hyperemia (star), interstitial edema (thin arrow), cells with morphological features consistent with apoptosis (arrowhead), and necrotic cells (thick arrow). These changes were less pronounced in the CZA-pretreated CLP group (C). Scale bar = 200 μm in each panel; H&E, ×200. CZA, ceftazidime–avibactam; CLP, cecal ligation and puncture; H&E, hematoxylin and eosin.

were higher at 24 hours post-CLP modeling, whereas antioxidant markers were lower. MDA, a major end product of lipid peroxidation, is widely used as a marker of oxidative tissue damage [17]; the higher ovarian MDA levels observed in the CLP group than in the sham group are therefore consistent with increased lipid peroxidation in ovarian tissue.

Oxidative stress has been implicated in ovarian dysfunction and follicular aging [18,19]. There is a finite pool of primordial follicles, and their loss may reduce ovarian reserve and contribute to premature ovarian insufficiency [4]. AMH is produced by developing ovarian follicles and is commonly used as a biochemical marker associated with ovarian reserve [9,20]. In the present study, serum AMH

Table 5. Immunohistochemical staining intensity scores for caspase-3 and TNF-α and pairwise comparisons among groups.

	Experimental groups (n = 6/group)				*p*-values*					
Marker	SG (1)	CLP (2)	CCLP (3)	CZA (4)	1 - 2	1 - 3	1 - 4	2 - 3	2 - 4	3 - 4
Caspase-3	0.40 ± 0.18	2.87 ± 0.16	1.17 ± 0.37	0.60 ± 0.13	**0.013**	**0.019**	0.113	**0.013**	**0.013**	**0.048**
TNF-α	0.30 ± 0.11	2.93 ± 0.10	1.00 ± 0.18	0.37 ± 0.23	**0.013**	**0.013**	0.760	**0.013**	**0.013**	**0.013**

Immunohistochemical staining intensity was graded semi-quantitatively as follows: − (0), negative; + (1), weak; ++ (2), moderate; and +++ (3), strong. For each marker, scores from 10 microscopic fields were averaged to obtain one score per animal. Values are presented as mean ± standard deviation (n = 6 animals per group). *Pairwise comparisons were performed using two-sided exact permutation tests for the difference in animal-level mean scores, with Holm adjustment across six comparisons per marker. Bold *p* values indicate an adjusted $p < 0.05$. SG, sham group; CLP, cecal ligation and puncture group; CCLP, CZA-pretreated CLP group; CZA, ceftazidime–avibactam-only group.

levels were lower in the CLP group than in the sham group at 24 hours after surgery. This finding coincided with unfavorable ovarian biochemical and tissue findings, although it is important to note that these measurements were made at a single early post-CLP time point. Because follicle counts and long-term reproductive outcomes were not assessed, the lower AMH level cannot definitively establish depletion of the primordial follicle pool or predict a subsequent decline in fertility.

Experimental studies have examined ovarian injury and responses to interventions in several models. Most relevant to our study, Selli et al. [7] investigated nicotinamide riboside in a rat model of experimental sepsis and reported findings concerning ovarian tissue infiltration and antioxidant capacity. Their work supports the relevance of evaluating ovarian injury during sepsis, although their intervention and measured outcomes differ from ours. Ince et al. [21] studied taxifolin in antipsychotic drug-induced ovarian injury, while a study of melatonin examined inflammation, oxidative stress, and apoptosis after cisplatin exposure [22]. Taxifolin was also investigated in the context of ovarian ischemia–reperfusion injury, incorporating analyses of oxidative stress and follicle counts [23]. Studies of lycopene in cisplatin-induced injury [24] and benidipine in ischemia–reperfusion injury [25] have likewise considered ovarian tissue damage and biochemical changes. In a separate cisplatin model, CoQ10 supplementation was associated with higher antral and lower atretic follicle counts than cisplatin alone [26]. Our findings similarly highlight differences in ovarian oxidative stress markers and tissue scores between the treated and untreated injury groups. However, the causes of injury, interventions, and endpoints differ across these studies. In particular, we did not assess follicle counts or long-term reproductive outcomes, and the comparisons cannot establish a direct effect of CZA on ovarian tissue.

Studies using sepsis models offer a closer parallel to our findings. In female rats subjected to CLP, a study of octreotide measured ovarian MDA and GSH levels 24 hours after surgery, providing biochemical outcomes comparable to those observed in the present analysis [27]. Another study utilizing the CLP model examined granulosa and theca cells but detected no statistically significant difference in follicular terminal deoxynucleotidyl transferase–mediated dUTP nick-end labeling (TUNEL) or 5-bromo-2′-deoxyuridine (BrdU) labeling between septic and sham animals [28]. This differs from our histological scores for morphological features consistent with apoptosis and caspase-3 staining. However, as these studies used different measures, their results cannot be directly compared with one another. A more recent study of sepsis in rats evaluating arbutin reported changes in serum AMH and ovarian inflammatory and oxidative stress markers, and included both pretreatment and post-sepsis intervention groups [29]. However, the intervention and use of antibiotics in the septic groups in that study differ from the CZA protocol used herein.

Timely antimicrobial administration is an important component of sepsis management. The 2026 Surviving Sepsis Campaign guidelines recommend immediate antimicrobial therapy, ideally within 1 hour of recognition, for adults with possible, probable, or definite septic shock and for adults with probable or definite sepsis without shock [30]. In an experimental sepsis model, doxycycline reduced endothelial glycocalyx shedding [31]. As this study examined a different antibiotic and outcome than ours, however, it cannot establish a similar effect of CZA on ovarian tissue.

CZA combines the cephalosporin ceftazidime with the β-lactamase inhibitor avibactam. Its activity against *P. aeruginosa*, including multidrug-resistant and extensively drug-resistant isolates, has been reviewed [32]. In a rat intra-abdominal abscess model involving resistant *Klebsiella pneumoniae*, CZA reduced bacterial burden [33]. The development of new β-lactam/β-lactamase inhibitor combinations has expanded the range of treatment options available for infections caused by multidrug-resistant Gram-negative bacteria. The choice of treatment depends on the resistance mechanisms and susceptibility of the bacteria to the specific combination [34]. The 2024 IDSA guidance lists ceftazidime–avibactam among the preferred treatment options for infections caused by KPC-producing Enterobacterales [35]. These publications provide an antibacterial ra-

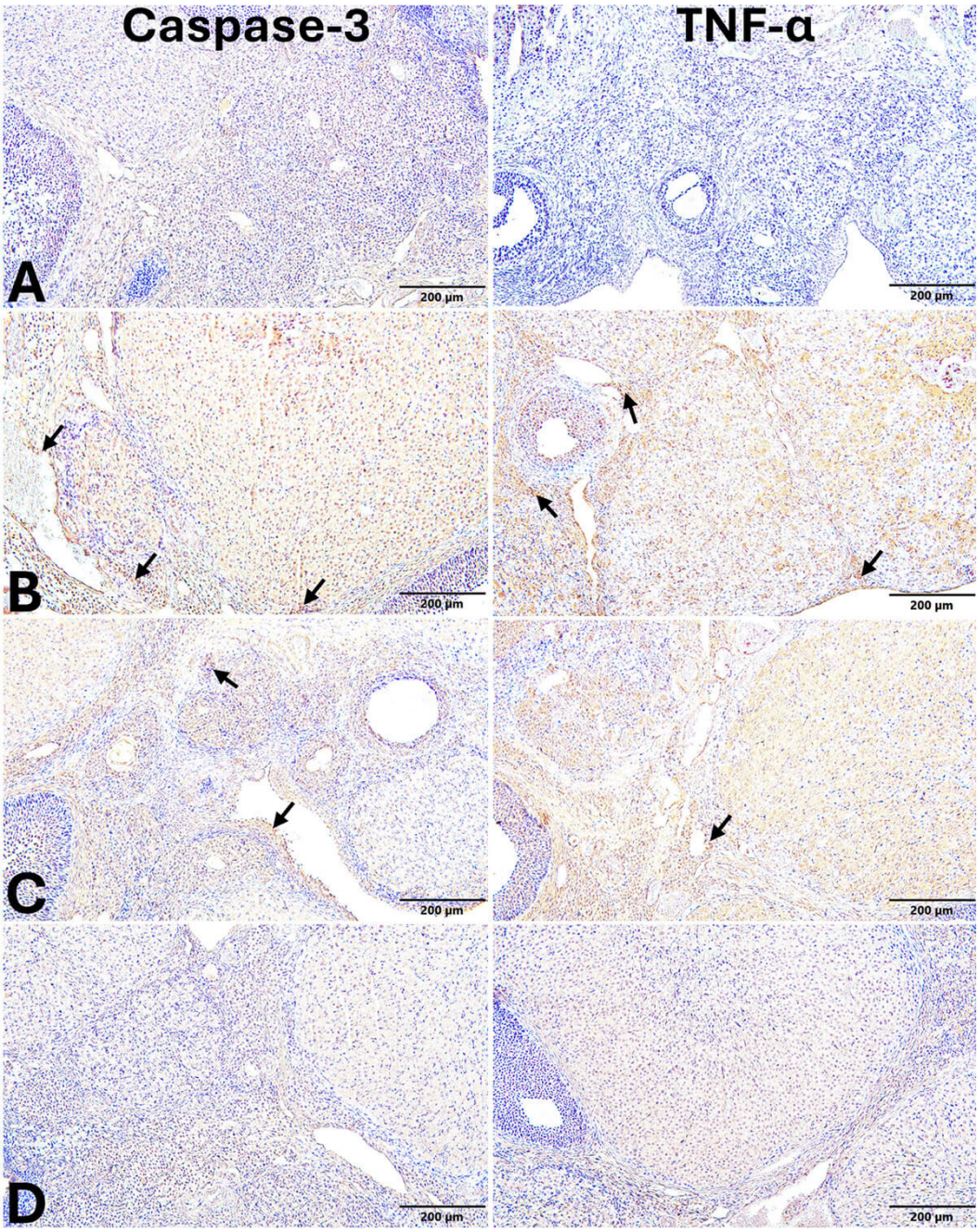

Fig. 3. Caspase-3 and TNF-α immunohistochemical staining in ovarian tissue. Representative ovarian sections stained for caspase-3 (left column) and TNF-α (right column) from the (A) sham, (B) CLP, (C) CZA-pretreated CLP, and (D) CZA-only groups. Brown DAB staining indicates positive immunoreactivity. Staining was more intense in the CLP group (B) as compared to the sham group (A) and was less intense in the CZA-pretreated CLP group (C) than in the CLP group (B). The CZA-only group (D) showed low staining intensity. Arrows indicate examples of positive staining. Scale bar = 200 μm in each panel; ×200. CZA, ceftazidime–avibactam; CLP, cecal ligation and puncture; DAB, 3,3′-diaminobenzidine; TNF-α, tumor necrosis factor-alpha.

tionale for studying CZA but do not demonstrate a direct anti-inflammatory effect or impact on the ovarian tissue.

In the present study, seven days of CZA pretreatment before CLP was associated with more favorable ovarian biochemical findings, lower histopathological injury scores and immunohistochemical staining intensity scores, and higher serum AMH levels at 24 hours post-CLP relative to the untreated CLP model group. Because bacterial burden and systemic indicators of sepsis severity were not assessed, we cannot determine whether these differences reflected changes in infection control or overall sepsis severity. We also cannot distinguish effects associated with the antibacterial activity of CZA from possible additional effects on ovarian tissue.

5. Limitations

This study has several limitations. First, this was an experimental study using rats; therefore, the findings cannot be directly extrapolated to humans. Second, group size was set at six animals without an a priori power calculation. Consequently, smaller between-group effects may have gone undetected. Accordingly, statistically nonsignificant findings should not be interpreted as evidence that no difference exists. Although histopathological and immunohistochemical scores were compared statistically, the small sample size and semi-quantitative nature of the scoring limit the precision and interpretation of these findings. No single primary outcome was prespecified, and multiple outcomes were examined; therefore, the findings should be interpreted with appropriate caution.

Third, bacterial burden, blood and peritoneal cultures, antimicrobial susceptibility, lactate levels, leukocyte counts, and hemodynamic parameters were not evaluated. Survival was not assessed beyond the 24-hour sampling time point. Consequently, we could not determine whether infection control or overall sepsis severity differed between groups; the ovarian findings should not be attributed to an established reduction in sepsis severity. We also cannot distinguish changes associated with CZA's antibacterial activity from additional anti-inflammatory or antioxidant effects. Intracellular signaling pathways were not investigated, further limiting mechanistic interpretation.

Fourth, CZA was administered for seven days before sepsis induction. Because this protocol does not reflect treatment started after sepsis develops, the findings cannot establish the effects of therapeutic CZA administration. Finally, serum AMH levels were assessed 24 hours after surgery, whereas follicle counts and long-term reproductive outcomes, including oocyte quality, pregnancy rates, and fertility, were not evaluated. Therefore, the observed AMH difference cannot establish preservation of the follicular pool or future fertility. These findings require confirmation in larger studies incorporating microbiological assessments, post-sepsis treatment protocols, and long-term reproductive follow-up.

6. Conclusions

In this rat model system, seven days of CZA pretreatment before CLP modeling was associated with lower histopathological injury scores and immunohistochemical staining intensity scores, more favorable ovarian biochemical findings, and higher serum AMH levels at 24 hours relative to the untreated CLP group. Because this was a pretreatment study focused on assessment solely at the 24-hour time point, however, the findings cannot be directly translated into human clinical practice. Whether the observed differences reflect effects beyond the antibacterial activity of CZA, persist over time, or would occur if CZA were administered after sepsis onset remains unknown. Future studies should therefore include microbiological assessments, treatment initiated after sepsis onset, follicle counts, and long-term reproductive outcomes.

Abbreviations

CZA, ceftazidime–avibactam; CLP, cecal ligation and puncture; AMH, anti-Müllerian hormone; CCLP, CZA-pretreated CLP group; ELISA, enzyme-linked immunosorbent assay; i.p., intraperitoneal; DAB, 3,3′-diaminobenzidine; GR, glutathione reductase; ANOVA, analysis of variance; GSH, glutathione; H&E, hematoxylin and eosin; HSD, honestly significant difference; IL-1β, interleukin-1 beta; IL-6, interleukin-6; MDA, malondialdehyde; PBS, phosphate-buffered saline; SD, standard deviation; SG, sham group; TNF-α, tumor necrosis factor-alpha.

Availability of Data and Materials

The datasets used and analyzed during the current study are available from the corresponding author on reasonable request.

Author Contributions

SA and NGT conceived and designed the study. SA and HGT conducted the animal experiments and collected the biological samples. MG and NK performed the biochemical analyses, while FA performed the histopathological and immunohistochemical evaluations. SA, NGT, and HGT analyzed and interpreted the data. SA prepared the initial draft of the manuscript. NGT, HGT, MG, NK, and FA critically reviewed and revised the manuscript for important intellectual content. All authors contributed to editorial changes in the manuscript, read and approved the final version, and agreed to be accountable for all aspects of the work.

Ethics Approval and Consent to Participate

All animal procedures were reviewed and approved by the Erzincan Binali Yıldırım University Animal Experiments Local Ethics Committee (approval date: 27 March 2025; decision no.: 14). All experimental procedures were conducted in accordance with the institutional guidelines and the Turkish Regulation on the Welfare and Protection of Animals Used for Experimental and Other Scientific Purposes. The study has been reported in accordance with the ARRIVE 2.0 guidelines, and the completed ARRIVE Essential 10 checklist can be found in the **Supplementary Material**.

Acknowledgment

Not applicable.

Funding

This research received no external funding.

Conflicts of Interest

The authors declare no conflicts of interest.

Declaration of AI and AI-Assisted Technologies in the Writing Process

During the preparation of this manuscript, the authors used ChatGPT (OpenAI) for language editing and formatting assistance. The authors subsequently reviewed and edited the manuscript, verified its scientific content and references, and take full responsibility for the final content of the publication.

Supplementary Material

Supplementary material associated with this article can be found, in the online version, at https://doi.org/10.31083/IJP57416.

References

[1] Singer M, Deutschman CS, Seymour CW, Shankar-Hari M, Annane D, Bauer M, et al. The Third International Consensus Definitions for Sepsis and Septic Shock (Sepsis-3). JAMA. 2016; 315: 801–810. https://doi.org/10.1001/jama.2016.0287

[2] Hotchkiss RS, Moldawer LL, Opal SM, Reinhart K, Turnbull IR, Vincent JL. Sepsis and septic shock. Nature Reviews. Disease Primers. 2016; 2: 16045. https://doi.org/10.1038/nrdp.2016.45

[3] Das P, Panda SK, Agarwal B, Behera S, Ali SM, Pulse ME, et al. Novel Chitohexaose Analog Protects Young and Aged mice from CLP Induced Polymicrobial Sepsis. Scientific Reports. 2019; 9: 2904. https://doi.org/10.1038/s41598-019-38731-3

[4] Oktem O, Urman B. Understanding follicle growth in vivo. Human Reproduction (Oxford, England). 2010; 25: 2944–2954. https://doi.org/10.1093/humrep/deq275

[5] Broekmans FJ, Soules MR, Fauser BC. Ovarian aging: mechanisms and clinical consequences. Endocrine Reviews. 2009; 30: 465–493. https://doi.org/10.1210/er.2009-0006

[6] Ozmen O, Asci H, Topsakal S, Taner R, Oktem M, Ozcan KN, et al. Remifentanil Attenuates LPS-Induced Genital Tract Injury by Modulating Inflammation, Oxidative Stress, and Mitochondrial Gene Expression in a Rat Sepsis Model. Reproductive Sciences (Thousand Oaks, Calif.). 2025; 32: 2583–2594. https://doi.org/10.1007/s43032-025-01930-7

[7] Selli J, Vural Keles D, Keles ON, Celik M, Yetim Z. Nicotinamide Riboside Preserves Ovarian Injury in Experimental Sepsis Model in Rats. The Eurasian Journal of Medicine. 2023; 55: 128–134. https://doi.org/10.5152/eurasianjmed.2023.22255

[8] Demir M. Anti-Müllerian hormone (AMH): as the best marker of ovarian reserve. Journal of Turkish Clinical Biochemistry. 2013; 11: 79–85.

[9] Yeniçeri H, Ürünsak İF, Sucu M, Çetin C, Özsürmeli M, Khatib G. Anti-Müllerian hormonunun in vitro fertilizasyon hastalarında over rezervini belirlemedeki rolü. Cukurova Medical Journal. 2017; 42: 19–26. https://doi.org/10.17826/cutf.270412 (In Turkish)

[10] Rhodes A, Evans LE, Alhazzani W, Levy MM, Antonelli M, Ferrer R, et al. Surviving Sepsis Campaign: International Guidelines for Management of Sepsis and Septic Shock: 2016. Intensive Care Medicine. 2017; 43: 304–377. https://doi.org/10.1007/s00134-017-4683-6

[11] Tamma PD, Aitken SL, Bonomo RA, Mathers AJ, van Duin D, Clancy CJ. Infectious Diseases Society of America Guidance on the Treatment of Extended-Spectrum β-lactamase Producing Enterobacterales (ESBL-E), Carbapenem-Resistant Enterobacterales (CRE), and Pseudomonas aeruginosa with Difficult-to-Treat Resistance (DTR-P. aeruginosa). Clinical Infectious Diseases: an Official Publication of the Infectious Diseases Society of America. 2021; 72: e169–e183. https://doi.org/10.1093/cid/ciaa1478

[12] Zhanel GG, Lawson CD, Adam H, Schweizer F, Zelenitsky S, Lagacé-Wiens PRS, et al. Ceftazidime-avibactam: a novel cephalosporin/β-lactamase inhibitor combination. Drugs. 2013; 73: 159–177. https://doi.org/10.1007/s40265-013-0013-7

[13] Carmeli Y, Armstrong J, Laud PJ, Newell P, Stone G, Wardman A, et al. Ceftazidime-avibactam or best available therapy in patients with ceftazidime-resistant Enterobacteriaceae and Pseudomonas aeruginosa complicated urinary tract infections or complicated intra-abdominal infections (REPRISE): a randomised, pathogen-directed, phase 3 study. The Lancet. Infectious Diseases. 2016; 16: 661–673. https://doi.org/10.1016/S1473-3099(16)30004-4

[14] Mosley JF, 2nd, Smith LL, Parke CK, Brown JA, Wilson AL, Gibbs LV. Ceftazidime-Avibactam (Avycaz): For the Treatment of Complicated Intra-Abdominal and Urinary Tract Infections. P & T: a Peer-reviewed Journal for Formulary Management. 2016; 41: 479–483.

[15] Nair AB, Jacob S. A simple practice guide for dose conversion between animals and human. Journal of Basic and Clinical Pharmacy. 2016; 7: 27–31. https://doi.org/10.4103/0976-0105.177703

[16] Rudd KE, Johnson SC, Agesa KM, Shackelford KA, Tsoi D, Kievlan DR, et al. Global, regional, and national sepsis incidence and mortality, 1990-2017: analysis for the Global Burden of Disease Study. Lancet (London, England). 2020; 395: 200–211. https://doi.org/10.1016/S0140-6736(19)32989-7

[17] Balcı S, Çöllüoğlu Ç, Yavuzer B, Bulut S, Altındağ F, Akbaş N, et al. Effect of low and high dose of favipiravir on ovarian and reproductive function in female rats: Biochemical and histopathological evaluation. General Physiology and Biophysics. 2022; 41: 457–463. https://doi.org/10.4149/gpb_2022036

[18] Yan F, Zhao Q, Li Y, Zheng Z, Kong X, Shu C, et al. The role of oxidative stress in ovarian aging: a review. Journal of Ovarian Research. 2022; 15: 100. https://doi.org/10.1186/s13048-022-01032-x

[19] Yang L, Chen Y, Liu Y, Xing Y, Miao C, Zhao Y, et al. The Role of Oxidative Stress and Natural Antioxidants in Ovarian Aging. Frontiers in Pharmacology. 2021; 11: 617843. https://doi.org/10.3389/fphar.2020.617843

[20] Iwase A, Hasegawa Y, Tsukui Y, Kobayashi M, Hiraishi H, Nakazato T, et al. Anti-Müllerian hormone beyond an ovarian reserve marker: the relationship with the physiology and pathology in the life-long follicle development. Frontiers in Endocrinology. 2023; 14: 1273966. https://doi.org/10.3389/fendo.2023.1273966

[21] Ince S, Ozer M, Kadioglu BG, Kuzucu M, Ozkaraca M, Gezer A, et al. The effect of taxifolin on oxidative ovarian damage and reproductive dysfunctions induced by antipsychotic drugs in female rats. The Journal of Obstetrics and Gynaecology Research. 2021; 47: 2140–2148. https://doi.org/10.1111/jog.14769

[22] Al-Shahat A, Hulail MAE, Soliman NMM, Khamis T, Fericean LM, Arisha AH, et al. Melatonin Mitigates Cisplatin-Induced Ovarian Dysfunction via Altering Steroidogenesis, Inflammation, Apoptosis, Oxidative Stress, and PTEN/PI3K/Akt/mTOR/AMPK Signaling Pathway in Female Rats. Pharmaceutics. 2022; 14: 2769. https://doi.org/10.3390/pharmaceutics14122769

[23] Kiremitli S, Kiremitli T, Nayki U, Yilmaz N, Turkler C, Dinc K, et al. Taxifolin attenuates ischemia–reperfusion-induced oxidative ovarian damage in rats. Asian Pacific Journal of Reproduc-

tion. 2021; 10: 168–175. https://doi.org/10.4103/2305-0500.321124

[24] Kulhan NG, Kulhan M, Turkler C, Ata N, Kiremitli T, Kiremitli S, et al. Effect of lycopene on oxidative ovary-damage induced by cisplatin in rats. General Physiology and Biophysics. 2019; 38: 253–258. https://doi.org/10.4149/gpb_2019006

[25] Unlubilgin E, Suleyman B, Balci G, Atakan Al R, Cankaya M, Arslan Nayki U, et al. Prevention of infertility induced by ovarian ischemia reperfusion injury by benidipine in rats: Biochemical, gene expression, histopathological and immunohistochemical evaluation. Journal of Gynecology Obstetrics and Human Reproduction. 2017; 46: 267–273. https://doi.org/10.1016/j.jogoh.2016.12.001

[26] Özcan P, Fıçıcıoğlu C, Kizilkale O, Yesiladali M, Tok OE, Ozkan F, et al. Can Coenzyme Q10 supplementation protect the ovarian reserve against oxidative damage? Journal of Assisted Reproduction and Genetics. 2016; 33: 1223–1230. https://doi.org/10.1007/s10815-016-0751-z

[27] Sener G, Cetinel S, Erkanli G, Gedik N, Yeğen BC. Octreotide ameliorates sepsis-induced pelvic inflammation in female rats by a neutrophil-dependent mechanism. Peptides. 2005; 26: 493–499. https://doi.org/10.1016/j.peptides.2004.10.013

[28] Taşdemir M, Ekiz-Yılmaz T, Uğur-Yılmaz C, Orhan N, Doğan MA, Arıcan N, et al. The effects of CLP-induced sepsis on proliferation and apoptosis of granulosa and theca cells in rat ovary: A histochemical and ultrastructural study. Reproductive Biology. 2020; 20: 408–416. https://doi.org/10.1016/j.repbio.2020.04.003

[29] Uyanık G, Gökçek İ, Abay M, Bayraktar HS. Evaluation of the protective effects of arbutin via hormonal, anti-inflammatory, and antioxidant pathways in experimental sepsis induced ovarian damage. Harran University Journal of the Faculty of Veterinary Medicine. 2026; 15: 90–100. https://doi.org/10.31196/huvfd.1902306

[30] Prescott HC, Antonelli M, Alhazzani W, Møller MH, Alshamsi F, Azevedo LCP, et al. Surviving Sepsis Campaign: International Guidelines for Management of Sepsis and Septic Shock 2026. Critical Care Medicine. 2026; 54: 725–812. https://doi.org/10.1097/CCM.0000000000007075

[31] de Oliveira JGCG, Miranda CH. Doxycycline protects against sepsis-induced endothelial glycocalyx shedding. Scientific Reports. 2024; 14: 10477. https://doi.org/10.1038/s41598-024-60919-5

[32] Daikos GL, da Cunha CA, Rossolini GM, Stone GG, Baillon-Plot N, Tawadrous M, et al. Review of Ceftazidime-Avibactam for the Treatment of Infections Caused by *Pseudomonas aeruginosa*. Antibiotics (Basel, Switzerland). 2021; 10: 1126. https://doi.org/10.3390/antibiotics10091126

[33] Sleger T, Gangl E, Pop-Damkov P, Krause KM, Laud PJ, Slee AM, et al. Efficacy of ceftazidime-avibactam in a rat intra-abdominal abscess model against a ceftazidime- and meropenem-resistant isolate of Klebsiella pneumoniae carrying bla_{KPC-2}. Journal of Chemotherapy (Florence, Italy). 2018; 30: 95–100. https://doi.org/10.1080/1120009X.2017.1405609

[34] Yahav D, Giske CG, Gramatniece A, Abodakpi H, Tam VH, Leibovici L. New β-Lactam-β-Lactamase Inhibitor Combinations. Clinical Microbiology Reviews. 2021; 34: e00115–e00120. https://doi.org/10.1128/CMR.00115-20 (Published erratum in Clinical Microbiology Reviews. 2021; 34. https://doi.org/10.1128/cmr.00021-21)

[35] Tamma PD, Heil EL, Justo JA, Mathers AJ, Satlin MJ, Bonomo RA. Infectious Diseases Society of America 2024 guidance on the treatment of antimicrobial-resistant Gram-negative infections. Clinical Infectious Diseases. 2024: ciae403. https://doi.org/10.1093/cid/ciae403