British Journal of Hospital Medicine

Br. J. Hosp. Med. (Lond) **2026**; 87(11): 55979
https://doi.org/10.31083/BJHM55979

Review

Pathophysiology, Detection and Intervention for Pathological Hip Fractures in Cancer Patients With Bone Metastasis

Lun Zhu[1,*], Ayden Ismail[1], Venkat Vadday[2], Aruni Ghose[3,4], Stergios Boussios[5,6,7,8,9]

[1]Department of Trauma and Orthopaedic Surgery, St Mary's Hospital, Isle of Wight NHS Trust, PO30 5TG Newport, UK
[2]Department of Internal Medicine, King George Hospital, Barking, Havering and Redbridge University Hospitals NHS Trust, RM1 2BA Romford, UK
[3]Department of Research and Innovation, Medway NHS Foundation Trust, ME7 5NY Gillingham, UK
[4]Cancer Division, University College London Hospitals NHS Foundation Trust, NW1 2PG London, UK
[5]Department of Medical Oncology, Medway NHS Foundation Trust, ME7 5NY Gillingham, UK
[6]United Kingdom and Ireland Global Cancer Network, M20 4BX London, UK
[7]Faculty of Medicine, Health and Social Care, Canterbury Christ Church University, CT1 1QU Canterbury, UK
[8]School of Cancer & Pharmaceutical Sciences, Faculty of Life Sciences & Medicine, King's College London, WC2R 2LS London, UK
[9]Kent and Medway Medical School, University of Kent, CT2 7FS Canterbury, UK
*Correspondence: ylunzhu@doctors.org.uk (Lun Zhu)

Academic Editor: Jianhua Liu
Submitted: 15 July 2026 Revised: 19 October 2026 Accepted: 27 October 2026 Published: 25 November 2026

Abstract

A fracture of the proximal femur, known as a hip fracture, is one of the most common presenting fractures for the emergency department and orthopaedic teams. Hip fractures contribute significant morbidity and mortality to patients, and considerable financial burden to healthcare systems. Whilst the vast majority of hip fracture cases are geriatric and traumatic, a small minority are atraumatic in aetiology, otherwise known as a pathological fracture, with malignancy responsible for some of these cases. The mainstay of pathological fracture management in the cancer patient is multidisciplinary team input alongside prophylactic intervention dependent on location, tumour, cortical integrity, patient life expectancy and operative suitability. A pathological hip fracture not only causes great reduction in independence and quality of life for all oncological patients, but also is a major harbinger for mortality, thus highlighting the significance in timely recognition, stratification risk, and management. This review aims to explore the current literature summarising the epidemiology and pathophysiology of hip fractures in the cancer patient, and clinical considerations in surgical management and current risk assessment tools such as Mirels' scoring, CT-based rigidity analysis (CTRA), Harrington's criteria, Capanna and Campanacci's classification, and PATHFx. We also discuss the major gaps in the current field regarding clinical accuracy and significance of diagnostic methods, risk calculation, and the surgical pathways available such as internal fixation, prosthetic replacement, or endoprosthetic reconstruction. Finally, we examine potential future pursuits in this field.

Keywords: pathological; hip fracture; metastasis; oncology; bone neoplasms

1. Introduction

Hip fractures represent a significant portion of geriatric healthcare and one of the most common admissions to an acute orthopaedic ward. Approximately 76,000 hip fractures occur within the UK each year [1], with the average age of a presenting patient being 82 years old [2]. The majority are due to a fall in the elderly population, and osteoporosis is the most prominent risk factor accounting for 60–85% of fracture susceptibility [3]. The morbidity and mortality associated with this injury is high, with approximately 28% of patients dying 1 year post-fracture [4]. Annually, hip fractures cost the National Health Service (NHS) approximately £2 billion (US$2.62 billion) [2].

A subset of patients exist who sustain a hip fracture as a result of an atraumatic, abnormal underlying process in the bone; a pathological fracture. Though other causes of pathological fracture may include metabolic bone disease and osteoporosis, this review will focus on the oncological cause of bone metastases. This subgroup represents an increasing concern in musculoskeletal oncology, due to the prevalence of the ageing population and increased cancer survival rates. Bone is a common site for metastatic potential in solid tumours, with a cumulative incidence of 8.4% at 10 years [5]. One third of these lesions will occur in the proximal femur [6]. In disrupting normal bone metabolism and weakening and replacing bone architecture with cancerous tissue, the transmission of mechanical load during weight-bearing results in pathological fracture. The most common tumours that metastasise to bone are advanced prostate, breast, renal, and thyroid. Prostate and breast cancer comprise most of all bone metastases, up to 70% [7]. It is also worth noting that for cancer patients undergoing chemotherapy, the rate of bone loss may be accelerated compared to post-menopausal osteoporosis in women [8].

The presence of bone metastases is a marker of short-term prognosis and disseminated disease—especially for certain cancers such as prostate with adjusted hazard ratio of 18.24 [9]. It is therefore crucial that pathological fractures

Copyright: © 2026 The Author(s). Published by IMR Press.
This is an open access article under the CC BY 4.0 license.

Publisher's Note: IMR Press stays neutral with regard to jurisdictional claims in published maps and institutional affiliations.

are widely recognised as a major risk in oncology patients, with appropriate and evidence-based detection and management, to best optimise quality of life and survival outcomes as well as better empower and inform patients. This article aims to provide a background of the pathophysiology of pathological bone metastases, risk evaluation methods, the means of surgical management, and the strength of current evidence and future direction.

2. Pathophysiology

Metastasis is a complex evolving process that involves the fundamental principles of loss of cellular adhesion, cellular migration, angiogenesis, invasion and survival of systemic circulation, immune evasion, adhesion and extravasation and growth in distant organs. Cancer cells must extravasate from bone marrow sinusoids into the marrow stroma, where they eventually activate bone resorption and reach the bone surface.

Various mechanisms have been proposed to explain the affinity of epithelial-type cancers for bone marrow. Facilitating factors include the rich vascular supply, haematopoietically active red bone marrow, cancer cells utilising adhesion molecules equivalent to vascular cellular adhesion molecule-1 (VCAM-1) and E-selectin required by haematopoietic stem cells to adhere and colonise bone marrow from the blood stream [10,11], receptor expression for chemoattractive cytokines such as C-X-C motif chemokine ligand 12 (CXCL12) usually secreted by bone marrow stromal/endothelial/osteoblasts for haematopoietic stem cell adhesion [12]. The mineral matrix of bone marrow also provides an environment of complex interplay of adhesion, migration, and growth for haematopoietic stem cells, with integrin interactions with osteopontin, bone sialoprotein, and collagen type 1—and indeed variation in such factors modifies prognosis and bone metastatic potential [13,14,15].

Bone metastases may be osteoblastic, osteolytic, or mixed. Osteoblastic and osteolytic metastases are apparent on plain radiograph as radiopaque or radiotransparent lesions respectively. As indicated by Table 1 (Ref. [16,17,18,19]) of the cancers most common for bone metastases, each primary tumour has varying likelihood as well as the histological appearance.

Table 1. Incidence of metastatic bone lesions in patients with metastatic solid tumours [16,17,18,19].

Type of primary tumour	Lytic/sclerotic/ mixed	Incidence of bone metastases in metastatic disease (%)
Prostate	Osteoblastic	84.8
Breast	Osteolytic	66.3
Lung	Osteoblastic Osteolytic	30–40
Renal cell	Osteolytic	28.3

Osteoblastic lesions, characterised by osteoblast-mediated deposition of new bone, still has a poorly understood mechanism. Prostate cancer, small cell lung cancer, and Hodgkin lymphoma present with osteoblastic metastases. It is thought the production of factors by cancer cells such as bone morphogenic proteins [20], transforming growth factor (TGF)-β [21], endothelin-1 [22], and upregulation of the Wnt signalling pathway [23] directly upregulate osteoblast proliferation.

Osteolytic lesions are mediated by osteoclastic processes rather than tumour cells directly [24], and present in breast cancer, renal cell carcinoma, melanoma, non-small cell lung cancer, non-Hodgkin lymphoma. Parathyroid hormone-related peptide (PTHrP) has a major role in bone metastatic osteolytic features, and is produced by most osteotropic cancers, and significantly correlates with clinical outcome and bone metastatic potential [25]. Known for also causing hypercalcaemia of malignancy, it stimulates osteoclast proliferation through inducing receptor activator of NF-kappaB ligand (RANKL) expression in osteoblastic cells and downmodulation of osteoprotegerin (OPG), subsequently increasing osteoclastic resorption with release of growth factors such as TGF-β, bone morphogenic proteins, insulin-like growth factor (IGF). Not only does this potentiate tumour growth, but also further secretion of PTHrP perpetuating a vicious positive cycle.

The biological behaviour of skeletal lesions varies by primary malignancy, influencing the pattern of bone destruction, fracture risk, prognosis and surgical management. Breast cancer metastases are predominantly osteolytic compared to prostate cancer typically producing osteoblastic lesions; however, the newly formed bone is often structurally abnormal and may coexist with increased bone resorption, so a sclerotic radiographic appearance does not necessarily indicate preserved mechanical strength. Lung cancer metastases are frequently osteolytic and can cause rapid cortical destruction and pathological fracture [26]. Renal cell carcinoma (RCC) commonly produces highly osteolytic, hypervascular lesions, particularly in the pelvis and femur. Extensive cortical destruction and limited reparative response can increase fracture risk and compromise fracture healing [27]. These examples demonstrate the histological importance of the cancer subtype and behaviour to guide subsequent management.

Emerging research has expanded the classical understanding of bone metastasis by demonstrating the importance of immune regulation, extracellular vesicles (EVs), cancer-associated fibroblasts (CAFs) and cellular heterogeneity within the metastatic bone niche. Tumour–immune interactions can promote immune evasion through regulatory T cells, exhausted cytotoxic T cells and immunomodulatory myeloid populations, thereby facilitating tumour persistence and progression [28]. Extracellular vesicles released by tumour and stromal cells transport proteins, lipids and non-coding RNAs that can modify recipient

Table 2. Mirels' scoring system in evaluating fracture risk for metastatic lesions.

Score	Site of lesion	Size of lesion	Nature of lesion	Pain
1	Upper limb	<1/3 cortex	Osteoblastic	Mild
2	Lower limb	1/3–2/3 cortex	Mixed	Moderate
3	Peri-trochanteric	>2/3 cortex	Osteolytic	Functional

cells, regulate osteoclast activity and remodel the pre-metastatic microenvironment [29]. CAFs further contribute to metastatic colonisation through extracellular matrix remodelling, chemokine signalling and interactions with immune and tumour cells [30]. These reinforce the concept of bone metastasis as a dynamic, multicellular process rather than a simple interaction between tumour cells and osteoclasts. In the context of pathological hip fractures, these advances may ultimately improve biological risk stratification and inform the development of adjunctive therapies.

3. Detection of Impending Fracture and Risk Evaluation

3.1 Fracture Risk Prediction and Assessment Tools

Various scoring systems exist to estimate the risk of impending fracture in those with metastatic lesions. Most commonly utilised is the Mirels' scoring system (Table 2) [31], dependent on 4 characteristics—the lesion site, nature (osteoblastic, osteolytic, mixed), size, and pain. Mirels' score originally proposed that lesions scoring ≤7 could be safely irradiated without prophylactic fixation, whereas those scoring ≥8 warranted prophylactic internal fixation. In contemporary practice, a score of 8 is often regarded as borderline, requiring clinical judgement, while scores ≥9 are generally considered a strong indication for prophylactic surgery.

There exists a few limitations with Mirels' scoring. The extent of cortical invasion is based on two-dimensions within the radiograph, and there is reduced sensitivity and specificity. With patients scoring 8, 'clinical judgement' is ambiguous and less certain in determining treatment.

CT-based rigidity analysis (CTRA) was developed by Nazarian et al. [32], whereby computed-tomography (CT) scan of the bone involved was obtained with hydroxyapatite phantom (CIRS Tissue Simulation and Phantom Technology) to convert each X-Ray attenuation pixel to bone mineral density. The final calculation indicates bone resistance to uniaxial, bending, and torsional load [32]. It provides 100% sensitivity versus 71.4% and 89.7% specificity versus 50% compared to the Mirels' score, due to limitations of two-dimensional representation and resolution, although these measurements cannot be generalised without consideration of the accessibility and reproducibility of CTRA, as well as individual factors such as radiation exposure. Clinically, though CTRA may have reduced accessibility, it may provide further information from inconclusive clinical assessment and Mirels' score.

Prior to developing Mirels' criteria, Harrington et al. [33] proposed four parameters indicating prophylactic fixation of the femur for impending fracture—more than 50% cortical bone destruction, the lesion being greater than 2.5 cm, a pathological avulsion fracture of the lesser trochanter, and functional pain post radiation therapy. However, aspects its criteria such as the radiographic evaluation has been questioned in terms of reliability and validity [34], and are oversimplified for clinical practice.

In 2001, Capanna and Campanacci [35] introduced an algorithm for long bone metastases to aid determination of management. It categorises patients into four groups according to the distribution and biological context of metastatic disease, the presence of an established pathological fracture, and the risk of fracture in weight-bearing bone. Class I comprises solitary metastatic lesions in patients with potentially favourable oncological prognoses; class II includes established pathological fractures; class III encompasses lesions considered at high risk of impending fracture in major weight-bearing bones; and class IV comprises other metastatic lesions (osteoblastic/osteolytic), including those that do not currently threaten structural integrity. Classes I–III are recommended for various means of surgical intervention with indicated subsequent adjuvant treatment, whilst Class IV should be treated conservatively with chemotherapy, radiation therapy, or hormonal therapy.

The classification is most applicable to adults with suspected or confirmed metastatic bone disease involving the proximal femur or the periacetabular region. The principle advantages are its relative simplicity, its integration of fracture status and oncological prognosis, and its usefulness as a shared framework for multidisciplinary treatment planning. However, the classification is not a validated stand-alone diagnostic tool or a quantitative predictor of fracture risk. It does not comprehensively account for lesion size, cortical destruction, pain severity, patient-specific functional demands, comorbidity, or contemporary systemic treatment options. Moreover, prognostic assumptions embedded in historical versions may not reflect outcomes with current oncological therapies. Accordingly, classification should be supplemented by clinical assessment, appropriate imaging, estimation of fracture risk, and individualised assessment of life expectancy and treatment goals.

3.2 Additional Assessments Supporting Surgical Decision-Making

Other modalities for evaluating risk of fracture and subsequent risk calculation have extended beyond classifications and utilised machine learning to aid the decision tool in being contemporary and accurate. PATHFx is a support tool developed to estimate postoperative survival in patients with skeletal metastases, therefore informing treatment planning for metastatic pathological fractures. Rather than classifying fractures by anatomical pattern or radiographic appearance, PATHFx utilise Bayesian belief network analysis, which is a statistical method to estimate outcome based on observed data and relationships between variables, to generate individualized probabilities of survival at predefined time points [36]. These models integrate patient-specific clinical and disease-related variables to estimate survival at 1, 3, 6, 12, 18 and 24 months. This can help support decisions regarding operative candidacy, the choice of reconstruction and implant durability, and the balance between surgical morbidity and anticipated functional benefit. Its advantages include the provision of quantitative, time-specific survival estimates, and external validation in independent international cohorts—however it focuses only on survival rather than fracture risk. Thus, these survival estimates should be interpreted alongside performance status, comorbidities, primary tumour biology, available systemic treatments and the patient's goals of care.

There may also be indirect means of measuring risk of fracture in cancer patients beyond purely pathological causes. With increasing survival time for cancer patients, they sustain greater risk of chronic metabolic diseases and lower bone density [37], thus highlighting the cruciality of early diagnosis to treat and lower risk of fracture, albeit from an osteoporotic (fragility fracture) viewpoint as opposed to secondary to metastases. Many studies have highlighted the risk of lower bone density, for example in breast cancer patients [38], gynaecological cancers [39], lung cancers [40] and melanoma [41].

Therefore, whilst osteoporotic fracture risk in cancer patients is not a focal discussion point in this paper discussing pathological fracture risk, bone mineral density (BMD) measurements may form part of monitoring and treatment for cancer-treatment-associated bone loss and indirect fracture risk. A primary modality of assessment is BMD measurement by dual-energy X-ray absorptiometry (DXA)—an internationally utilised method to assess fragility fracture risk. Screening with risk calculators such as fracture risk assessment tool (FRAX) and subsequent anti-osteoporotic medication may lead to relative risk reduction of hip fractures up to 17% [42]. A previous review summarised evidence from multiple clinical trials indicating that bisphosphonates can reduce skeletal-related events, including pathological fractures, the need for palliative radiation therapy, or hypercalcaemia [43]. It is of note that DXA/FRAX measurements is for the purposes of fragility fracture risk rather than the assessment of metastatic pathological fracture risk.

4. Surgical Intervention: Prevention and Treatment Strategies

Mortality for patients who sustain a pathological fracture of the hip has been estimated at 57% at 6 months and 43% at one year post-fracture [44]. Even compared to the relative morbidity and mortality from standard hip fractures, pathological fracture of the hip is a clear marker of poor prognosis. Therefore, this begs the question of the impact of early prophylactic surgical intervention on survivability and adverse outcomes of such cancer patients.

Deciding on intervention requires multidisciplinary input, including orthopaedic surgery, medical oncology, and physicians to obtain objective assessment of pre-existing medical comorbidities, cancer status, prognosis. Management may include conservative means, open reduction and internal fixation (ORIF), intramedullary nailing, prosthetic replacement, or endoprosthetic reconstruction—taking into consideration the location, tumour, cortical integrity, patient life expectancy.

Patients with trochanteric or subtrochanteric lesions may be managed with intramedullary nailing, plating, or dynamic hip screw (DHS). Typically, nailing may be considered in patients with subtrochanteric or extensive intertrochanteric lesions and sufficiently preserved bone integrity to support fixation, whilst ORIF may be used for smaller trochanteric lesions. Patients with a life expectancy of below 3 months or poor baseline function may be considered as candidates [45], as a means to relieve pain and enhance functionality alternatively, conservative management may be considered. A multicentre prospective cohort study reported clinically meaningful improvements in physical function and pain interference in 63.0% and 72.8% of patients, respectively, following orthopaedic surgery for metastatic bone disease [46]. However, postoperative complications and revision surgery remain important concerns. A systematic review reported revision rates ranging from 0% to 26.7% following internal fixation, including a revision rate of 13.3% in one ORIF cohort [47]. A separate study reported an implant breakage rate of 16.7% and a revision rate of 21.4% following DHS fixation [48]. It is also of note that with well-preserved bone integrity, radiotherapy or conservative management may be considered prior to fixation, accounting for impending fracture risk and other clinical considerations.

Prosthetic reconstruction may be more beneficial for patients with proximal lesions, extensive bone destruction, articular involvement, and tumour burden, as it allows quicker rehabilitation and reduces risk of implant failure, exchange, or non-union, particularly should the patient have a longer life expectancy. A population-based cohort study found that endoprosthetic reconstruction was associ-

ated with a lower risk of implant failure than osteosynthesis, and no significant difference in overall revision risk was observed [49], although this may be confounded by factors such as patient selection, primary tumour type, metastatic burden, prognosis, and selection of durability due to these factors. It is also associated with higher risks of infection and dislocation—although this may be mitigated with emerging techniques in dual mobility hip replacements.

Nonetheless, there is a statistically significant overall difference in patients prophylactically treated for imminent fracture compared to those managed for acute pathological fracture. On average, prophylactically treated patients have 143 days greater survival and suffer 8.8% reduced risk of perioperative mortality at 1 month [50].

It is important to consider perioperative complications in determining surgical management, which may include deep vein thrombus, pulmonary embolism, surgical site infection, postoperative pneumonia. All of these may have devastating effect, and even more so for an oncology patient. However, on balance overwhelmingly the evidence suggests improved mortality and secondary outcomes for management of impending fractures rather than treating complete. Whilst 90-day survival rate did not differ, suggesting no significance in perioperative survivability, 1 year survival was greater for prophylactic management [51]. Further to this, complete pathological fracture was more associated with greater intraoperative blood loss, blood transfusion requirements, and subsequent revision operations. Prophylactic fixation has been shown to significantly decrease perioperative risk of deep vein thrombus and pulmonary embolism compared to those patients undergoing fixation following complete pathological fractures [52].

Recent comparative evidence reinforces the need to balance these competing considerations. A 2025 systematic review and meta-analysis of 19 studies involving 4126 patients found that prosthetic reconstruction was associated with better functional outcomes and longer observed survival than internal fixation, whereas overall complication and reoperation rates did not differ significantly. Internal fixation was associated with shorter operative times and less blood loss [53].

There currently exists no formalised clinical decision-making surgical pathway for impending hip fractures, however, we propose a few key considerations in subsequent management (Fig. 1). Given the heterogeneous nature of pathological fractures of the hip, treatment selection should be guided by an integrated assessment of the underlying pathology, anatomical location, extent of osseous destruction, fracture configuration, patient prognosis and anticipated functional requirements.

5. Current Limitations and Future Direction

Despite advances in imaging, development in fracture-risk assessment, and orthopaedic oncology surgical techniques and adjuvant therapy, important limitations remain in the evidence supporting the prophylactic detection, diagnosis, and management of impending pathological fractures of the hip.

A central unresolved issue is the limited accuracy and generalisability of conventional fracture-risk assessment methods. For example, the most widely-used Mirels' scoring system's reliance on relatively subjective clinical and radiographic parameters can result in limited specificity, potentially leading to unnecessary surgical intervention in some patients. As discussed, further developed techniques such as CTRA seeks to improve this, however, observed fracture events has been limited and follow-up periods can be relatively short [32]. A further methodological challenge is that lesions identified as high risk are frequently stabilised by the surgeon's discretion before a fracture can occur. Whilst clinically appropriate, this may complicate validation of prediction and learning predictive models by treatment-selection bias. Further to this, there currently exists a lack of evidence pertaining to early diagnostic detection or screening for patients at risk of bony metastases, and this integration into their usual oncological management.

The current literature on impending pathological fractures encompasses different primary malignancies, metastatic tumour types, lesion characteristics, anatomical distributions, and patient prognoses, due to the complicated nature and presentation of orthopaedic oncology. Such heterogeneity limits direct comparison between studies and reduces the certainty with which pooled conclusions can be applied to individual patients. Thus, it is more difficult to determine the optimal timing and appropriate selection of prophylactic intervention. This would likely be related to balancing the predicted probability and consequence of pathological fracture against the operative morbidity, complication risk, survival, and independence. Better evidence is needed to identify which patients will derive the greatest net benefit.

The interventional approaches currently utilised for internal fixation and, endoprosthetic reconstruction differ in their mechanical properties, rehabilitation implications, and overall survival. Much of the comparative literature are retrospective studies, where the choice of the intervention may be determined by lesion location, the extent of bone destruction, expected survival, and surgeon preference. Whilst reasonable, it may be difficult to determine whether differences in outcomes reflect the intervention itself or underlying differences between the treated populations. Much of the outcome literature rests on determining fracture occurrence, operative complications and overall survival, whilst patient-reported outcomes such as pain relief, preservation of independent mobility, and quality of life may be underemphasised. These are all critical parameters to patients with advanced oncological disease. The competing mortality rate may also confound the interpretation of fracture-free survival, as patients may pass away before late complications occur. Future studies may in-

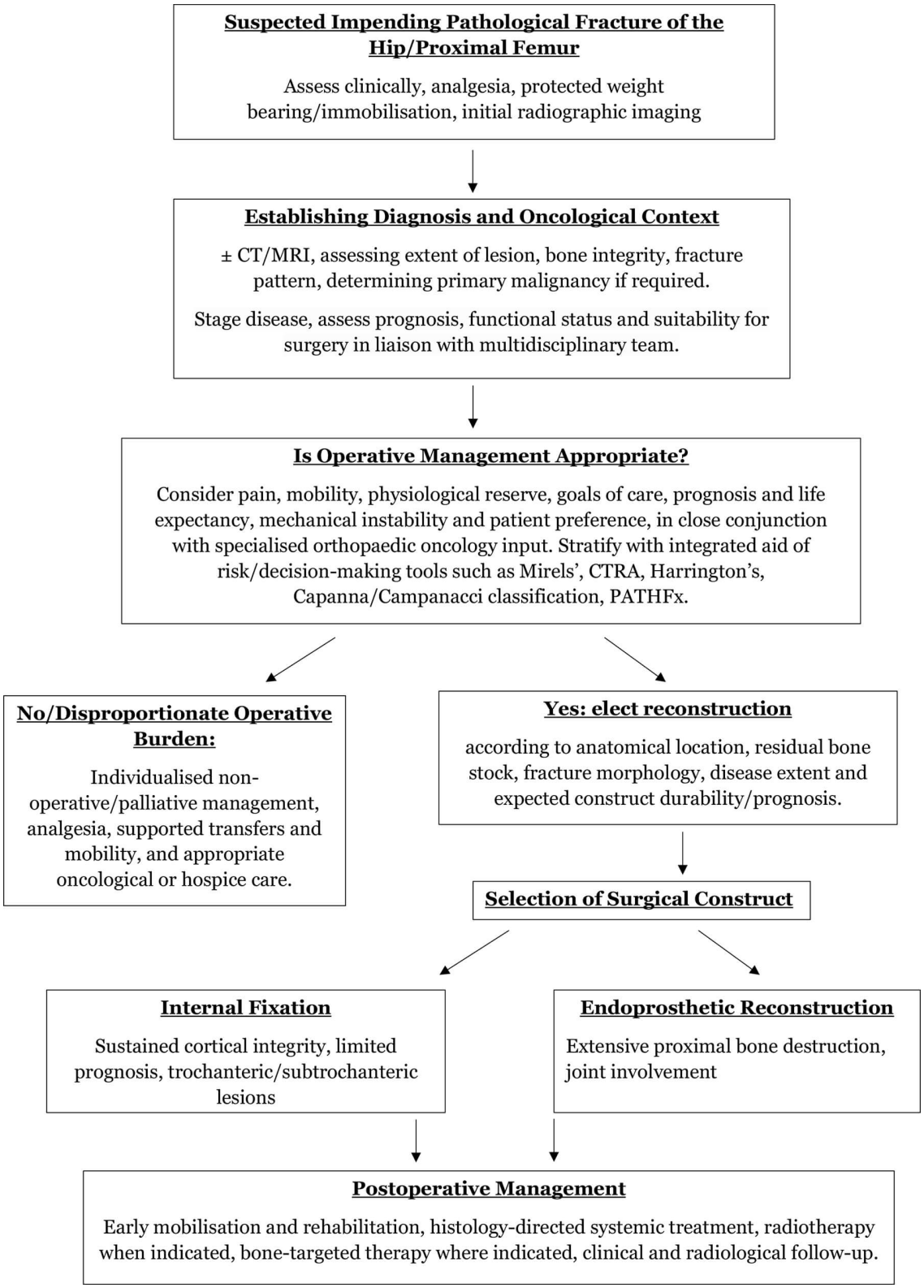

Fig. 1. Proposed pathway for management for adult patients with suspected or confirmed proximal femoral metastatic lesions, to aid multidisciplinary decision-making.

clude functional outcomes and sufficiently long follow up for early or late events. There may also exist the question of economic evaluation on the efficacy of various detection or intervention methods.

Pathological fractures of the proximal femur remain a major cause of morbidity in patients with metastatic bone

disease, with consequences extending beyond local skeletal complications to overall survival, continued systemic therapy, and functional independence. The importance of this outcome is underscored by a 2025 systematic review and meta-analysis by Lamo-Espinosa et al. [54], which included eight studies involving 15,464 patients with metastatic cancer. Compared with patients without pathological fractures, those who sustained a fracture had a higher adjusted risk of mortality (hazard ratio 1.31) and a shorter mean survival by 14.50 months. At the time of this paper, there is no universally adopted, validated clinical pathway integrating risk prediction with surgical selection.

The multisociety clinical practice guidelines from the Musculoskeletal Tumor Society, the American Society for Radiation Oncology, and the American Society of Clinical Oncology, reviewed by the American Academy of Orthopaedic Surgeons (AAOS), provides a framework for prevention and treatment [55]. It also considers bone-modifying agents to reduce femoral fracture risk (regardless of histology) and radiation therapy for lesions assessed as being at increased risk. For established pathological femoral fractures, arthroplasty should be considered when appropriate to improve function and reduce reliance on postoperative radiation therapy. These interventions should be selected according to the clinical circumstances rather than applied uniformly to all metastatic lesions.

AAOS educational guidance published in March 2026 further emphasizes the importance of choosing a reconstruction that remains mechanically reliable despite compromised bone quality and limited healing potential. For lesions involving the femoral head or neck, hemiarthroplasty or total hip arthroplasty may be preferable to internal fixation due to bone integrity compromise. For intertrochanteric and subtrochanteric disease, the options may include intramedullary fixation, a calcar-replacing stem, or proximal femoral replacement, depending on the extent of bone destruction, fracture configuration, tumour characteristics, and prognosis. There may exist future avenues to compare the outcomes of such reconstructive techniques.

Surgical management should also be integrated with the wider oncological treatment plan. Postoperative radiotherapy is commonly considered following stabilization or intralesional surgery to improve local disease control, while systemic treatment should be coordinated with the treating oncologist. Bisphosphonates or denosumab may be appropriate for selected patients with metastatic bone disease, taking account of tumour type, renal function, treatment-related risks, and other clinical factors. These measures are constantly evolving and complement mechanical stabilization but do not substitute for timely surgical assessment when a fracture is imminent.

Current British Orthopaedic Association Standards for Trauma (BOASt) guidelines state that all surgical interventions should outlast the remaining lifetime of the patient. However, there exists a lack of establishing a management pathway and method of prophylactic surgical intervention to best augment prognosis. This is likely due to the individual oncological nature and type of cancer, as well as overall consideration of patients' comorbidities, baseline functionality, and other modalities of cancer treatment.

With criteria in place to identify patients at high risk of pathological fracture, there exists a need to have standardised approach to prophylactic surgical intervention. As already demonstrated, a preventative approach yields greater outcomes in prognosis, morbidity, and mortality than an acutely curative approach. Previously discussed was the use of various scoring criteria to determine risk of impending fracture or indicators of bone quality, however there is not yet a standardised approach for determining the prognostic value of a surgical approach. Future advances in fields such as machine learning for the predictive value of surgical or conservative management have already indicated clinical utility for patients facing a broad range of prognoses.

It is also important to consider other oncological advances which work to better inform clinical decision making. This is constantly evolving, from understanding of immune involvement such as regulatory T cells and myeloid-derived suppressor cells, in modulating osteoclast activity, immune evasion and metastatic progression [56], to the bone microenvironment remodelling in influencing tumour-cell dormancy, phenotypic plasticity and treatment resistance [57]. So far, the discussion of radiographic evidence does not describe biological events, surgical planning should integrate anatomical and mechanical assessment with primary tumour histology, systemic disease burden, expected survival and response to systemic and bone-targeted therapies—all of which remains an important area for future research.

It is prudent to consider other approaches beyond purely conservative or surgical management, and how multidisciplinary effort may offer a broader range of choice, more minimally invasive procedures, and improved safety and efficacy. Different approaches such as utilising advancements in imaging techniques, percutaneous consolidation achieved through needle guidance, osteoplasty and pins, or cannulated screws gives interventional radiology a whole niche in management, achievable even under conscious sedation. Outcomes were comparable to surgical approaches in pain relief, complication rate, and relapsing fracture rate [58]. Thus, even in surgically unfit patients, this may offer a minimally invasive alternative to arthroplasty.

6. Conclusion

Hip fractures are predictors of poor prognosis and significant decrease in the quality of life in the standard presenting population, and present a growing public health concern. For cancer patients sustaining a pathological fracture secondary to metastases, the picture is bleaker

with greater mortality and evidence of disseminated disease. This is an increasing patient population, with hip bone metastases being a common extension of epithelial tumours. In light of modern oncological management advancements, oncology patients have increasing survivability and therefore increased opportunity for bone metastatic development. Several predictors in estimating impending fracture risk exist, alongside a variety of surgical methods that must be tailored to the individual's needs and preferences, with multidisciplinary input. The current evidence is pointing to preventative outcomes being better overall. Future work focusing on generating robust evidence to improve predictive value, machine learning, and multidisciplinary effort are crucial for continually improving patient outcomes and most importantly, preserving quality of life.

Key Points

• Pathological fracture of the hip is a prevalent oncological issue, and is a poor indicator of prognosis.

• Cancer has great affinity for bone metastases through a favourable bone microenvironment.

• Surgical intervention for an impending fracture leads to better overall outcomes for the patient.

• There exist several scoring systems to better predict the chance of pathological fracture of the hip, each with its various benefits and drawbacks.

• There exists various means of surgical intervention including ORIF, intramedullary nailing, DHS, or endoprosthetic reconstruction.

• There does not yet exist a formalised pathway in surgical management due to the complexity of individual patient background and cancer profiles, thus requiring strong multidisciplinary collaboration.

Availability of Data and Materials

Not applicable.

Author Contributions

LZ: Conceptualisation, Methodology, Writing—original draft, Visualisation. AI: Conceptualisation, Methodology. VV and AG: Conceptualisation. SB: Conceptualisation, Methodology, Supervision. All authors contributed to revising the manuscript critically for important intellectual content. All authors read and approved the final manuscript. All authors have participated sufficiently in the work and agreed to be accountable for all aspects of the work.

Ethics Approval and Consent to Participate

Not applicable.

Acknowledgment

Not applicable.

Funding

This research received no external funding.

Conflicts of Interest

Given his role as an Editorial Board Member, Stergios Boussios had no involvement in the peer-review of this article and has no access to information regarding its peer-review. Full responsibility for the editorial process for this article was delegated to Jianhua Liu.

References

[1] Royal College of Physicians. A broken hip - three steps to recovery: The 2024 National Hip Fracture Database report on 2023. 2024. Available at: https://www.nhfd.co.uk/2024report (Accessed: 15 June 2026).

[2] Royal College of Physicians. Room for improvement: hip fracture care in 2024: The 2025 National Hip Fracture Database report on 2024. 2025. Available at: https://www.nhfd.co.uk/2025report (Accessed: 15 June 2026).

[3] Li L, Bennett-Brown K, Morgan C, Dattani R. Hip fractures. British Journal of Hospital Medicine. 2020; 81: 1–10. https://doi.org/10.12968/hmed.2020.0215

[4] Baji P, Patel R, Judge A, Johansen A, Griffin J, Chesser T, et al. Organisational factors associated with hospital costs and patient mortality in the 365 days following hip fracture in England and Wales (REDUCE): a record-linkage cohort study. The Lancet. Healthy Longevity. 2023; 4: e386–e398. https://doi.org/10.1016/S2666-7568(23)00086-7

[5] Hernandez RK, Wade SW, Reich A, Pirolli M, Liede A, Lyman GH. Incidence of bone metastases in patients with solid tumors: analysis of oncology electronic medical records in the United States. BMC Cancer. 2018; 18: 44. https://doi.org/10.1186/s12885-017-3922-0

[6] Hage WD, Aboulafia AJ, Aboulafia DM. Incidence, location, and diagnostic evaluation of metastatic bone disease. The Orthopedic Clinics of North America. 2000; 31: 515–vii. https://doi.org/10.1016/s0030-5898(05)70171-1

[7] Cecchini MG, Wetterwald A, Pluijm GVD, Thalmann GN. Molecular and Biological Mechanisms of Bone Metastasis. EAU Update Series. 2005; 3: 214–226. https://doi.org/10.1016/j.euus.2005.09.006

[8] Nisha Y, Dubashi B, Bobby Z, Sahoo JP, Kayal S, Anantha krishnan R, et al. Cytotoxic chemotherapy is associated with decreased bone mineral density in postmenopausal women with early and locally advanced breast cancer. Archives of Osteoporosis. 2023; 18: 41. https://doi.org/10.1007/s11657-023-01231-z

[9] Zhang J, Cai D, Hong S. Prevalence and prognosis of bone metastases in common solid cancers at initial diagnosis: a population-based study. BMJ Open. 2023; 13: e069908. https://doi.org/10.1136/bmjopen-2022-069908

[10] Dimitroff CJ, Lechpammer M, Long-Woodward D, Kutok JL. Rolling of human bone-metastatic prostate tumor cells on human bone marrow endothelium under shear flow is mediated by E-selectin. Cancer Research. 2004; 64: 5261–5269. https://doi.org/10.1158/0008-5472.CAN-04-0691

[11] Dimitroff CJ, Descheny L, Trujillo N, Kim R, Nguyen V, Huang W, et al. Identification of leukocyte E-selectin ligands, P-selectin glycoprotein ligand-1 and E-selectin ligand-1, on human metastatic prostate tumor cells. Cancer Research. 2005; 65: 5750–5760. https://doi.org/10.1158/0008-5472.CAN-04-4653

[12] Balkwill F. Cancer and the chemokine network. Nature Reviews. Cancer. 2004; 4: 540–550. https://doi.org/10.1038/nrc1388

[13] Thalmann GN, Sikes RA, Devoll RE, Kiefer JA, Markwalder R, Klima I, et al. Osteopontin: possible role in prostate cancer progression. Clinical Cancer Research. 1999; 5: 2271–2277.
[14] Zhang JH, Wang J, Tang J, Barnett B, Dickson J, Hahsimoto N, et al. Bone sialoprotein promotes bone metastasis of a non-bone-seeking clone of human breast cancer cells. Anticancer Research. 2004; 24: 1361–1368.
[15] Adwan H, Bäuerle TJ, Berger MR. Downregulation of osteopontin and bone sialoprotein II is related to reduced colony formation and metastasis formation of MDA-MB-231 human breast cancer cells. Cancer Gene Therapy. 2004; 11: 109–120. https://doi.org/10.1038/sj.cgt.7700659
[16] Kadeerhan G, Xue B, Wu XL, Chen WN, Wang DW. Incidence trends and survival of metastatic prostate cancer with bone and visceral involvement: 2010-2019 surveillance, epidemiology, and end results. Frontiers in Oncology. 2023; 13: 1201753. https://doi.org/10.3389/fonc.2023.1201753
[17] Chen F, He B, Wang Y. Bone metastases among newly diagnosed cancer patients: a population-based study. Postgraduate Medical Journal. 2024; 100: 569–577. https://doi.org/10.1093/postmj/qgae036
[18] So KWL, Leung EMC, Ng T, Tsui R, Cheung JPY, Choi SW. Machine Learning Models to Predict Bone Metastasis Risk in Patients With Lung Cancer. Cancer Medicine. 2024; 13: e70383. https://doi.org/10.1002/cam4.70383
[19] Challapalli A, Ratnayake G, McGrane J, Frazer R, Gupta S, Parslow DS, et al. 1463P Patterns of care and outcomes of metastatic renal cell carcinoma (mRCC) patients (pts) with bone metastases (BM): A UK multicenter review. Annals of Oncology. 2022; 33: S1215. https://doi.org/10.1016/j.annonc.2022.07.1566
[20] Keller ET, Zhang J, Cooper CR, Smith PC, McCauley LK, Pienta KJ, et al. Prostate carcinoma skeletal metastases: cross-talk between tumor and bone. Cancer Metastasis Reviews. 2001; 20: 333–349. https://doi.org/10.1023/a:1015599831232
[21] Harris SE, Bonewald LF, Harris MA, Sabatini M, Dallas S, Feng JQ, et al. Effects of transforming growth factor beta on bone nodule formation and expression of bone morphogenetic protein 2, osteocalcin, osteopontin, alkaline phosphatase, and type I collagen mRNA in long-term cultures of fetal rat calvarial osteoblasts. Journal of Bone and Mineral Research. 1994; 9: 855–863. https://doi.org/10.1002/jbmr.5650090611
[22] Nelson JB, Hedican SP, George DJ, Reddi AH, Piantadosi S, Eisenberger MA, et al. Identification of endothelin-1 in the pathophysiology of metastatic adenocarcinoma of the prostate. Nature Medicine. 1995; 1: 944–949. https://doi.org/10.1038/nm0995-944
[23] Emami KH, Corey E. When prostate cancer meets bone: control by wnts. Cancer Letters. 2007; 253: 170–179. https://doi.org/10.1016/j.canlet.2006.12.040
[24] Taube T, Elomaa I, Blomqvist C, Beneton MN, Kanis JA. Histomorphometric evidence for osteoclast-mediated bone resorption in metastatic breast cancer. Bone. 1994; 15: 161–166. https://doi.org/10.1016/8756-3282(94)90703-x
[25] Zhao Y, Lu SM, Zhong B, Wang GC, Jia RP, Wang Q, et al. Parathyroid hormone related-protein (PTHrP) in tissues with poor prognosis in prostate cancer patients. Medicine. 2024; 103: e37934. https://doi.org/10.1097/MD.0000000000037934
[26] Deng M, Ding H, Zhou Y, Qi G, Gan J. Cancer metastasis to the bone: Mechanisms and animal models (Review). Oncology Letters. 2025; 29: 221. https://doi.org/10.3892/ol.2025.14967
[27] Cesana B, Cochet C, Filhol O. New players in the landscape of renal cell carcinoma bone metastasis and therapeutic opportunities. International Journal of Cancer. 2025; 156: 475–487. https://doi.org/10.1002/ijc.35181
[28] Hiraga T. Immune microenvironment of cancer bone metastasis. Bone. 2025; 191: 117328. https://doi.org/10.1016/j.bone.2024.117328
[29] Li Y, Zheng Y, Tan X, Du Y, Wei Y, Liu S. Extracellular vesicle-mediated pre-metastatic niche formation via altering host microenvironments. Frontiers in Immunology. 2024; 15: 1367373. https://doi.org/10.3389/fimmu.2024.1367373
[30] Xie J, Lin X, Deng X, Tang H, Zou Y, Chen W, et al. Cancer-associated fibroblast-derived extracellular vesicles: regulators and therapeutic targets in the tumor microenvironment. Cancer Drug Resistance. 2025; 8: 2. https://doi.org/10.20517/cdr.2024.152
[31] Mirels H. Metastatic disease in long bones. A proposed scoring system for diagnosing impending pathologic fractures. Clinical Orthopaedics and Related Research. 1989; 256–264.
[32] Nazarian A, Entezari V, Zurakowski D, Calderon N, Hipp JA, Villa-Camacho JC, et al. Treatment Planning and Fracture Prediction in Patients with Skeletal Metastasis with CT-Based Rigidity Analysis. Clinical Cancer Research. 2015; 21: 2514–2519. https://doi.org/10.1158/1078-0432.CCR-14-2668
[33] Harrington KD. New trends in the management of lower extremity metastases. Clinical Orthopaedics and Related Research. 1982; 53–61.
[34] Keene JS, Sellinger DS, McBeath AA, Engber WD. Metastatic breast cancer in the femur. A search for the lesion at risk of fracture. Clinical Orthopaedics and Related Research. 1986; 282–288.
[35] Capanna R, Campanacci DA. The treatment of metastases in the appendicular skeleton. The Journal of Bone and Joint Surgery. British Volume. 2001; 83: 471–481. https://doi.org/10.1302/0301-620x.83b4.12202
[36] Overmann AL, Clark DM, Tsagkozis P, Wedin R, Forsberg JA. Validation of PATHFx 2.0: An open-source tool for estimating survival in patients undergoing pathologic fracture fixation. Journal of Orthopaedic Research. 2020; 38: 2149–2156. https://doi.org/10.1002/jor.24763
[37] Buzasi E, Carreira H, Funston G, Mansfield KE, Forbes H, Strongman H, et al. Risk of fractures in half a million survivors of 20 cancers: a population-based matched cohort study using linked English electronic health records. The Lancet. Healthy Longevity. 2024; 5: e194–e203. https://doi.org/10.1016/S2666-7568(23)00285-4
[38] Bostany GS, Chen Y, Francisco L, Sparks JR, York M, Sessions M, et al. New-onset osteopenia/osteoporosis among long-term survivors of breast cancer: Role of hormone therapies and metabolic risk factors. Journal of Clinical Oncology. 2025; 43: 12046–12046. https://doi.org/10.1200/jco.2025.43.16_suppl.12046
[39] Sobecki J, Weigman B, Anderson-Carter I, Barroilhet L, Chandereng T, Kliewer M, et al. Opportunistic osteoporosis screening using routine computed tomography images to identify bone loss in gynecologic cancer survivors. International Journal of Gynecological Cancer. 2022; 32: 1050–1055. https://doi.org/10.1136/ijgc-2021-003169
[40] Ebstein E, Brocard P, Soussi G, Khoury R, Forien M, Khalil A, et al. Burden of comorbidities: Osteoporotic vertebral fracture during non-small cell lung cancer - the BONE study. European Journal of Cancer. 2024; 200: 113604. https://doi.org/10.1016/j.ejca.2024.113604
[41] Baddi S, Suarez D, Ruet A, Van Butsel T, Cerasuolo D, Rat AC, et al. Changes in scanographic bone mineral density in melanoma patients treated with immunotherapy: a new irAE from real-life data. Scientific Reports. 2025; 15: 24600. https://doi.org/10.1038/s41598-025-08974-4
[42] Kahwati LC, Kistler CE, Booth G, Sathe N, Gordon RD, Okah E, et al. Screening for Osteoporosis to Prevent Fractures: A Systematic Evidence Review for the US Preventive Services Task

Force. JAMA. 2025; 333: 509–531. https://doi.org/10.1001/jama.2024.21653
[43] Polascik TJ. Bisphosphonates in oncology: evidence for the prevention of skeletal events in patients with bone metastases. Drug Design, Development and Therapy. 2009; 3: 27–40.
[44] Kilk K, Kask G, Nieminen J, Laitinen MK. Metastatic bone disease in proximal femur. Outcome of surgical treatments. - Do we know what to do? Journal of Bone Oncology. 2025; 54: 100711. https://doi.org/10.1016/j.jbo.2025.100711
[45] Wedin R, Bauer HCF. Surgical treatment of skeletal metastatic lesions of the proximal femur: endoprosthesis or reconstruction nail? The Journal of Bone and Joint Surgery. British Volume. 2005; 87: 1653–1657. https://doi.org/10.1302/0301-620X.87B12.16629
[46] Groundland J, Tokson JH, Hakim A, Cizik A, Blank A, Lerman D, et al. Length of Time to Clinical Improvement After Orthopedic Oncology Surgery in Patients With Metastatic Cancer: A Multi-Institution Patient-Reported Outcome Study. Journal of Surgical Oncology. 2025; 131: 955–964. https://doi.org/10.1002/jso.27932
[47] Iljazi A, Andersen MS, Brorson S, Petersen MM, Sørensen MS. Surgical management of metastatic lesions in the proximal femur: a systematic review. EFORT Open Reviews. 2025; 10: 104–114. https://doi.org/10.1530/EOR-24-0138
[48] Chou KC, Lee KH, Chen CM, Lin YK, Wu PK, Chen CF, et al. Comparison of treatment options with long intramedullary nail and dynamic hip screws for metastatic subtrochanteric fracture: A cohort study. Journal of the Chinese Medical Association. 2026; 89: 76–84. https://doi.org/10.1097/JCMA.0000000000001322
[49] Zarifkar P, Ladegaard TH, Iljazi A, Petersen MM, Sørensen MS. Endoprosthetic reconstruction versus osteosynthesis for metastatic disease of the proximal femur: a population-based cohort study. Journal of Bone Oncology. 2026; 60: 100796. https://doi.org/10.1016/j.jbo.2026.100796
[50] Hershkovich O, Sakhnini M, Barkay G, Liberman B, Friedlander A, Lotan R. Femoral metastatic pathological fractures, impending and actual fractures – A patient survival study. Surgical Oncology. 2023; 51: 102014. https://doi.org/10.1016/j.suronc.2023.102014
[51] Groot OQ, Lans A, Twining PK, Bongers MER, Kapoor ND, Verlaan JJ, et al. Clinical Outcome Differences in the Treatment of Impending Versus Completed Pathological Long-Bone Fractures. The Journal of Bone and Joint Surgery. American Volume. 2022; 104: 307–315. https://doi.org/10.2106/JBJS.21.00711
[52] Christ AB, Piple AS, Gettleman BS, Duong A, Chen M, Wang JC, et al. Prevalence of primary malignant tumours, rates of pathological fracture, and mortality in the setting of metastatic bone disease. Bone & Joint Open. 2023; 4: 424–431. https://doi.org/10.1302/2633-1462.46.BJO-2023-0042.R1
[53] Lai YS, Chuang SH, Kuo YJ, Cheng SJ, Chen YP. Comparative outcomes of internal fixation versus prosthetic reconstruction in the treatment of proximal femoral metastases: a systematic review and meta-analysis. EFORT Open Reviews. 2025; 10: 842–850. https://doi.org/10.1530/EOR-2024-0131
[54] Lamo-Espinosa JM, Mariscal G, Gómez-Álvarez J, Khalil I, San-Julián M. Survival impact of pathological fractures in metastatic cancer: a comprehensive meta-analysis. Archives of Orthopaedic and Trauma Surgery. 2025; 145: 253. https://doi.org/10.1007/s00402-025-05852-6
[55] Wodajo F, Colman M, Getty P. AAOS Clinical Practice Guideline Summary: Treatment of Metastatic Carcinoma and Myeloma of the Femur. The Journal of the American Academy of Orthopaedic Surgeons. 2023; 31: e118–e129. https://doi.org/10.5435/JAAOS-D-21-00888
[56] Bhale R, Ghosh P, Theriault R, Thorpe S, Loots G, Randall RL. The dynamic microenvironment associated with metastatic bone disease: Current concepts. Journal of Surgical Oncology. 2023; 128: 468–477. https://doi.org/10.1002/jso.27354
[57] Bruschi A, Sambri A, Fiore M, Bubbico E, Scollo C, Pace A, et al. Inside a Metastatic Fracture: Molecular Bases and New Potential Therapeutic Targets. Cancer Medicine. 2025; 14: e70901. https://doi.org/10.1002/cam4.70901
[58] Roux C, Tselikas L, Delpla A, Yevich S, Teriitehau C, Hakime A, et al. Percutaneous Fixation of Impending Fracture of the Hip. Techniques in Vascular and Interventional Radiology. 2022; 25: 100802. https://doi.org/10.1016/j.tvir.2022.100802