Clinical and Experimental Obstetrics & Gynecology

Clin. Exp. Obstet. Gynecol. **2024**; 51(10): 217
https://doi.org/10.31083/j.ceog5110217

Original Research

The Effects of Quercetin on the Expression of Collagen I, Collagen III and Elastin in Vaginal: An Experimental Animal Study

Tri Hastono Setyo Hadi[1,*], Gatut Hardianto[1], Eighty Mardiyan Kurniawati[1], Harry Parathon[1], Ira Sari Yudaniayanti[2], Budi Utomo[3], Budi Iman Santoso[4]

[1]Department of Obstetrics and Gynecology, Universitas Airlangga, 60286 Surabaya, Indonesia
[2]Division of Veterinary Clinic, Faculty of Veterinary Medicine, Universitas Airlangga, 60286 Surabaya, Indonesia
[3]Department of Public Health and Preventive Medicine, Universitas Airlangga, 60286 Surabaya, Indonesia
[4]Department of Obstetrics and Gynecology, Universitas Indonesia, 10430 Jakarta, Indonesia
*Correspondence: dr.trihastonosh@gmail.com (Tri Hastono Setyo Hadi)
Academic Editor: Michael H. Dahan
Submitted: 18 May 2024 Revised: 22 July 2024 Accepted: 1 August 2024 Published: 29 September 2024

Abstract

Background: Vulvovaginal atrophy is part of the genitourinary syndrome of menopause caused by hypoestrogenic changes. This pathophysiological mechanism alters the concentration of collagen and elastin, which modifies the vaginal mucosa and impairs the function of the pelvic floor muscles. Quercetin is one of the flavonols found in plants, fruits, and vegetables. Quercetin helps to improve the syndrome through a variety of actions and estrogen-like effects. This study aimed to analyze the impact of quercetin on collagen I, collagen III, and elastin in a vaginal menopausal rat model. **Method**: This study's research design was an *in vivo* randomized control group post-test. The research was conducted at the animal laboratory, Faculty of Medicine, Universitas Airlangga. Rattus norvegicus, used in the study, were divided into 5 groups: normal rat, menopausal model without treatment, menopausal model given 17-β estradiol valerate 0.18 mg/kg, quercetin 12.5 mg/kg, and quercetin 50 mg/kg. The effectiveness of therapy was assessed from the immunohistochemical expression of collagen I, collagen III, and elastin in vaginal tissue. **Results**: The standard group in this study had the highest average expression levels of collagen I and elastin. The group of menopausal models without treatment in the study had the highest average expression of collagen III. Collagen I expression ($p < 0.001$), collagen III expression ($p < 0.001$), and elastin expression ($p < 0.001$) all showed significant differences. The menopausal rat model without treatment and the standard group showed the most differences in the expression of collagen I, collagen III, and elastin. **Conclusions**: The expression of collagen I, collagen III, and elastin in the vagina of the menopausal model was affected by the administration of quercetin at a level of 50 mg/kg. Thus, quercetin can be an alternative herbal treatment option to improve vulvovaginal atrophy in menopausal conditions.

Keywords: quercetin; collagen I; collagen III; elastin; menopause; vulvovaginal atrophy

1. Introduction

The condition of hypoestrogenism associated with menopause has a negative impact on the health of the vagina and urinary tract, known as the genitourinary syndrome of menopause (GSM). Genital signs and symptoms such as dryness, burning, irritation, and sexual symptoms such as discomfort or pain were previously known as vulvovaginal atrophy (VVA). GSM occurs in 15% of premenopausal women, while around 50–70% occur in postmenopausal women and will tend to get worse during menopause [1].

The hypoestrogenic environment of urogenital tissue causes changes in the thickness of the vaginal epithelium and lamina propria, smooth muscle atrophy, reduced blood flow to the vaginal area, and loss of tissue elasticity due to decreased concentrations of collagen, elastin, and hyaluronic acid. The effects of these pathophysiological mechanisms produce changes in the urogenital system, especially changes in the vaginal mucosa. In the lower urinary tract, they affect the capacity and contractile ability of the bladder, urethral sphincter, and pelvic floor muscle function [2].

Collagen I and collagen III represent the primary constituents of the extracellular matrix, exerting substantial influence on the biomechanical attributes of the vaginal tissue. Their distinct fiber diameters result in divergent mechanical properties, with collagen I predominantly contributing to tensile strength and stiffness, while collagen III confers flexibility to the tissue [3]. Elastin's primary function is to offer resilience to tissues that experience repetitive stretching and physical strain [4].

Flavonoids are a group of natural substances often found in foods and drinks originating from plants, such as fruit, vegetables, and tea [5]. Flavonoids have anti-oxidative, anti-inflammatory, anti-mutagenic, and anti-carcinogenic properties in flavonoids and can modulate the function of vital cellular enzymes [5]. Flavonoids are widely used for the treatment of menopausal symptoms, although it is currently unclear whether they can prevent or alleviate other menopausal changes [6]. One of the most common flavonoids is quercetin. Quercetin is a phytoestrogen that has estrogenic activity. Many molecular and clinical data support the effects of estrogen receptors on normal

Copyright: © 2024 The Author(s). Published by IMR Press.
This is an open access article under the CC BY 4.0 license.

Publisher's Note: IMR Press stays neutral with regard to jurisdictional claims in published maps and institutional affiliations.

skin homeostasis and may accelerate re-epithelialization in wound healing [7]. Several *in vivo* and *in vitro* studies have been carried out to look for evidence of the influence of quercetin, but there is no research explicitly discussing their effect on connective tissue in menopausal women. This research was carried out on experimental animals to analyze the impact of quercetin on the vagina so that it can be the first step in understanding the role of quercetin in vulvovaginal atrophy.

2. Materials and Methods

2.1 Study Design and Samples Collection

The study's design was a laboratory experimental investigation with an *in vivo* randomized control group posttest-only design. This study focused on a Wistar rat (*Rattus norvegicus*) model of menopause. The study was conducted at the Experimental Animal Laboratory at Airlangga University's Surabaya Medical Faculty from November 2022 to March 2023. The relevant Research Ethics Committee approved the protocol regarding research procedures carried out on animals. This research has been tested for ethical feasibility at the Faculty of Medicine, Airlangga University, to meet the ethical requirements for experimental animals. The study's population included female Wistar rats (*Rattus norvegicus*) from the Experimental Animal Laboratory at Airlangga University's Surabaya Medical Faculty. The sample contained a female Wistar rat weighing 200–300 grams. The total sample size in this study was 30 samples separated into five groups, each containing six samples.

Group K0 consisted of non-menopausal rats not receiving therapy and served as the control group. Group K1 consisted of menopausal model rats who received no treatment and served as the control group. Group K2 comprised menopausal model rats who received oral estrogen treatment (17-β estradiol-Progynova preparation dose 0.18 mg/kgBW). Group K3 included menopausal model rats who received oral quercetin (12.5 mg/kgBW). Group K4 comprised menopausal model rats who received oral quercetin (50 mg/kgBW). Treatment was given for a duration of 21 days (Fig. 1).

2.2 Menopause Rat Model

Preoperative preparation involved acclimatizing rats for two weeks from the breeding source. Before the surgery, thirty rats underwent health checks, and their weight was measured using a digital weighing machine (SF-400, Zhejiang Mengxuan Electronic Co., Ltd., Jinhua, Zhejiang, China). The animals were anesthetized with a combination of 50 mg/kgBW ketamine and 10 mg/kgBW xylazine. Once anesthetized, rats underwent fur shaving and surgical site disinfection. A midline dorsal skin incision with 3 cm long preceded bilateral ovariectomy. After the muscle dissection, the peritoneal space and adipose tissue surrounding the ovary were exposed. After identifying the ovary and uterine horn, a vicryl sutures-3/0 was performed around the area of the distal uterine horns, which was sectioned after that, and the ovaries were removed. The procedure was repeated for the left ovary [8,9]. In the K0 group, only laparotomy was performed without bilateral ovariectomy. Postoperative wound care included the application of iodine tincture, dressing replacement, as well as administration of enrofloxacin antibiotic at a dose of 5 mg/kgBW and Tolfenamic acid analgesic at a dose of 4 mg/kgBW for three days.

2.3 Quercetin Treatment

Flavonoids in the form of Quercetin (C15H10O7, Sigma-Aldrich Co - Merck KGaA, Darmstadt, Germany). In the *in vivo* therapeutic model, experimental rats received intraoral doses. Group quercetin dose 1 received 12.5 mg/kgBW, while group quercetin dose 2 received 50 mg/kgBW.

2.4 Estrogen Treatment

The powder of 17-β estradiol valerate Progynova® (Bayer, Leverkusen, Germany) weighing 6.5 mg was gradually added to a suspension of sodium carboxymethyl cellulose (Na-CMC) 0.5% w/v while being stirred until homogeneous. The suspension of 17-β estradiol valerate was then transferred into a 10 mL volumetric flask, followed by the addition of Na-CMC 0.5% suspension up to the mark.

2.5 Immunohistochemical Staining

After the intervention had been completed, euthanasia was carried out on the experimental animals by previously anesthetizing them with isoflurane. Then, the implementation of euthanasia according to the Institutional Animal Care and Use Committee (IACUC) using the cervical dislocation method [10]. Vaginal organ collection was then carried out. In immunohistochemical staining, the initial step involved preparing the specimen slides by deparaffinization and rehydration using an oven and a series of xylene and ethanol solutions with appropriate concentrations. Furthermore, if necessary, the antigen retrieval procedures were performed using enzyme retrieval agents such as trypsin or protease at 37 °C for 2–30 minutes. The subsequent process involved the inactivation of endogenous peroxidase by incubating with 3% hydrogen peroxide for 5 minutes, mainly when using peroxidase-conjugated secondary antibodies or ExtrAvidin-Peroxidase. The antibodies used in this study were obtained from Genetex (Irvine, CA, USA), with batch numbers GTX26308, GTX60940, and GTX37428, and were diluted at a ratio of 1:500. Primary antibodies, including those for collagen I, collagen III, and elastin, were applied to the slides with a minimum incubation period of 60 minutes at 37 °C, followed by reaction with biotinylated secondary antibody (1:100; Starr Trek Universal HRP Detection, Biocare Medical, Pacheco, CA, USA; STUHRP700) and washing with phosphate buffered saline (PBS). A substrate mixture was prepared and utilized for color reaction development, with an incubation period of 5–10 minutes or until the desired color reaction was ob-

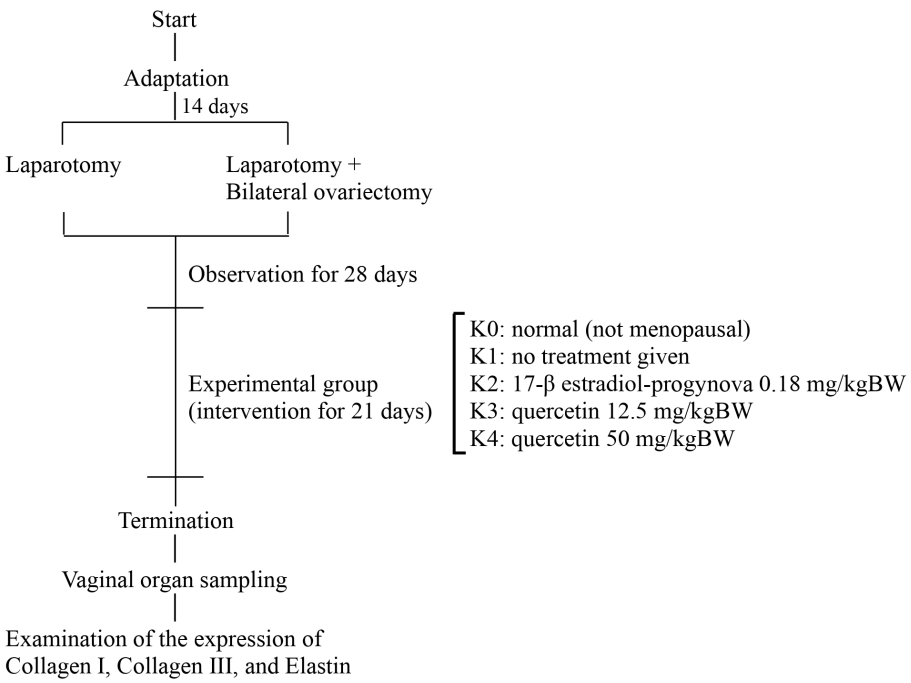

Fig. 1. Experimental procedures for rat and quercetin administration.

served. Subsequently, counter-staining was performed using hematoxylin Mayer, with an incubation period of 0.5–5 minutes, followed by washing with distilled water. Finally, the slides were mounted using an aqueous mounting medium such as gelatin glycerol and sealed with clear nail polish.

2.6 Immunohistochemical Examination

Evaluation of collagen I, collagen III, and elastin expression was conducted using the modified Remmele method. The Remmele scoring index (Immuno Reactive Score, IRS) was obtained by multiplying the score of the percentage of positive immunoreactive cells or area with the score of color intensity in immunoreactive cells. Data from each sample represented the average IRS value observed in 5 fields of view at 1000 times magnification [11].

2.7 Statistical Analysis

Research data will be recorded in the data collection form. Then, a normality test was carried out using the Shapiro-Wilk test. If the distribution is normal ($p > 0.05$), a One-Way analysis of variance (ANOVA) test will be carried out to compare the means of the dependent variables between the three groups and continue with the Least Significant Difference (LSD) post hoc test. A p-value below 0.05 was statistically significant. Statistical calculations will use SPSS software tools (version 24, IBM Corp., Chicago, IL, USA).

3. Results

3.1 Immunohistochemical Examination Results of Collagen I

The highest average expression of collagen I was observed in the control group of untreated normal rats (10.13 $\pm$ 1.32), followed by the menopausal model rats treated with 17-β estradiol valerate Progynova 0.18 mg/kgBW (8.70 $\pm$ 0.68), menopausal model rats treated with quercetin 50 mg/kgBW (6.97 $\pm$ 1.02), and menopausal model rats treated with quercetin 12.5 mg/kgBW (4.76 $\pm$ 1.28), while the lowest average was in the control group of untreated menopausal model rats (3.90 $\pm$ 0.90). Further analysis using the One-Way ANOVA statistical test to assess the difference in collagen I expression between groups with the result of $p < 0.001$ (Table 1). These results suggest significant differences in collagen I expression in vaginal tissues (Table 1). The post hoc LSD analysis showed that high considerable difference between K0 and K1, K1 and K2, K2 and K3, K1 and K4, K0 and K3, also K0 and K4 ($p < 0.001$) (Table 2). The immunohistochemical features can be seen in Fig. 2.

3.2 Immunohistochemical Examination Results of Collagen III

The highest average expression of collagen III was observed in the control group of menopausal model rats without treatment (7.10 $\pm$ 1.46), menopausal model rats given quercetin 12.5 mg/kgBW (6.87 $\pm$ 2.71), menopausal

model rats given quercetin 50 mg/kgBW (4.37 ± 1.09), the menopausal model rat group given 17-β estradiol valerate Progynova 0.18 mg/kgBW (4.00 ± 0.83) and the lowest average in the control group of normal model rats without treatment (2.83 ± 0.43). Subsequent evaluation of the collagen III expression differences between groups was done using the One-Way ANOVA statistical test, yielding a p-value of less than 0.001 (Table 3). These findings point to notable variations in the expression of collagen III in vaginal tissues. A highly significant difference ($p < 0.001$) was found between K0 and K1, as well as K0 and K3, according to the post hoc LSD analysis (Table 4). Fig. 2 displays the immunohistochemical image.

3.3 Immunohistochemical Examination Results of Elastin

The highest average expression of elastin was observed in the control group of untreated normal rats (10.10 ± 1.65), followed by the menopausal model rats treated with 17-β estradiol valerate Progynova 0.18 mg/kgBW (8.10 ± 1.33), menopausal model rats treated with quercetin 50 mg/kgBW (6.30 ± 1.42), and menopausal model rats treated with quercetin 12.5 mg/kgBW (4.47 ± 1.80), while the lowest average was in the control group of untreated menopausal model rats (4.13 ± 1.23) (Table 5). The One-Way ANOVA statistical test was then used to analyze the differences in elastin expression between the groups, producing a p-value of less than 0.001 (Table 5). These results suggest significant differences in collagen elastin expression in vaginal tissues. The post hoc LSD analysis (Table 6) revealed a highly significant difference ($p < 0.001$) between K0 and K1, K1 and K2, K2 and K3, K1 and K4, K0 and K3, and K0 and K4. The immunohistochemical image is shown in Fig. 2.

Table 1. Statistical analysis of collagen I expression results.

Group	N	Mean ± SD	One-Way ANOVA test
K0	6	10.13 ± 1.32	
K1	6	3.90 ± 0.90	
K2	6	8.70 ± 0.68	$p < 0.001$***
K3	6	4.76 ± 1.28	
K4	6	6.97 ± 1.02	

SD, standard deviation; ANOVA, analysis of variance. ***$p < 0.001$.

Table 2. Results of post hoc LSD analysis of collagen I.

Group	p-value				
	K0	K1	K2	K3	K4
K0		<0.001***	0.029*	<0.001***	<0.001***
K1	<0.001***		<0.001***	0.172	<0.001***
K2	0.029*	<0.001***		<0.001***	0.010*
K3	<0.001***	0.172	<0.001***		0.001*
K4	<0.001***	<0.001***	0.010*	0.001*	

LSD, Least Significant Difference. *$p < 0.05$; ***$p < 0.001$.

Table 3. Statistical analysis of collagen III expression results.

Group	N	Mean ± SD	One-Way ANOVA test
K0	6	2.83 ± 0.43	
K1	6	7.10 ± 1.46	
K2	6	4.00 ± 0.83	$p < 0.001$***
K3	6	6.87 ± 2.71	
K4	6	4.37 ± 1.09	

SD, standard deviation. ***$p < 0.001$.

Table 4. Results of post hoc LSD analysis of collagen III.

Group	p-value				
	K0	K1	K2	K3	K4
K0		<0.001***	0.196	<0.001***	0.093
K1	<0.001***		0.002*	0.793	0.005*
K2	0.196	0.002*		0.003*	0.680
K3	<0.001***	0.793	0.003*		0.009*
K4	0.093	0.005*	0.680	0.009*	

*$p < 0.05$; ***$p < 0.001$.

Table 5. Statistical analysis of elastin expression results.

Group	N	Mean ± SD	One-Way ANOVA test
K0	6	10.10 ± 1.65	
K1	6	4.13 ± 1.23	
K2	6	8.10 ± 1.33	$p < 0.001$***
K3	6	4.47 ± 1.80	
K4	6	6.30 ± 1.42	

SD, standard deviation. ***$p < 0.001$.

4. Discussion

Vulvovaginal atrophy is a component of GSM, characterized by symptoms and signs resulting from decreased estrogen levels in various parts of the female genitalia and urinary system in menopausal women. The alterations result in troubling symptoms such as vaginal dryness, itching, painful sexual intercourse, more frequent urination, sudden need to urinate, and urine incontinence [12]. The menopausal genitourinary syndrome is associated with estrogen deficiency resulting in reduced elastin and collagen in the vaginal tissue, thinning of the vaginal epithelium, and increased vaginal pH [13]. It demonstrates how the structural integrity of vaginal tissues is significantly impacted by estrogen deficiency, which also contributes to the symptoms of GSM by reducing crucial extracellular matrix components. This research highlights the possible therapeutic use of substances like quercetin, which may improve vaginal tissue integrity and lessen symptoms of GSM by modifying the expression of collagen and elastin [14,15].

Collagen I levels are lower in menopausal models compared to non-menopausal models or those who have had therapy. These results show that treatment with quercetin 50 mg/kgBW provides a significant effect com-

IMR Press

Table 6. Results of post hoc LSD analysis of elastin.

Group	*p*-value				
	K0	K1	K2	K3	K4
K0		<0.001***	0.030*	<0.001***	<0.001***
K1	<0.001***		<0.001***	0.704	0.019*
K2	0.030*	<0.001***		<0.001***	0.048*
K3	<0.001***	0.704	<0.001***		0.045*
K4	<0.001***	0.019*	0.048*	0.045*	

*$p < 0.05$; ***$p < 0.001$.

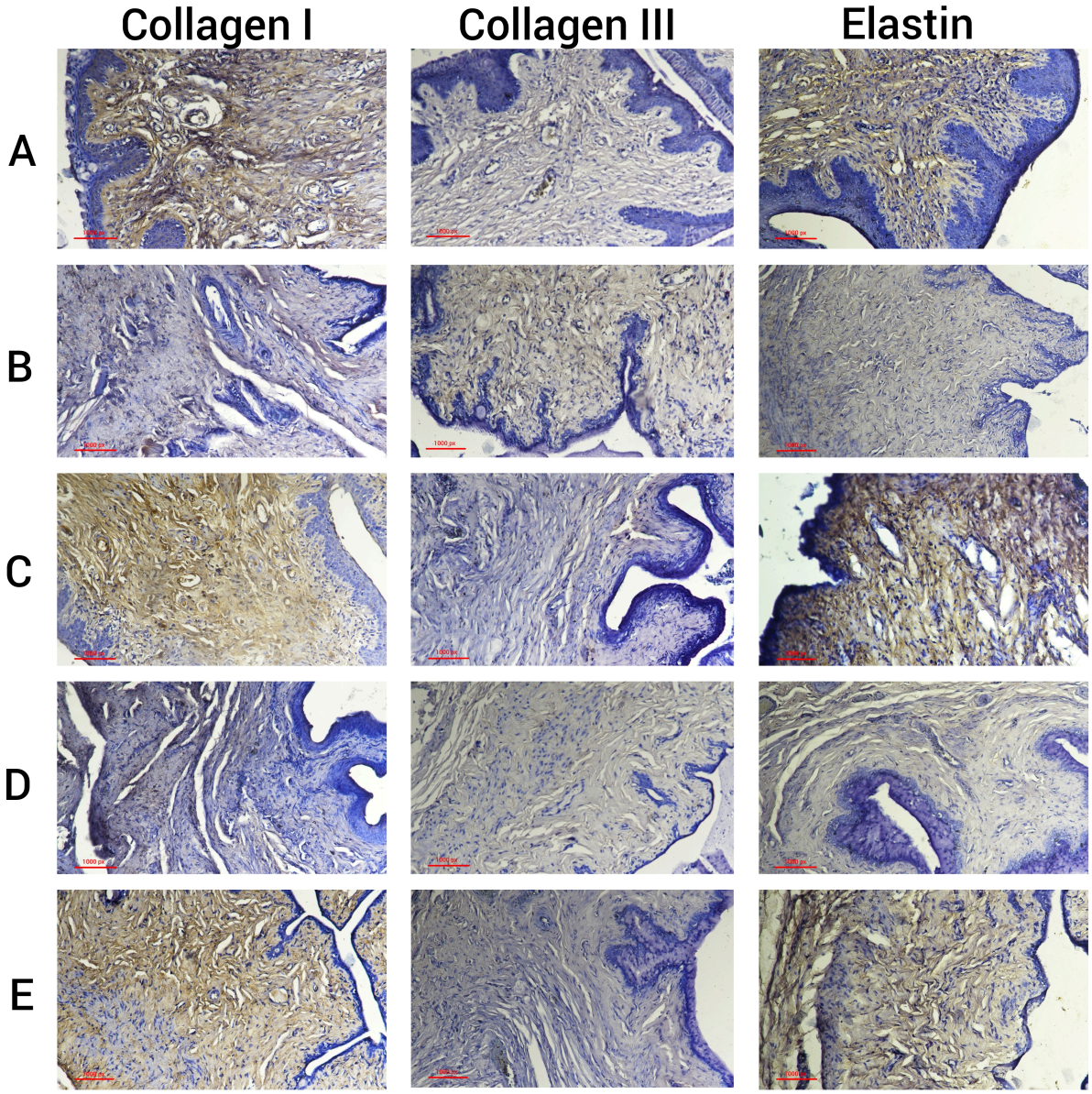

Fig. 2. Immunohistochemical image of collagen I, collagen III, and elastin vaginal tissue. (A) Regular rat model. (B) Menopausal rat model without treatment. (C) Menopausal rat model with 17-β estradiol valerate Progynova 0.18 mg/kgBW. (D) Menopausal rat model with 12.5 mg/kgBW of quercetin. (E) Menopausal rat model with 50 mg/kgBW of quercetin. Scale bar = 100 µm.

pared to the menopause model without treatment. However, it does not offer the same results as estrogen therapy. Postmenopausal women exhibit reduced levels of collagen I expression and thinner vaginal wall epithelium compared to premenopausal women. Menopause without hormone medication leads to a reduction in collagen I levels [16]. Estrogen significantly impacts the production of collagen in the pelvic region. Estrogen can stimulate the expression of type I collagen and destroy type III collagen in fibroblasts, resulting in greater muscle strength. In addition, estrogen can also improve total collagen cross-linking and replace old collagen with new tissue [17]. Differences in vaginal collagen I expression were observed among various treatment groups, including normal mice and menopausal model mice receiving different treatments, such as 17-β estradiol valerate Progynova and quercetin at varying doses [18]. Estradiol is crucial in controlling collagen metabolism. Estrogen enhances fibroblast proliferation and the expression of fibroblast-associated protein, extracellular matrix, and growth factors [16].

The largest average of collagen III expression was located in the control group of the menopause model without treatment, and the lowest average was in the control group of the standard model without treatment. The results of this study show that quercetin at a dose of 50 mg/kgBW provides the same effect as estrogen therapy in normal mice. Collagen III expression is influenced by therapy and the beginning of menopause. Post-menopause involves a gradual decrease in ovarian function, leading to particular alterations in organs and tissues, such as atrophy of the labia, vagina, and uterus [16]. Type III collagen and type I collagen are the main constituents of the interstitial matrix. Type III collagen mutations are associated with Ehlers-Danlos syndrome, vascular deficiencies, and aortic and arterial aneurysms [19]. Changes in collagen distribution during wound healing and extracellular matrix (ECM) remodeling during injury where the ratio of collagen I and collagen III is altered with a higher amount of collagen III during healing while increased collagen I in a healed wound [20].

The highest average level of elastin expression was observed in the control group of normal mice. The lowest average level was found in the control group of menopausal model mice without any treatment. These results show that therapy with quercetin 50 mg/kgBW provides a significant effect compared to the menopause model without treatment. However, it does not give the same results as estrogen therapy. The decrease in estrogen levels results in a reduction of vaginal epithelial permeability, perfusion, and elastin levels, resulting in vaginal dryness and atrophy. Therefore, it can be assumed that one of the causes of vaginal atrophy may be an estrogen deficiency resulting from the aging process, leading to a decrease in the expression of the Lysyl oxidase (LOX) family proteins and a reduction in the level of elastin in the vagina [21]. In postmenopausal women, the expression of elastin and the thickness of the vaginal wall epithelium are reduced compared to premenopausal women. Estrogen affects the elastin metabolism in relation to the matrix metalloproteinase (MMP) enzyme. It decreases the expression of MMP-2 and MMP-9, which degrade elastin [16].

Estrogen replacement therapy is recognized as the primary intervention for managing conditions arising from estrogen deficiency, particularly in postmenopausal women. However, owing to documented adverse effects associated with this approach, there is a notable inclination toward seeking a suitable alternative [22]. A common flavonoid found in fruits and vegetables, quercetin has been extensively studied for various health benefits, including its potential in wound healing and tissue regeneration. It is well-known for its potent anti-inflammatory and antioxidant qualities and estrogen-like effect *in vivo* and *in vitro* studies [15,23].

Our results are consistent with earlier research that demonstrated quercetin's capacity to regulate the expression of extracellular matrix components, thereby augmenting tissue regeneration and repair [15]. Particularly, quercetin's impact on collagen synthesis may enhance the elasticity and structural support of vaginal tissues, indicating a possible therapeutic use for disorders affecting the integrity and function of the vagina [14].

Numerous studies have been conducted on the health benefits of quercetin, which may include improving skin health by increasing the production of collagen and elastin. Recent research has highlighted several mechanisms through which quercetin achieves these effects. Quercetin is well-known for having strong antioxidant qualities. Free radicals are scavenged, and oxidative stress is decreased, which can harm skin proteins like collagen and elastin. Quercetin helps preserve the structural integrity of these proteins, which is necessary for the elasticity and firmness of skin, by reducing oxidative damage [15,24]. Moreover, it has been demonstrated that quercetin inhibits the activity of enzymes responsible for the breakdown of collagen and elastin. In particular, it lessens the activity of the enzymes known as MMPs, which break down the skin's collagen fibers. Quercetin preserves collagen levels by blocking MMPs, improving skin resilience, and lessening skin aging signs [15,25].

By altering the expression of genes linked to collagen synthesis, quercetin also encourages the synthesis of new collagen. Collagen type I and III expression are upregulated, essential for skin elasticity and strength. This effect is especially helpful in preventing the menopause-related loss of collagen, which results in skin that is thinner and less elastic [24,25]. Moreover, the anti-inflammatory characteristics of quercetin are essential for preserving skin health. The deterioration of collagen and elastin may be accelerated by persistent inflammation. Quercetin protects these proteins and facilitates their renewal and repair processes by lowering inflammation [15,26]. A review of the use of quercetin in osteoporosis has a similar effect of phytoestrogen on inhibiting bone resorption by participating

in the binding of estrogen receptors, especially in estrogen receptor-β (Erβ) mainly expressed in bone, also suggested that quercetin might affect bone metabolism through ERs independent pathway [23].

The limitation of this study is that it only takes three primary markers that occur in changes in the condition of vulvovaginal atrophy. Therefore, more research is needed, for example, by examining tissue inhibitor of metalloproteinase-1 (TIMP-1), antigen Kiel 67 (Ki-67), vascular endothelial growth factor (VEGF), aquaporin-2 (AQP-2), and MMP-1, so that this research can describe more complete changes in the condition of vulvovaginal atrophy.

5. Conclusions

In conclusion, quercetin is a promising option for enhancing skin health and reducing the effects of aging, particularly in menopausal women, because it increases the expression of collagen I, collagen III, and elastin through its antioxidant, enzyme-inhibiting, and anti-inflammatory qualities in the vagina of menopausal model especially by the administration of quercetin at a level of 50 mg/kgBW. Thus, quercetin can be an alternative herbal treatment option to improve vulvovaginal atrophy in menopausal conditions. For further research, studies can be conducted with markers related to vulvovaginal atrophy or pelvic organ prolapse with quercetin as one of the therapy options.

Availability of Data and Materials

The datasets used and/or analyzed during the current study are available from the corresponding author upon reasonable request.

Author Contributions

THSH, GH, EMK, ISY, HP, BU, and BIS were involved in conceptualizing and designing the research study. THSH was responsible for database management. THSH and BU conducted the statistical analysis. THSH drafted the initial manuscript. All authors contributed to editorial changes in the manuscript. All authors read and approved the final version of the manuscript. Additionally, all authors participated significantly in the research and agreed to take responsibility for all aspects of the work.

Ethics Approval and Consent to Participate

This research has been tested for ethical feasibility at the Faculty of Medicine, Airlangga University, to meet the ethical requirements for experimental animals. It has received approval from the research ethics committee with number 215/EC/KEPK/FKUA/2022. The research data and results are only used for knowledge purposes.

Acknowledgment

We are deeply grateful to everyone who assisted us throughout the composition of this manuscript. Furthermore, we extend our heartfelt thanks to the reviewers for their dedicated time and effort in meticulously reviewing the manuscript and offering invaluable insights to enhance its quality.

Funding

This research was funded by Universitas Airlangga Research and Community Service Institute (No. 66/UN3.15/PT/2022).

Conflict of Interest

The authors declare no conflict of interest.

References

[1] Alvisi S, Gava G, Orsili I, Giacomelli G, Baldassarre M, Seracchioli R, *et al*. Vaginal Health in Menopausal Women. Medicina (Kaunas, Lithuania). 2019; 55: 615.

[2] Angelou K, Grigoriadis T, Diakosavvas M, Zacharakis D, Athanasiou S. The Genitourinary Syndrome of Menopause: An Overview of the Recent Data. Cureus. 2020; 12: e7586.

[3] Mao M, Li Y, Zhang Y, Kang J, Zhu L. Tissue Composition and Biomechanical Property Changes in the Vaginal Wall of Ovariectomized Young Rats. BioMed Research International. 2019; 2019: 8921284.

[4] Baud S, Duca L, Bochicchio B, Brassart B, Belloy N, Pepe A, *et al*. Elastin peptides in aging and pathological conditions. Biomolecular Concepts. 2013; 4: 65–76.

[5] Panche AN, Diwan AD, Chandra SR. Flavonoids: an overview. Journal of Nutritional Science. 2016; 5: e47.

[6] Vrachnis N, Zygouris D, Vrachnis D, Antonakopoulos N, Fotiou A, Panagopoulos P, *et al*. Effects of Hormone Therapy and Flavonoids Capable on Reversal of Menopausal Immune Senescence. Nutrients. 2021; 13: 2363.

[7] Wang Z, Zhang G, Le Y, Ju J, Zhang P, Wan D, *et al*. Quercetin promotes human epidermal stem cell proliferation through the estrogen receptor/β-catenin/c-Myc/cyclin A2 signaling pathway. Acta Biochimica et Biophysica Sinica. 2020; 52: 1102–1110.

[8] Lasota A, Danowska-Klonowska D. Experimental osteoporosis–different methods of ovariectomy in female white rats. Roczniki Akademii Medycznej W Bialymstoku (1995). 2004; 49: 129–131.

[9] Khajuria DK, Razdan R, Mahapatra DR. Description of a new method of ovariectomy in female rats. Revista Brasileira De Reumatologia. 2012; 52: 462–470.

[10] American Veterinary Medical Association. AVMA Guidelines for the Euthanasia of Animals: 2020 Edition. American Veterinary Medical Association: Schaumburg, IL. 2020.

[11] Wardhani PH, Prakoeswa CRS, Listiawan MY, Astari L, Zulkarnain I, Murtiastutik D, *et al*. Melanocyte count on leukotrichia in vitiligo using S100 protein immunohistochemistry before and after phototherapy: A case report. Journal of Pakistan Association of Dermatologists. 2020; 30: 355–358.

[12] Mercier J, Dumoulin C, Carrier-Noreau G. Pelvic floor muscle rehabilitation for genitourinary syndrome of menopause: why, how and when? Climacteric: the Journal of the International Menopause Society. 2023; 26: 302–308.

[13] Jang YC, Leung CY, Huang HL. Comparison of Severity of Genitourinary Syndrome of Menopause Symptoms After Carbon Dioxide Laser vs Vaginal Estrogen Therapy: A Systematic Review and Meta-analysis. JAMA Network Open. 2022; 5: e2232563.

[14] Chen H, Xue L, Gong G, Pan J, Wang X, Zhang Y, *et al*. Collagen-based materials in reproductive medicine and engi-

neered reproductive tissues. Journal of Leather Science and Engineering. 2022; 4: 3.
[15] Aghababaei F, Hadidi M. Recent Advances in Potential Health Benefits of Quercetin. Pharmaceuticals (Basel, Switzerland). 2023; 16: 1020.
[16] Adnyana IGHE, Suwiyoga K, Megadhana W. Ekspresi kolagen I, elastin, dan ketebalan epitel dinding vagina paskamenopause lebih rendah dibandingkan premenopause. Medicina (B Aires). 2018; 49: 241–245. (In Indonesia)
[17] Zhou L, Shangguan AJ, Kujawa SA, Bochenska K, Zhang L, Bulun SE, *et al*. Estrogen and Pelvic Organ Prolapse. Journal of Molecular and Genetic Medicine. 2016; 10: 221.
[18] McCracken JM, Calderon GA, Le QN, Faruqui NM, Balaji S, Hakim JCE. Cellular and extracellular vaginal changes following murine ovarian removal. Physiological Reports. 2023; 11: e15762.
[19] Karsdal MA. Biochemistry of Collagens, Laminins and Elastin. Elsevier: Amsterdam, The Netherlands. 2016.
[20] Singh D, Rai V, Agrawal DK. Regulation of Collagen I and Collagen III in Tissue Injury and Regeneration. Cardiology and Cardiovascular Medicine. 2023; 7: 5–16.
[21] Szymański JK, Słabuszewska-Jóźwiak A, Jakiel G. Vaginal Aging-What We Know and What We Do Not Know. International Journal of Environmental Research and Public Health. 2021; 18: 4935.
[22] Jafari Khorchani M, Samare-Najaf M, Abbasi A, Vakili S, Zal F. Effects of quercetin, vitamin E, and estrogen on Metabolic-Related factors in uterus and serum of ovariectomized rat models. Gynecological Endocrinology: the Official Journal of the International Society of Gynecological Endocrinology. 2021; 37: 764–768.
[23] Huang YY, Wang ZH, Deng LH, Wang H, Zheng Q. Oral Administration of Quercetin or Its Derivatives Inhibit Bone Loss in Animal Model of Osteoporosis. Oxidative Medicine and Cellular Longevity. 2020; 2020: 6080597.
[24] Sobhy R, Khalifa I, Rahaman A, Zeng XA, Nawaz A, Walayat N. Quercetin: The Biological Effects, Chemical Steadiness, Metabolism, and Delivery Systems. In Xiao J (ed.) Handbook of Dietary Flavonoids (pp. 1–33). Springer International Publishing: Berlin, Germany. 2023.
[25] Aziz J, Shezali H, Radzi Z, Yahya NA, Abu Kassim NH, Czernuszka J, *et al*. Molecular Mechanisms of Stress-Responsive Changes in Collagen and Elastin Networks in Skin. Skin Pharmacology and Physiology. 2016; 29: 190–203.
[26] Baumann L, Bernstein EF, Weiss AS, Bates D, Humphrey S, Silberberg M, *et al*. Clinical Relevance of Elastin in the Structure and Function of Skin. Aesthetic Surgery Journal. Open Forum. 2021; 3: ojab019.