

Evaluation of the chest X-ray: a pictorial review

This article aims to provide the reader with a step-by-step guide to the accurate interpretation of the chest radiograph. It begins by discussing the importance of patient and radiographical features, and then describes the main anatomical structures that can be seen on the chest radiograph.

The chest radiograph (CXR) is one of the most common X-ray examinations performed, but is also one of the most difficult to interpret. Ideally, each CXR should be reported by a radiologist, but its initial interpretation is often left to the clinicians and junior doctors who requested the examination.

Accurate evaluation of the CXR is an invaluable skill for the clinician, since it may be instrumental in tailoring the immediate treatment delivered to the patient.

This article presents a comprehensive method for reading a CXR with special attention paid to examination of the normal anatomical structures and technical factors.

Patient details

The first step in evaluation of the CXR is to check the details printed on the film, including the patient's name, the date of the examination and the position of the side markers (*Figure 1*). This routine will avoid making decisions based on old CXRs or even on the radiograph of a different patient.

Technical quality of CXR

Technical factors which have to be considered to avoid a misinterpretation of a CXR are:

Projection

The projection (AP – anteroposterior or PA – postero-anterior) is defined by the direction of the X-ray beam through the patient. The standard projection is PA whereby the X-ray tube is posterior to the patient and the film cassette is positioned anteriorly. The mediastinal structures are anteriorly positioned within the chest, and thus a PA projection will cause minimal magnification. An AP film by comparison will cause magnification and the mediastinal structures are therefore difficult to assess (*Figure 2*). However, AP films may be taken with the patient sitting or supine, and so this projection is used if

the patient is immobile or seriously ill (*Figure 3*). The projection should be marked on the film (Meholic et al, 1996).

A portable CXR is often requested for critically ill patients. It is a good examination to identify obvious pathology within the chest and position of drains and lines. However, it has a significant limitations in assessing the details of lung parenchyma, especially in the thickest part of the chest, because of the lower energy of X-rays used.

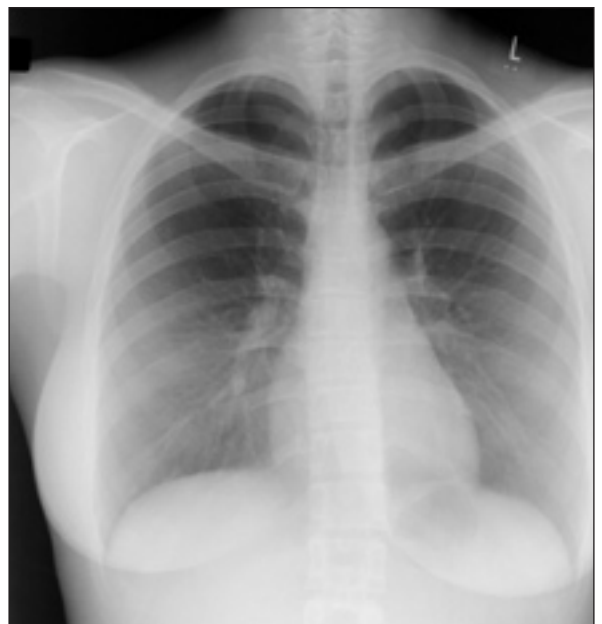Rotation

The medial ends of the clavicles should be an equal distance from the spinous processes of thoracic vertebrae. Rotation of the patient may distort the mediastinal contour and the lung on the side to which the patient is rotated may appear hypertransradiant (lighter) (*Figure 4*).

Penetration

Penetration is best evaluated by assessing if the vertebral bodies and intervertebral discs are just visible behind the cardiac silhouette (Armstrong and Wastie,

Figure 1. Normal chest radiograph.



Dr Joanna Kasznia-Brown is Specialist Registrar in the Department of Radiology, Bristol Royal Infirmary, Bristol and **Dr Chris Cook** is Consultant Radiologist in the Department of Radiology, Weston General Hospital, Uphill, Weston-Super-Mare BS23 4TQ

Correspondence to: Dr C Cook

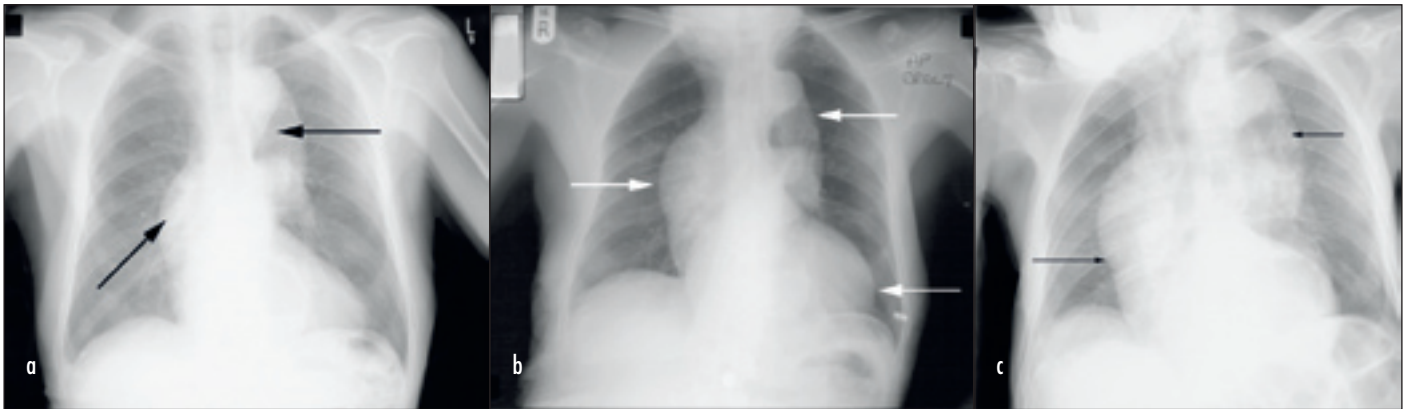
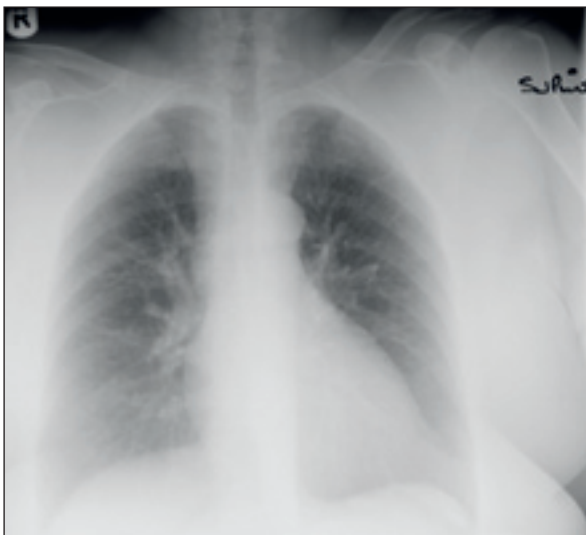

Figure 2. Posteroanterior (PA), anteroposterior (AP) and supine chest X-ray of the same patient showing the effect of the patient's position on the appearance of the mediastinal structures. *a.* The PA projection demonstrates normal size heart and slight widening of the mediastinum because of the unfolding aorta. *b.* The AP projection shows increase in size of the heart and width of mediastinum. *c.* AP supine film demonstrates severe widening of the mediastinum, simulating soft tissue mass.

1987). If they are too clearly visible, then the film is over-penetrated and subtle low density lesions within

Figure 3. The anteroposterior supine chest X-ray shows increased prominence in the hilar vasculature and the dilatation of the vessels in the upper lobes. These changes are caused by the supine position of the patient, not cardiac failure.



lung parenchyma may not be seen. If the vertebral bodies are not visible, then the film is under-penetrated and the lung fields will appear falsely white (Figure 5).

Figure 4. Portable chest X-ray shows wide mediastinum and a difference in the lucency between two lung fields as a result of severe patient rotation.

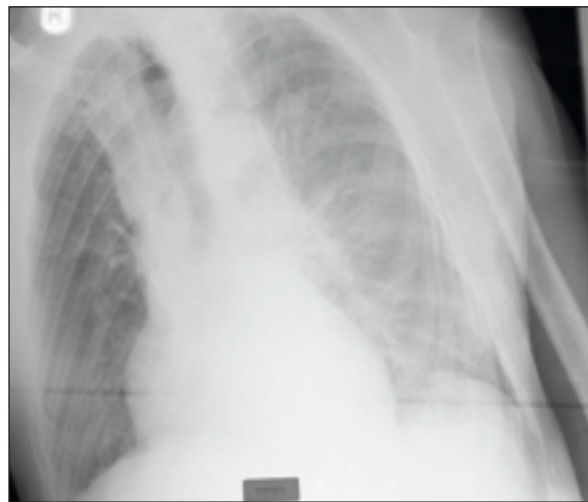
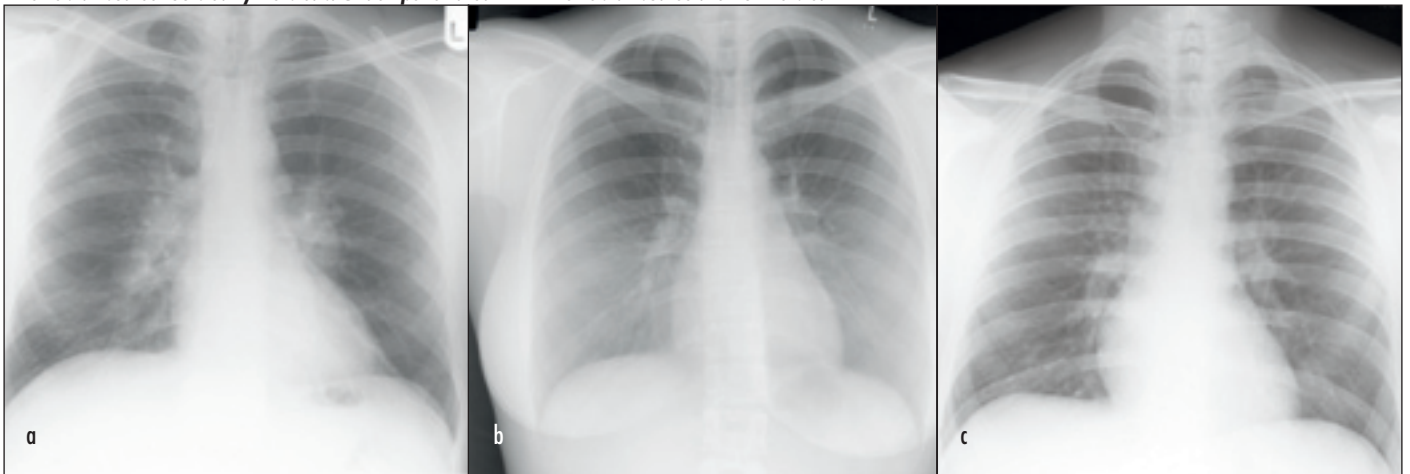


Figure 5. Posteroanterior chest X-rays showing different penetration of X-rays. *a.* Vertebral bodies just visible through the cardiac shadow. *b.* Over-penetrated film – vertebral bodies too clearly visible. *c.* Under-penetrated film – vertebral bodies are not visible.



Patient factors

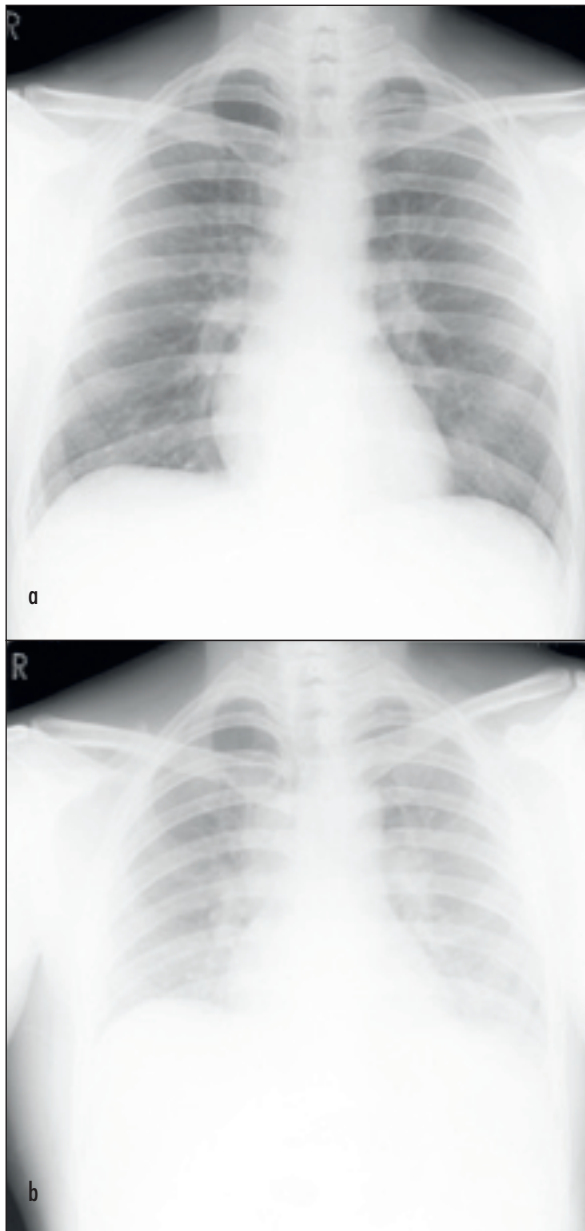
Degree of inspiration

The CXR should ideally be exposed in full inspiration with the patient in the upright position. Films taken on expiration are difficult to interpret because the lung bases appear hazy and the heart shadow appears relatively increased in size (*Figure 6*).

A normal inspiratory X-ray in adults should reveal at least nine, and preferably ten posterior ribs above the diaphragm, or between five and seven ribs anteriorly.

Inadequate depth of inspiration can cause an elevation of the diaphragm, crowding of vascular markings and obscuring up to one third of the lower lobes of both

Figure 6. X-rays of the same patient taken only few minutes apart. a. Normal appearance. b. Haziness of lung fields in the lower zones bilaterally, indistinguishable left hemidiaphragm and prominence of hilar vasculature. Changes are secondary to poor inspiration.



lungs. These appearances may closely mimic the radiographical features of congestive heart failure or basal pneumonia (Sutton, 1987).

Evaluation of a normal chest radiograph

In everyday practice, a standardized routine for CXR evaluation is necessary. An exact method of evaluation is up to individual discretion, but all structures must be seen and evaluated, otherwise important abnormalities may be overlooked.

A routine beginning with the cardiac silhouette is described below.

Heart and mediastinum

Heart

The overall heart size is easily assessed on a plain CXR (*Figure 7*). The cardiothoracic ratio (CTR) is widely used, but it is not actually a very accurate method of measurement. In a normal person the transverse diameter of the heart is usually less than half the internal diameter of the chest. Comparing the CXR with previous films is probably more useful in assessing the heart size than the CTR in isolation.

The position of the heart is very variable; on average one third lies to the right of the midline, but anything from one half to one fifth of the heart lying to the right of the midline is within the normal range.

The left and right heart borders should be clearly defined.

The right border comprises the superior vena cava, right atrium and sometimes a short segment of inferior vena cava. In older patients, the ascending aorta may form part of the upper right cardiovascular silhouette. The left border comprises the aortic knuckle, pulmonary trunk, left atrial appendage and left ventricle (Grainger and Allison, 2001).

Figure 7. Posteroanterior chest X-ray demonstrates cardiomegaly. Incidental note is made of a missing breast shadow on the right side (large arrow) and hiatus hernia projected behind the heart (small arrow).

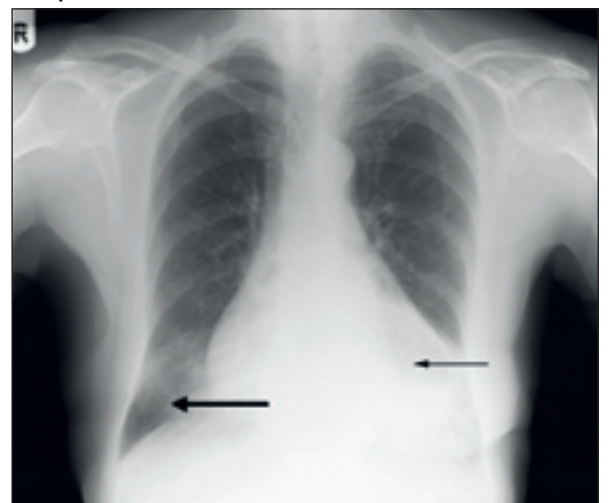

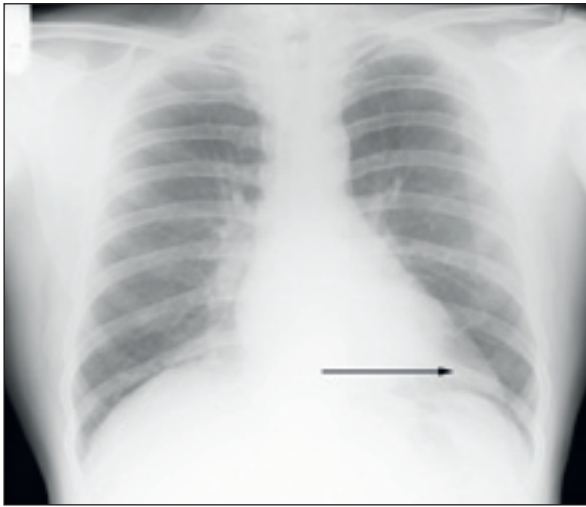


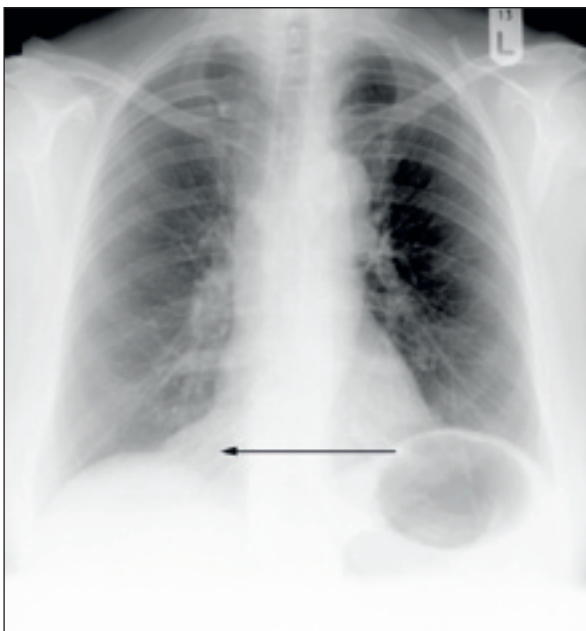
Figure 8. Chest X-ray shows epicardial fat pad at the left cardiophrenic angle, which simulates cardiac enlargement. Heart size is normal.

There is often fat surrounding the heart in the form of epicardial fat pads. These are usually localized to the cardiophrenic angles and may simulate cardiac enlargement or adjacent mass (*Figures 8 and 9*).

Mediastinum

The right superior mediastinal border is usually straight or slightly curved as it passes downward to merge with the right heart border (*Figures 1 and 10*). The left superior mediastinal border is ill defined above the aortic arch. The aortic arch is usually left-sided and it lies over the left main bronchus and indents the left side of the trachea. The rare anatomical variant of a right aortic arch may simulate a right para-tracheal mass.

Figure 9. Chest X-ray shows epicardial fat pad at the right cardiophrenic angle, which simulates cardiac enlargement. Heart size is normal.



In infants and young children, the thymus occupies a large part of the anterior mediastinum and may obscure parts of the upper cardiac silhouette (Chapman and Nakielny, 2003).

Trachea

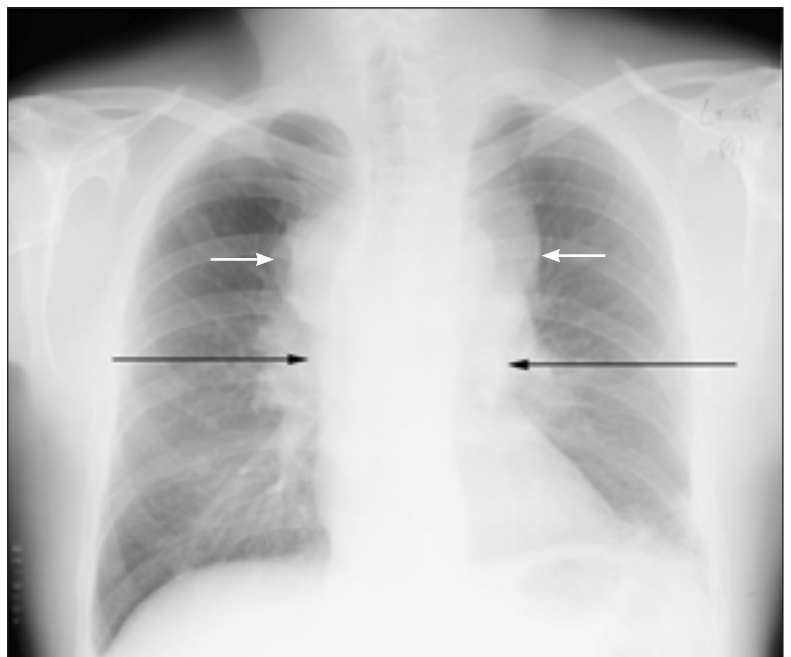
The trachea lies in the mid-line proximally, but distally it is deviated to the right by the aortic arch (*Figure 1*). The lumen appears as a translucent band and in adults it is normally 1.2–2 cm wide. The right para-tracheal stripe is a band of tissues outlined by the air in the tracheal lumen and right lung and is normally less than 5 mm wide.

The subcarinal angle, created by the main bronchi, is normally 60–70°. This angle may be increased by left atrial enlargement (such as occurs in mitral valve disease) or subcarinal lymphadenopathy (Dahnert, 2003).

Hila

On the CXR, the normal hilar shadows are formed by the pulmonary arteries and upper lobe veins. Normal lymph nodes are not visible. The left hilum is 0.5–1.5 cm higher than the right. Both hila should be of similar radiodensity. Hilar enlargement may be a result of enlargement of the hilar vessels or lymph nodes, or to a mass (*Figures 1 and 5a*). Vascular enlargement tends to produce a smooth convex outline, but masses and lymphadenopathy can often appear lobulated too, and ultimately a computed tomography scan may be needed to differentiate these (Chapman and Nakielny, 2003).

Figure 10. Chest X-ray demonstrates widening of the mediastinum (white arrows) and enlargement of hila (black arrows) as a result of lymphadenopathy in a patient with lymphoma.



Lungs

The only structures that can be identified within normal lungs are the blood vessels, the interlobar fissures and the walls of the larger bronchi seen end-on. The fissures can only be seen if they lie tangential to the X-ray beam. The horizontal fissure separates the right upper and the right middle lobe and it is visible in 50–60% of patients. It runs from the right hilum to the sixth rib in the mid-axillary line. There is no equivalent of the horizontal fissure on the left. An upward or downward inclination of 10° is seen occasionally, but anything more is considered abnormal.

There are certain areas where the abnormalities can be easily overlooked – the apices, the retrosternal space, the retrocardiac area, the perihilar regions and the posterior costophrenic recesses. These ‘blind’ areas of the lungs on the normal CXR make up to 40% of the lung area and 25% of lung volume. Masses as large as 2 cm can be easily missed in these areas (Grainger and Allison, 2001).

The density of the lung is normally the same on both sides, if the patient is standing straight, and the overlying soft tissues are symmetrical. Even slight rotation may cause one lung to be more transradiant than the other (Figure 4). A good method of analysis is to compare one lung with the other, zone by zone.

The vessels in the upper half of the lung are smaller than those in the lower half, but they are symmetrical in size and number at equivalent levels of both lungs. They run downward either in a straight line or with a slight

lateral convexity in the lower zone. Disturbance of the pulmonary vascular pattern may be caused by pulmonary or cardiovascular disease.

Diaphragm and pleura

The upper surfaces of the diaphragm should be clearly visible from one costophrenic angle to the other, except where the heart is in contact with the diaphragm. Large breast shadows, or other fat deposition can cause a generalized haziness in the lower zones but the diaphragm–lung interface should remain clear (Figure 1 and 11).

The mid-point of the right hemidiaphragm should lie between the anterior ends of the fifth and seventh ribs.

The right hemidiaphragm is usually 1–2 cm higher than the left, excluding persons with a large amount of gas in the stomach or colon, which will cause elevation of the left dome. The curve of the diaphragm may be assessed by measuring the distance between the highest point of the diaphragm and a line joining the costophrenic and cardiophrenic angles. When this distance is less than 1 cm, the diaphragm is said to be flattened (Figure 12).

The pleura should not be visible, but the lung edges should be reviewed for evidence of abnormal pleural thickening, calcification or pneumothorax (Chapman and Nakielny, 2003).

Review areas

Systemic evaluation of the CXR must include ‘review areas’, which represent the structures not completely seen or CXR. Pathology in these areas may be easily overlooked on initial evaluation of the CXR.

Figure 11. Erect chest X-ray: patient post-mastectomy – absence of right breast shadow. Right hemidiaphragm is more clearly visible than the left.

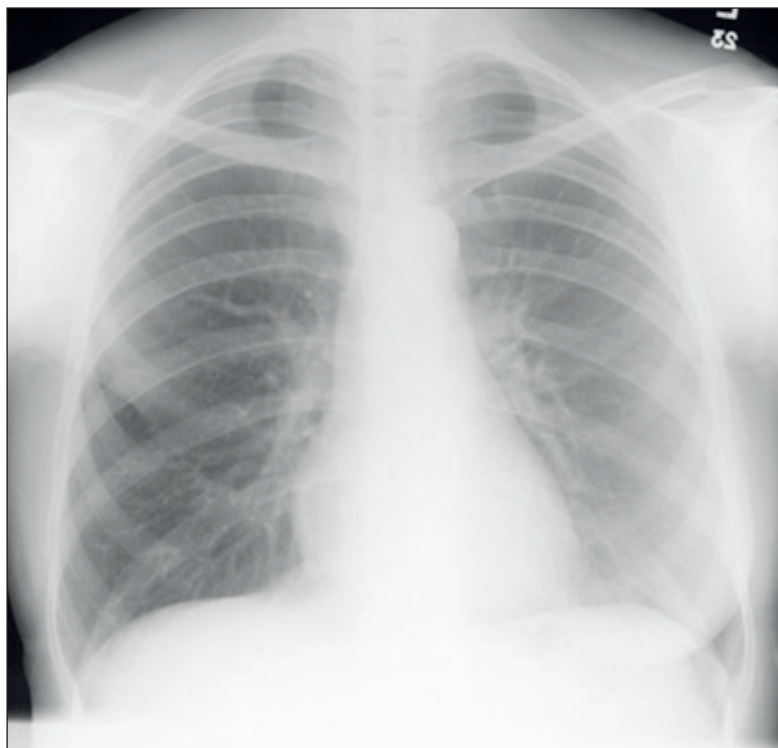
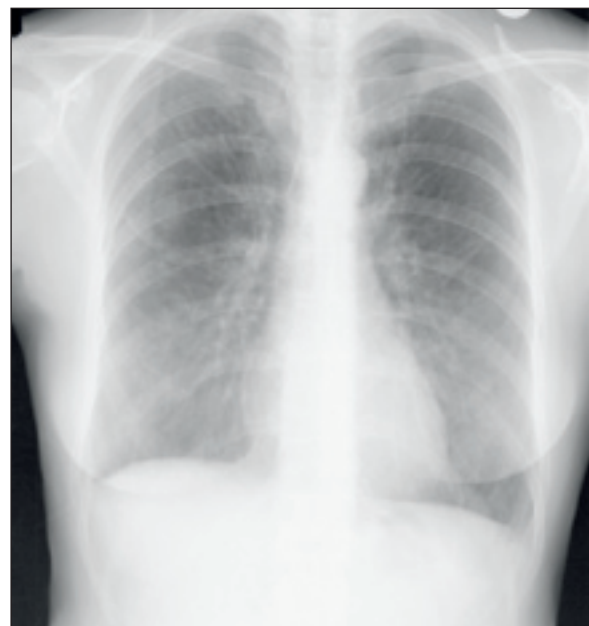

Figure 12. Posteroanterior chest X-ray of patient with chronic obstructive pulmonary disease demonstrates hyperinflation of both lungs and flattening of the diaphragm.



Hidden areas of lung

The review areas should also include the lung apices, lung projected beneath the domes of diaphragm and behind the heart. Small or subtle lesions in these areas may be obscured by multiple overlying structures, e.g. the first rib, clavicle, or obscured by the heart itself (Corne et al, 2002).

Bones and soft tissue

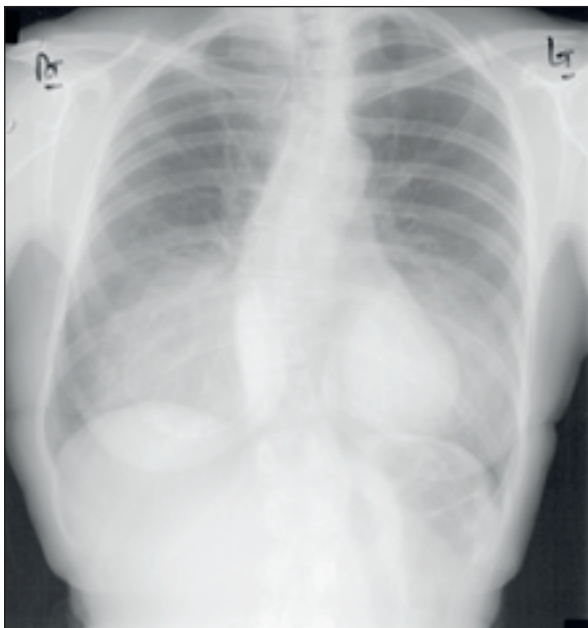A general survey should be made of all bones (ribs, spine, clavicles, sternum, scapulae) demonstrated on the chest film. A survey should also include the soft tissue of the chest wall, shoulders and lower neck. The breast shadows should be reviewed for evidence of breast surgery, and since large breasts may change the density of the lung bases and obscure subtle lesions (Figures 7, 11 and 13).

The pectoral muscles, breasts, plaits of hair, skin lumps or the nipples may mimic pulmonary nodules (Meholic et al, 1996).

Upper abdomen

A pneumoperitoneum is better seen on the erect chest film than on an abdominal X-ray (Figure 14). A full explanation of the radiological signs of pneumoperitoneum is given in the article on p. 634 of this issue. A search should be made for other abnormal gas shadows,

Figure 13. Chest X-ray of the patient after breast surgery. Bilateral soft tissue shadows in the lower zones represent breast implants.



such as the dilated loops of bowel, abscesses, displaced gastric bubble and intramural gas. Calcified hepatic tumours, granulomas and gallstones may occasionally be seen (Corne et al, 2002).

Conclusions

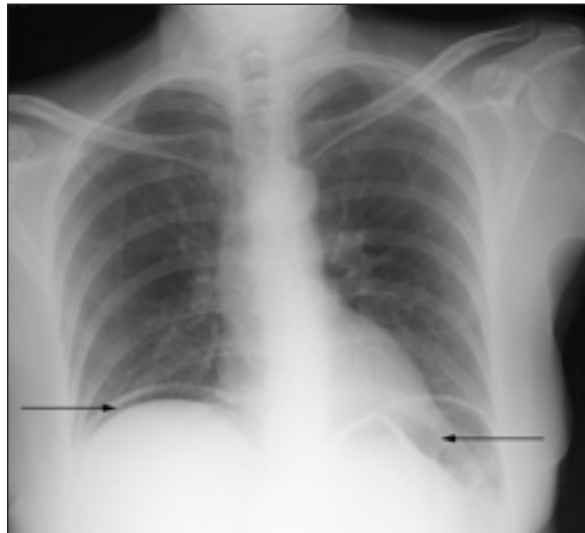
Accurate evaluation of the CXR is aided by a step-by-step analysis. This article describes the importance of patient details and radiographical features before describing a suitable sequence for anatomical evaluation. It includes a description of the 'review areas' which are important to include in CXR analysis if subtle pathologies are not to be missed by the less experienced observer. **BJHM**

The authors would like to thank Dr G Stoddart for supplying Figures 2, 6, 8 and 9.

Conflict of interest: none.

Armstrong P, Wastie M, eds (1987) *Diagnostic Imaging*. 2nd edn. Blackwell Scientific Publications, Oxford
 Chapman S, Nakielny R, eds (2003) *Aids to Radiological Differential Diagnosis*. 4th edn. Saunders, Edinburgh
 Corne J, Carroll M, Brown I, Delany D (2002) *Chest X-ray Made Easy*. 2nd edn. Churchill Livingstone, Edinburgh
 Dahnert W (2003) *Radiology Review Manual*. 5th edn. Lippincott, Williams & Wilkins, Baltimore, Maryland
 Grainger R, Allison D, eds (2001) *Diagnostic Radiology. A Textbook of Medical Imaging*. 4th edn. Churchill Livingstone, London
 Meholic A, Ketai L, Lofgren R (1996) *Fundamentals of Chest Radiology*. 1st edn. Saunders, London
 Sutton D, ed. (1987) *A Textbook of Radiology and Imaging*. 4th edn. Churchill Livingstone, New York

Figure 14. Erect chest X-ray shows free air under the diaphragm, representing pneumoperitoneum as a result of perforation.



KEY POINTS

- Remember to look at the patient's details and the date of examination before proceeding.
- Evaluate the projection of the film and look at other patient factors.
- Follow a routine for the actual chest X-ray analysis such as the one given here.
- Look carefully at the so-called 'review' areas where pathology is often missed.