

Morton's neuroma

Morton's neuroma is a common cause of metatarsalgia. This review highlights the importance of the history and examination in making the diagnosis and discusses the options for management.

Morton's neuroma, a painful enlargement of the interdigital nerves between the metatarsal heads, was originally recognized by Durlacher in 1845. Morton in 1876 thought the cause to be secondary to metatarsophalangeal (MTP) joint pathology and recommended removal of the metatarsal head (Smith and Jones, 1999). Despite this, Morton's name has become associated with the condition which may also be referred to as Morton's metatarsalgia, Morton's syndrome, or interdigital neuroma. This review focuses on how the condition is diagnosed, distinguishing it from other causes of forefoot pain or metatarsalgia, such as disorders of the MTP joints. Options for management and the outcome after surgery are discussed.

The cause of Morton's neuroma remains uncertain; it is probably a form of entrapment neuropathy and may be related to overuse of inappropriate footwear, but the condition does not appear to be any more common in individuals who undertake sporting activities that involve high stresses on the forefoot (Mann, 1999). Most published series report a female preponderance; of the author's patients the female to male ratio is 7:1. The majority are aged between 30 and 60 years; the youngest is 17 years old and the oldest is 75 years old.

What is Morton's neuroma?

Aetiology

The cause of Morton's neuroma is uncertain. It is generally considered to be a form of nerve entrapment. The common digital nerves lie adjacent to the transverse intermetatarsal ligaments between the plantar plates of the MTP joints. There has been much speculation as to the relevance of the widths of interspaces and relative mobility of metatarsals causing irritation or compression of the nerve. The common digital nerve in the third to fourth interspace, primarily arising from the lateral plantar nerve, usually has a communicating branch from the medial plantar nerve, and it has been suggested that this may increase its vulnerability by being thicker or more tethered (Levitsky et al, 1993), but this does not account for the occurrence of lesions in the second to third interspace. Tight-fitting footwear commonly aggravates symptoms from Morton's neuroma, but there is no evidence to show that this causes the condition. The incidence is not increased among athletes or people who spend prolonged periods on their feet at work (Mann, 1999).

Mr Peter J Briggs is Consultant Orthopaedic Surgeon in the Department of Orthopaedics, Freeman Hospital, Newcastle upon Tyne NE7 7DN

Pathology

At surgery there is a macroscopic swelling of the nerve in the region of its bifurcation into digital branches. Histology shows fibrosis of the endoneurium and perineurium, Schwann cell and fibroblast proliferation, and demyelination with loss of nerve fibres (Bullough, 1997). Thickening and hyalinization of walls of the interdigital arteries may be seen, but whether this is part of the same pathological process is uncertain. These features are suggestive of an entrapment neuropathy associated with the deep transverse intermetatarsal ligament.

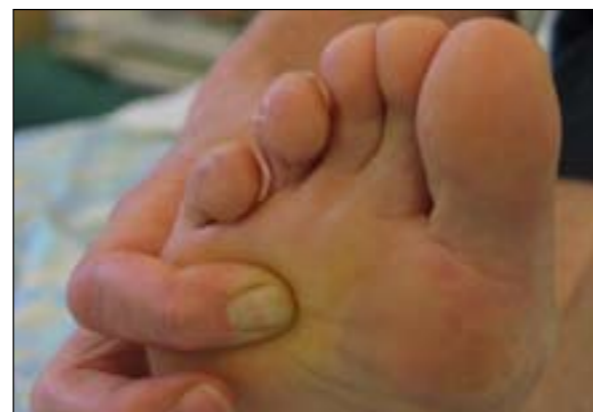How is Morton's neuroma diagnosed?

Symptoms

The classical features of Morton's neuroma are a localized burning pain felt between the third and fourth metatarsal heads on standing and walking, which may radiate into the toes, and is often relieved by removing the shoes. Patients can often point directly to the site of the pain between the metatarsal heads (Figure 1). In 30–50% of patients the pain will be between the second and third metatarsal heads, and rarely in the other interspaces. It can be a severe pain, stopping patients in their tracks and often relieved by removal of footwear. The onset of symptoms is usually gradual, without any obvious precipitating event, with episodes steadily getting more severe over several months. Certain types of footwear, such as tight slip-on shoes or high-heeled shoes, aggravate symptoms. Some patients feel numbness or paraesthesiae in the toes distal to the affected interspace, but this is not a reliable feature.

Patients with long-standing symptoms may develop a more generalized pain in the forefoot making diagnosis more uncertain. Pain arising from the MTP joints as a result of synovitis, joint instability or deformity of the

Figure 1. Patient indicating the site of pain between the third and fourth metatarsal heads.



toes or metatarsals should be considered. Radiation of the pain proximal to the forefoot is unusual and should raise suspicion of a more proximal condition, e.g. tarsal tunnel syndrome or even a prolapsed lumbar intervertebral disc.

Examination

To inspection the feet may be unremarkable. Deformity of the toes, e.g. clawing, points to the possibility of an articular cause for the symptoms. Deviation of the toes at the relevant interspace has been suggested as a sign of the presence of a Morton's neuroma, but in the author's experience this is very uncommon and probably reflects some underlying problem at the MTP joints causing secondary interdigital nerve entrapment. Reduction of the longitudinal arch of the foot with excessive pronation of the heel may alter forefoot mechanics such that there is increased compression of the interdigital nerves.

Walking barefoot on a hard surface is more uncomfortable and asking the patient to stand on tip-toe will aggravate pain from a variety of forefoot pathologies. Plantar tenderness maximal between the respective metatarsal heads is the most reliable physical finding to differentiate Morton's neuroma from other painful conditions of the forefoot. Squeezing the MTP joints and interspaces in turn and asking the patient which is most painful helps to differentiate between articular pain and Morton's neuroma. Palpating with the finger and thumb at the relevant interspace while compressing the metatarsal heads together with the other hand may elicit a palpable clicking sensation which, if it reproduces the symptoms (Mulder's sign; Mulder, 1951), is diagnostic of a Morton's neuroma.

Differential diagnosis

Synovial cysts or bursae in the metatarsal interspace may cause interdigital nerve compression, and rarely other soft tissue tumours such as a ganglion or lipoma.

The main disorders that need to be differentiated from Morton's neuroma relate to the MTP joints. Synovitis from joint instability, Freiberg's disease or inflammatory arthropathy may give rise to localized forefoot pain. Patients can often determine which toe is affected. Pain often gradually gets worse with walking, is not usually of a burning quality, and is aggravated by toe movement. Swelling, unusual in Morton's neuroma, may be evident. Toe deformities such as hammer toes or claw toes may lead to pressure problems under the metatarsal heads or the tops of the toes associated with callosities. Tenderness will be maximal over the joints rather than the interspaces. A metatarsal stress fracture is usually associated with a rapid onset of symptoms, with tenderness along the metatarsal shaft. Rupture of the MTP joint plantar plate may also be associated with sudden onset of pain, often with some swelling or bruising, tenderness maximal on the plantar aspect of the metatarsal head, and followed by gradual development of a claw toe.

Radiation of pain, numbness or paraesthesiae proximal to the forefoot is uncommon in Morton's neuroma and should raise the suspicion of a more proximal pathology

such as tarsal tunnel syndrome, peripheral neuropathy, or even nerve root compression in the spine. Rarely other nerve lesions may be found. A more detailed neurological assessment, including palpation of the tibial nerve behind the ankle, percussion along the course of lower limb nerves, and sciatic nerve root tension signs should be undertaken.

Can the diagnosis be confirmed by investigation?

The diagnosis of Morton's neuroma is not always certain. Repeated evaluation of the patient's symptoms and signs on different occasions is often helpful in clarifying the situation. Weight-bearing radiographs may be helpful in excluding MTP joint pathologies, e.g. inflammatory arthropathy or osteoarthritis, and assessing any underlying deformities of the foot. Electromyography and nerve conduction studies are of no value in establishing the diagnosis of Morton's neuroma, but may be of use in assessing more proximal pathologies.

Ultrasound and magnetic resonance (MR) imaging have been used in the investigation of Morton's neuroma (Betts et al, 2003; George et al, 2005). Both are equally effective in demonstrating the enlargement of the nerve (Figures 2 and 3). However, small lesions, which can be just as painful as larger lesions, may be missed (Sharp et al, 2003). Clinical assessment remains the most reliable

Figure 2. Coronal magnetic resonance scan of a forefoot showing Morton's neuroma in the third to fourth interspace.

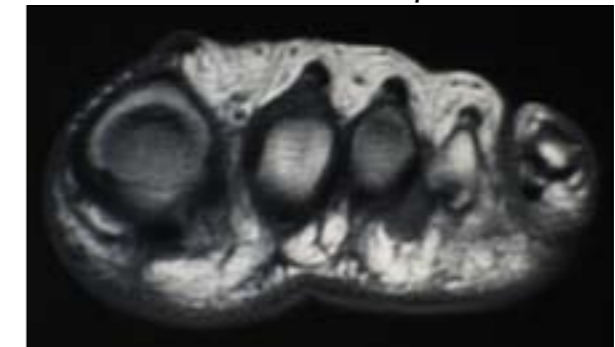
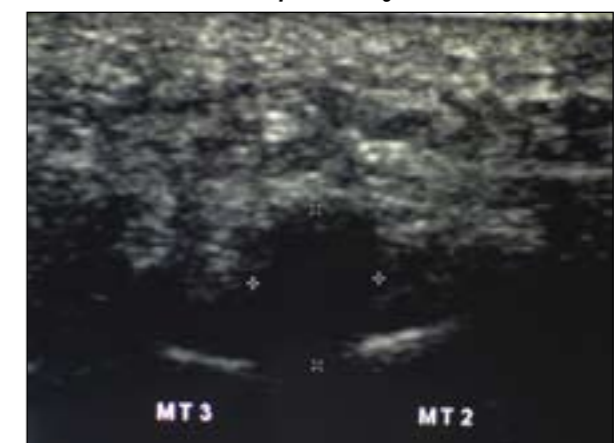


Figure 3. Ultrasound scan of a forefoot showing a hypochoic Morton's neuroma in the second to third interspace. The plantar surface of the foot is at the top of the image.



method of diagnosis, and in general imaging is used where there is uncertainty of the diagnosis or the location of the neuroma. Ultrasound is usually the most accessible imaging modality, but is dependent on the skill of the investigator in demonstrating the lesion between the metatarsal heads which prolapses into the forefoot fat pad with mediolateral forefoot compression. It is also useful in the assessment of patients with recurrent symptoms after surgery (Levine et al, 1998).

How should Morton's neuroma be managed? Footwear

Pain relief can be obtained by adjustments to footwear. Our feet tend to get broader as we get older, yet few patients consider this when buying shoes. Wider fitting shoes tend to be more comfortable, and lower heels will reduce forefoot loading. Insoles, such as a metatarsal bar or dome, can be helpful in reducing the loading under the region of the metatarsal heads, but the orthotist must ensure that there is sufficient space inside the shoe to comfortably accommodate both the insole and the foot. Trainers are often more comfortable than dress shoes, but are not always acceptable. Orthoses can also be helpful in addressing other problems such as a flexible flat foot deformity. Saygi et al (2005) found that 63% of patients had satisfactory relief of symptoms with these measures, but better results were obtained with steroid injection.

Steroid injection

Steroid injections to the region of the neuroma are used to manage symptoms. The injection is inserted through the relevant webspace and placed on the plantar side of the deep transverse intermetatarsal ligament. There is a risk of inducing thinning of the forefoot fat pad and skin, which is why the plantar approach should be avoided, and repeated injections are unwise. The main drawback as a treatment is the unpredictability of the duration of response, with most patients experiencing recurrent symptoms within 6–12 months. Others report better responses with 82% relief at 1 year (Saygi et al, 2005) and 30% at 2 years (Greenfield et al, 1984). Steroid injection can, however, be useful as a diagnostic test in those cases where diagnosis remains in doubt.

Surgery

Most patients will seek surgical treatment because of persistent or recurrent symptoms. Excision of the interdigital nerve and neuroma is the mainstay of management. This can be done through either a plantar or a dorsal approach. A distal web incision does not allow sufficient access to the nerve proximally. The plantar approach involves a longitudinal incision in the relevant interspace with careful incision of the fat pad, avoiding blunt dissection which increases fat pad damage and scarring, down to the neurovascular bundle (Figure 4). The nerve and its swelling are inspected, and the bifurcation identified. The nerve is cauterized proximally and distally and then

excised, ensuring that the proximal stump is well proximal to the MTP joints and intermetatarsal ligament. The wound is closed carefully, ensuring that the dermis layer is accurately apposed, using interrupted sutures which are removed at 7–10 days. Heel weight bearing is allowed during this time. The alternative, dorsal approach, avoids any plantar wound healing problems. Dissection is made between the respective metatarsals which are distracted. The intermetatarsal ligament is divided to expose the nerve and neuroma, which are then excised. Occasionally an intermetatarsal bursa will be found which may be the cause of symptoms and this should be excised. Rarely other lesions such as a ganglion may be found.

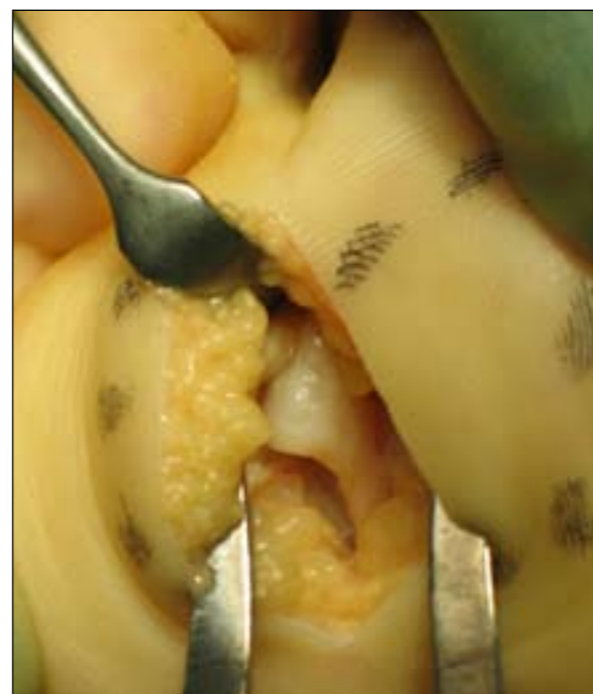Decompression of the interdigital nerve by division of the deep transverse intermetatarsal ligament and neurectomy without resection has been advocated. Comparison with neurectomy showed similar results in a prospective study, but neurectomy appeared to be associated with a greater risk of recurrence (Díez et al, 1999).

The excised specimen is sent for histological examination (Figure 5). This is generally regarded as the definitive confirmation of the diagnosis, although some doubt has been thrown on this by the finding that nerves excised at autopsy from people who did not have any history of foot problems were indistinguishable microscopically from specimens excised from patients with symptoms of Morton's neuroma, although the latter tended to be larger (Morscher et al, 2000).

How effective is surgical management?

Surgical excision of the interdigital nerve provides satisfactory relief of symptoms in over 80% of patients (Díez et al,

Figure 4. Enlarged interdigital nerve between the third and fourth metatarsal heads exposed through a plantar incision.



al, 1999; Mann, 1999; Coughlin and Pinsonneault, 2001). However, many patients have some residual discomfort in the region of the surgery and 70% still have some degree of footwear restriction (Schroven and Geutjens, 1995). For those who underwent the plantar approach this is usually attributed to wound healing problems, and for the dorsal approach to disruption and instability relating to the divided deep transverse intermetatarsal ligament, which normally functions to prevent splaying of the metatarsals and control the toes (Stainsby, 1997). There have been no direct comparisons but there does not appear to be any difference between the two approaches in terms of overall success. A thickened plantar scar may be painful, but usually settles after a few months, and only rarely requires scar excision and resuture.

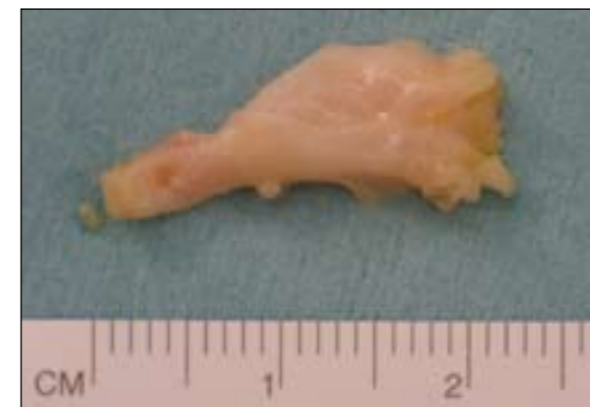Numbness in the toes is rarely a clinical problem with most patients being unaware of any sensory loss. About 50% of patients will have sensation in the toes in the respective interspace and so this is not a useful sign in determining the adequacy of resection (Mann, 1999).

Recurrent symptoms, similar to the original neuroma, have been reported in up to 20% of patients, two-thirds of them within 1 year of surgery (Johnson et al, 1988; Delmi, 2002). These may relate to inadequate resection of the Morton's neuroma or the development of a true neuroma that has become adherent to the intermetatarsal ligament or MTP joint capsule. Ultrasound may be useful in investigating these patients, looking for a discrete hypochoic lesion within the scarring from the original surgery (Levine et al, 1998). Non-surgical management options may be tried but are not often successful and excision of the lesion is recommended through a plantar incision, ensuring that the proximal resection is distant from the MTP joint capsule and ligaments with the nerve stump in the region of the interosseous muscles of the foot.

Conclusions

The history and examination findings are the most reliable features in the diagnosis of Morton's neuroma. Imaging studies show that ultrasound and MR are equally effective,

Figure 5. The excised specimen. The common digital nerve is at the left, and the bifurcation can be discerned at the distal part of the swelling to the right.



but both can miss small lesions. Conservative management can be helpful, but many patients opt for surgery. Debate continues as to whether a dorsal or plantar approach is better, with both at risk of complications, and mild persistent symptoms are not uncommon. **BJHM**

Conflict of interest: none.

- Betts RP, Bygrave CJ, Jones S, Smith TWD, Flowers MJ (2003) Ultrasonic diagnosis of Morton's neuroma: a guide to problems, pointers, pitfalls and prognosis. *The Foot* **13**: 92–9
- Bullough PG (1997) Benign soft tissue tumours: Morton's neuroma. In: Bullough PG, ed. *Orthopaedic Pathology*. Mosby-Wolfe, London: 447–9
- Coughlin MJ, Pinsonneault T (2001) Operative treatment of interdigital neuroma. A long-term follow-up study. *J Bone Joint Surg [Am]* **83-A**: 1321–8
- Delmi M (2002) Nerve compression syndromes in the athletic foot. 4th Congress of the European Foot and Ankle Society, Seville
- Díez EM, Mas SM, Pi JF, Aramburo F (1999) Comparative results of two different techniques in the treatment of the Morton's neuroma. *The Foot* **9**: 134–7
- George VA, Khan AM, Hutchinson CE, Maxwell HA (2005) Morton's neuroma: the role of MR scanning in diagnostic assistance. *The Foot* **15**: 14–16
- Greenfield J, Rea JJ, Ilfeld FW (1984) Morton's interdigital neuroma: indications for treatment by local injections versus surgery. *Clin Orthop* **185**: 142–4
- Johnson JD, Johnson KA, Unni KK (1988) Persistent pain after excision of an interdigital neuroma. *J Bone Joint Surg [Am]* **70-A**: 651–7
- Levine SE, Myerson MS, Shapiro PP, Shapiro SL (1998) Ultrasonographic diagnosis of recurrence after excision of an interdigital neuroma. *Foot Ankle Int* **19**: 79–84
- Levitsky KA, Alman BA, Jevsevar DS, Morehead J (1993) Digital nerves of the foot: Anatomic variations and implications regarding the pathogenesis of interdigital neuroma. *Foot Ankle* **14**: 208–14
- Mann RA (1999) Diseases of the nerves. In: Coughlin MJ, Mann RA, eds. *Surgery of the Foot and Ankle*. Mosby, St Louis: 502–24
- Morscher E, Ulrich J, Dick W (2000) Morton's intermetatarsal neuroma: morphology and histological substrate. *Foot Ankle Int* **21**: 558–62
- Mulder JD (1951) The causative mechanism in Morton's metatarsalgia. *J Bone Joint Surg* **33**: 94–5
- Saygi B, Yildirim Y, Saygi EK, Kara H, Esemeli T (2005) Morton neuroma: comparative results of two conservative methods. *Foot Ankle Int* **26**: 556–9
- Schroven I, Geutjens G (1995) Results of excision of the interdigital nerve in the treatment of Morton's metatarsalgia. *The Foot* **5**: 196–8
- Sharp RJ, Wade CM, Hennessey MS, Saxby TS (2003) The role of MRI and ultrasound imaging in Morton's neuroma and the effect of size of lesion on symptoms. *J Bone Joint Surg [Br]* **85-B**: 999–1005
- Smith TWD, Jones S (1999) Morton's misnomer and Durlacher's metatarsalgia. *The Foot* **9**: 209
- Stainsby GD (1997) Pathological anatomy and dynamic effect of the displaced plantar plate and the importance of the integrity of the plantar plate - deep transverse metatarsal ligament tie-bar. *Ann Roy Coll Surg Engl* **79**: 58–68

KEY POINTS

- Morton's neuroma is a localized painful condition affecting the forefoot.
- It is more common in women between the ages of 30 and 60 years and affects the interdigital nerves of the third to fourth or the second to third interspaces.
- A detailed history and examination are required for making the diagnosis.
- Changes to footwear can be effective in relieving symptoms.
- Steroid injection can provide temporary relief, and is useful as a diagnostic test.
- A meticulous surgical technique is required to minimize the risk of persistent discomfort and recurrent neuroma and can provide good relief of the neuritic pain.