

Unilateral ocular myasthenia gravis in an acute medical take: is a Tensilon test useful?

Introduction

Unilateral ocular involvement is an unusual presentation of myasthenia gravis. The diagnosis should be suspected in any patient presenting with progressive diplopia. The Tensilon test is a rapid and sensitive tool to expedite the diagnosis.

Discussion

Approximately 20% of patients with myasthenia gravis will have disease confined only to the extra-ocular muscles (Sommer et al, 1993). These patients often present a diagnostic challenge (Feuer and Jagoda, 2001).

Analysis for anti-acetylcholine receptor antibodies (anti-AChR) may take some time as this test is only performed in specialist centres. Anti-AChR are detectable in the serum of approximately 80% of all myasthenia patients, but in only 50% of patients with weakness limited to the ocular muscles (Beekman and Kuks, 1997).

In this case the Tensilon test provided an immediate diagnosis allowing early intervention while further investigations were pending.

From the available literature, one previous study demonstrated that the Tensilon test was positive in 46 out of 48 patients (95%) with pure ocular myasthenia, while anti-AChR antibodies were detected in approximately 46% of patients (Evoli et al, 1988). Disease progression is most rapid within the first 3 years, and more than half of deaths caused by myasthenia gravis occur during this period (Feuer and Jagoda, 2001).

Making a timely diagnosis leads to early treatment and offers the patient prompt relief from both anxiety and the presenting symptoms. **BJHM**

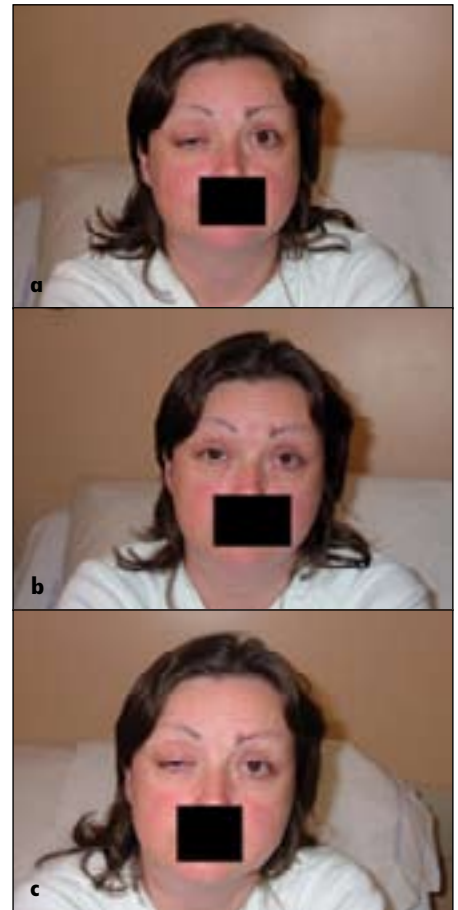
Beekman R, Kuks JB (1997) Myasthenia gravis: diagnosis and follow-up of 100 consecutive patients. *Neurology* **244**: 112–18

Evoli A, Tonali P, Bartocioni E, Lo Monaco M (1988) Ocular myasthenia: diagnostic and therapeutic problems. *Acta Neurol Scand* **77**: 31–5

Feuer H, Jagoda A (2001) Myasthenia gravis presenting as a unilateral abducens nerve palsy. *Am J Emerg Med* **19**: 410–12

Sommer N, Melms A, Weller M, Dichgans J (1993) Ocular myasthenia gravis. A critical review of clinical and pathophysiological aspects. *Doc Ophthalmol* **84**: 309–33

Figure 1. a. Marked ptosis before the administration of edrophonium (8mg iv). b. Improvement in ptosis 2 minutes after edrophonium. c. Return of ptosis 5 minutes after the administration of edrophonium.



Case Report

A 42-year-old woman presented to an eye clinic with a 2-week history of diplopia. Examination revealed signs of a right sixth nerve palsy. A computed tomography (CT) brain scan was normal. Six weeks later she presented during the acute medical take with increasing diplopia, a drooping right eyelid and unsteadiness. Direct questioning revealed that the drooping became progressively worse throughout the day. She had no relevant past medical history or any regular medication. Examination revealed a partial right ptosis and signs of right third, fourth and sixth nerve palsy. Diplopia on binocular vision resolved on patch testing; neurological examination was otherwise unremarkable, with no evidence of limb weakness.

A magnetic resonance imaging scan of the brain and CSF examination were unremarkable. Ocular myasthenia was suspected, anti-acetylcholine receptor antibody test was requested, and a Tensilon test was performed with full resuscitation equipment available. Following the administration of the test dose (2 mg) of intravenous edrophonium (Tensilon) a visible improvement in the right ptosis was observed. Subsequent administration of a further 8 mg edrophonium yielded more marked improvement, with complete correction of the right ptosis (Figure 1) and a subjective decrease in diplopia on right gaze. A diagnosis of unilateral ocular myasthenia gravis was made on the basis of the clinical picture and the positive Tensilon test.

A neurological opinion was sought and the patient commenced on pyridostigmine 60 mg four times a day. Further investigations included a CT scan of the thorax which revealed a 2 cm retrosternal mass, compatible with thymic hyperplasia. Five weeks after the positive Tensilon test, a report of strongly positive anti-acetylcholine receptor antibodies (anti-acetylcholine receptor antibodies >8 nmol/litre, normal range 0–0.5 nmol/litre) was received. The diplopia continues to improve and the patient has regular follow up.

Dr D McCarthy is House Physician,
Dr C Patel is Senior House Officer and
Dr JAO Ahlquist is Consultant Physician,
Southend Hospital NHS Trust, Westcliff on
Sea, Essex and **Dr JW Stephens** is Senior
Lecturer and Honorary Consultant at the
University of Wales Swansea and Morriston
Hospital, Swansea SA2 8PP

Correspondence to: Dr JW Stephens