

Aspiration of the elbow joint

Indications

Indications for aspiration and injection of the elbow joint include:

- Osteoarthritis
- Rheumatoid arthritis
- Crystal arthropathies
- Septic arthritis
- Radial head fractures.

The technique described below can be used for any of the above conditions. Aspiration of the elbow joint following radial head fracture will form the focus of this discussion.

Fractures to the radial head typically follow a fall onto the outstretched hand. Patients present with limited, painful elbow motion in both flexion/extension and pronation/supination. Tenderness may be elicited on palpation of the radial head. A haemarthrosis is present – this is seen as the ‘fat pad’ sign on X-ray. Diagnosis is confirmed by two-plane radiography (Figures 1a and b).

Aspiration serves three functions in radial head fractures:

1. Confirms diagnosis – the aspirate contains blood and fat globules
2. Provides analgesia – relieving the capsular distension caused by haemarthrosis and by instilling a local anaesthetic agent
3. Allows examination of range of motion under local anaesthesia to assess for the presence of a mechanical block.

Planning

Having selected the patient with a suspected or radiologically proven radial head fracture, the clinician must prepare the necessary equipment to carry out the aspiration and infiltration of local anaesthetic. A collar and cuff must also be prepared to hold the arm following the procedure.

Mr Sam Oussedik is Clinical and Research Fellow in Orthopaedic Surgery, Department of Orthopaedics, University College Hospital, London NW1 2BU and **Mr Fares Haddad** is Consultant Orthopaedic and Trauma Surgeon, Department of Trauma Surgery, Middlesex Hospital, London

Correspondence to: Mr S Oussedik

Technique

Equipment

- Sterile gloves
- Skin preparation – iodine based or chlorhexidine
- Sterile gauze
- 5 ml syringe
- 22 gauge needle (blue)
- 2.5 ml of 2% lidocaine (lignocaine) and 0.5% marcaïn in a labelled syringe
- Adhesive dressing.

Procedure

The patient is positioned sitting on a couch with the arm resting on a side table. The elbow is placed in 45° of flexion. A sterile field is prepared by cleansing the skin over the lateral aspect of the elbow using the skin preparation and sterile gauze. The elbow joint is approached laterally, avoiding the ulnar nerve. The landmarks to palpate are illustrated in Figure 2. The needle is mounted onto the empty 5 ml syringe. The site for insertion of the needle is the centre of a triangle formed by the radial head, the lateral epicondyle and the tip of the olecranon. The needle is then advanced in the direction of the medial epicondyle.

The syringe is aspirated as the needle is advanced. If a haemarthrosis is present,

entry to the joint capsule is signalled by the aspiration of blood. The joint is aspirated until dry. The syringe is then disengaged from the needle, taking care not to dislodge the tip from the joint. The aspirate may then be decanted into a sterile container. Examination of the fluid once it has been allowed to settle may demonstrate fat globules. The fluid can then be sent for further microbiological or biochemical analysis as required.

The 2.5 ml syringe is then mounted onto the needle which has remained within the elbow joint. The lidocaine and marcaïn can be infiltrated into the joint. The needle is finally withdrawn and an adhesive sterile dressing placed over the injection site.

A theoretical risk of introducing infection to the joint exists, and therefore all precautions must be taken to avoid this by the use of meticulous aseptic technique.

Post-procedure

Following aspiration of the elbow and injection of the local anaesthetic, the elbow can be examined for the presence of a mechanical block to flexion or rotation. In the case of displaced radial head fractures, a fragment can become interposed between the radial head remnant and the

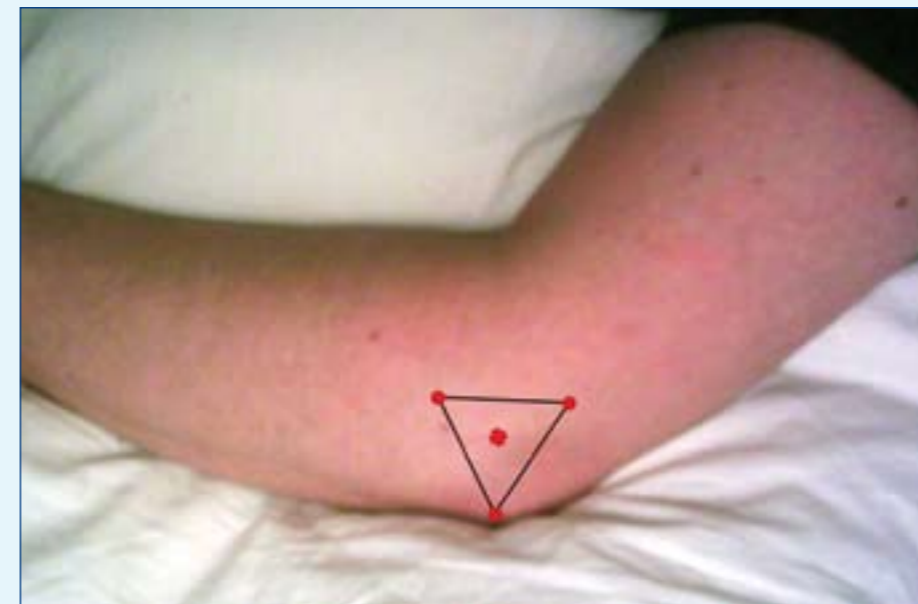
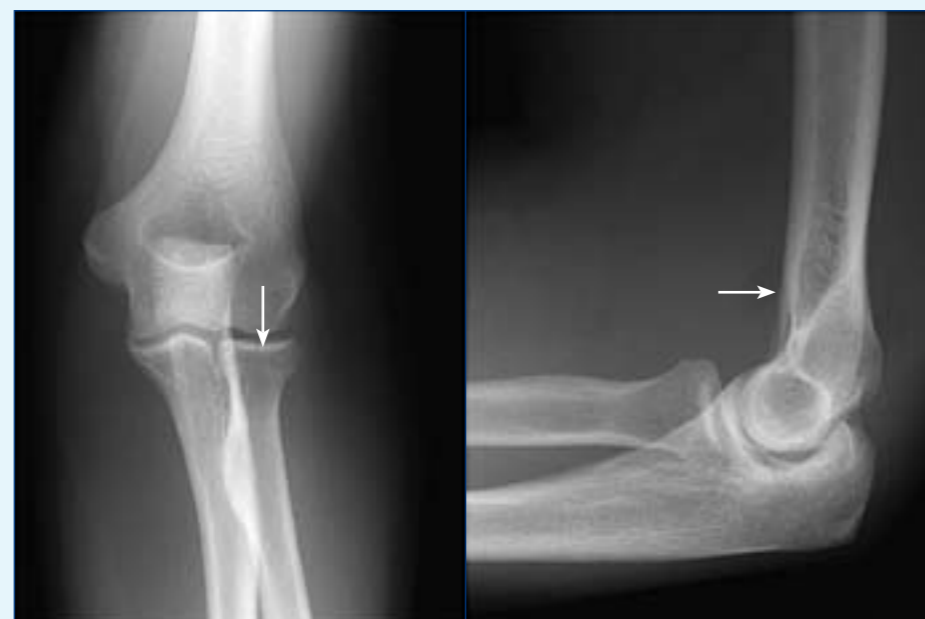

Figure 2. Landmarks for lateral aspiration of the elbow joint.

capitellum, causing a mechanical block to movement. Having abolished the pain inhibition caused by the haemarthrosis, any residual loss of range of motion may be the result of a mechanical block. This may be an indication for operative treatment.

Aspiration of the elbow in radial head fractures increases the speed of recovery, as a full range of motion is restored more quickly and patients are more able to comply with physiotherapy (Holdsworth et al, 1987; Dooley et al 1991). **BJHM**

Figure 1. a. Anteroposterior radiograph of elbow showing undisplaced radial head fracture (arrow). b. Lateral radiograph of elbow showing fat pad sign (arrow).



Conflict of interest: none.

Dooley JF, Angus PD (1991) The importance of elbow aspiration when treating radial head fractures. *Arch Emerg Med* 8(2): 117–21
 Holdsworth BJ, Clement DA, Rothwell PN (1987) Fractures of the radial head—the benefit of aspiration: a prospective controlled trial. *Injury* 18(1): 44–7

KEY POINTS

- Aspiration of radial head fracture haematoma and injection of local anaesthetic allows assessment for mechanical block to flexion.
- The needle is introduced at a point at the centre of a triangle formed by the lateral epicondyle of the humerus, the tip of the olecranon and the lateral aspect of the radial head.
- Aspiration of the elbow following radial head fracture improves the rate of recovery.