

The clinical anatomy of the antecubital fossa

Introduction

To the anatomist, the antecubital fossa is the space through which the principal vascular and nervous trunks pass into the forearm. To the surgeon it is also the site of possible injury to the brachial artery in fractures around the elbow, with the risk of Volkmann's ischaemic contracture constantly in mind. It is here where the surgeon is tempted to use the large superficial veins for venous access, but knows only too well the dangers of inadvertent intra-arterial or intraneural injection – something that may well be encountered in a 'main-line' drug addict. It is also a convenient site for arterial cannulation and for anaesthetic blocks of the nerves to the forearm.

Boundaries

The antecubital fossa is a triangle, which is bounded by the brachioradialis inferiorly and laterally (*Figure 1a*), by pronator teres inferiorly and medially and by an imaginary line which joins the lateral and medial epicondyles of the humerus above.

Professor Harold Ellis is Clinical Anatomist, Guy's, King's and St Thomas' School of Biomedical Science, London SE1 1UL

Roof

The roof of the fossa is deep fascia, reinforced by the tough bicipital aponeurosis. On this deep fascia, lying within the variable amount of fat contained in the superficial fascia, lies the median cubital vein, which is crossed superficially, or sometimes deeply, by the medial cutaneous nerve of the forearm, a direct branch of the medial cord of the brachial plexus.

This nerve is here occasionally damaged at attempted venepuncture. Medially courses the basilic vein, while laterally lie the cephalic vein and the lateral cutaneous nerve of the forearm, which is the continuation of the musculocutaneous nerve after this has given off its motor branches to the anterior compartment muscles of the upper arm – the biceps, brachialis and coraco-brachialis.

Contents

If the muscular walls of the fossa are retracted (*Figure 1b*), the following structures can be revealed from the medial to the lateral side:

- The median nerve
- The brachial artery, which bifurcates at the level of the neck of the radius into the radial and ulnar artery
- The tendon of biceps

- Brachialis, with the lateral cutaneous nerve of the forearm emerging between these two muscles
- The radial nerve, accompanied by the recurrent branch of the radial artery, as this nerve emerges between brachialis and brachioradialis.

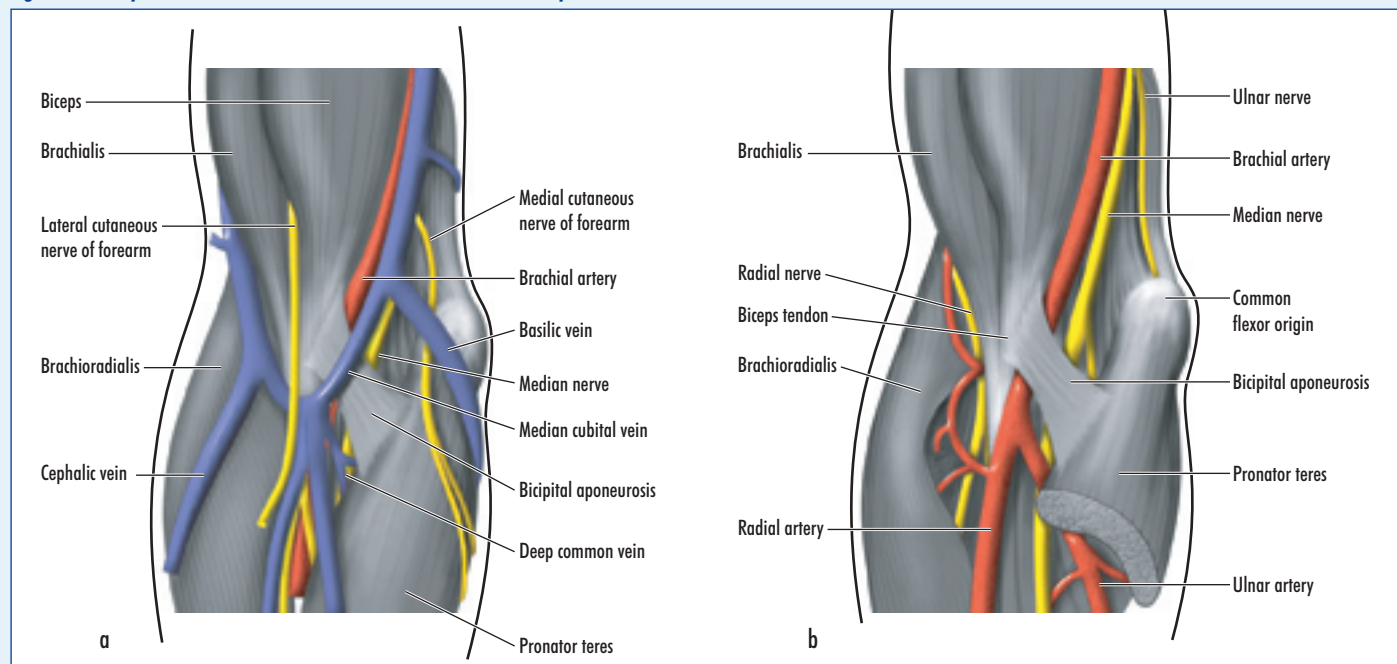
Note that the radial nerve promptly divides into its two terminal branches, the posterior interosseous nerve, which is entirely motor, and which supplies the muscles in the posterior compartment of the forearm, and the superficial radial nerve, which is entirely sensory.

Structures of particular clinical importance

The superficial veins

The cephalic vein commences in the anatomical snuff box by draining the dorsal venous arch on its radial side (*Figure 2*). In the snuff box it crosses superficial to the superficial radial nerve, it ascends the forearm – easily visible in thin subjects – and then lies in a groove on the lateral aspect of the biceps. The vein pierces the deep fascia at the lower border of the pectoralis major, then runs in the deltopectoral groove between this muscle and the deltoid – a groove that is readily seen and felt and where the vein can be reached by a cut-

Figure 1. a. Superficial dissection of the antecubital fossa. b. Deep dissection of the antecubital fossa.



down if necessary. The vein now dives through the clavipectoral fascia to terminate in the axillary vein.

Attempts to insert a catheter by a cut-down on the cephalic vein frequently fail to enter the axillary vein (and hence the subclavian), because of the sharp angulation of the vein in its passage through the clavipectoral fascia.

The basilic vein commences at the ulnar side of the dorsal venous arch on the back of the hand, drains the ulnar side of the forearm, then ascends along the medial border of the biceps to pierce the deep fascia at the middle of the upper arm. From here the vein runs proximally to the level of the lower border of the axilla, where it is joined by the venae comitantes accompanying the brachial artery to form the axillary vein.

The median cubital vein, sometimes called the median basilic or the median cephalic vein, usually arises from the cephalic vein about 2.5 cm distal to the level of the lateral epicondyle and then joins the basilic vein about 2.5 cm above the transverse crease of the elbow, giving the rather drunken H-shaped pattern shown in *Figure 2a*. It receives tributaries from the front of the forearm, which often include a prominent median antebrachial

(or forearm) vein, as well as giving off a deep median vein, which pierces the deep fascia of the fossa to enter the venae comitantes around the brachial artery.

A very common variant of this pattern is for the median antebrachial vein to bifurcate just distal to the antecubital fossa, one limb passing to the cephalic, the other to the basilic vein, to give an M-shaped arrangement, as shown in *Figure 2b*.

The bicipital aponeurosis

This is a thickened sheet of deep fascia (*Figures 1a* and *b*) which arises from the medial border of the lower end of the biceps muscle and its tendon and which passes medially and downwards to blend with the deep fascia over the origins of the forearm flexor muscles. Its function is to prevent ‘bow-stringing’ of the biceps in flexion of the elbow.

Its upper edge is thickened and can be readily palpated:

Bend your elbow; run your index finger down the medial border of biceps; when you reach the edge of the tendon your finger tip encounters this crescentic upper edge of the aponeurosis. Note also that now you feel, seriatim, the tendon of biceps, next medial to this the pulsation of the brachial artery, next medially you get paraesthesiae in the forearm as your finger presses on the adjacent median nerve. You have now confirmed on yourself this important relationship of tendon, artery, nerve

This fortuitously placed fascial barrier protecting the brachial artery was very much appreciated by the barber surgeons of bygone days who used the median cubital vein for blood-letting. They were well aware of the risk of accidental damage to the underlying brachial artery in their squirming and struggling patients and named it the *Grâce a Dieu* fascia – the Praise be to God fascia!

The brachial artery

The brachial artery (*Figure 1b*), like many structures in the body, is subject to anatomical variations. Some of these are clinically important and surgeons need to be aware of them. These include:

1. The artery may bifurcate anywhere in the arm, even up to the level of the axilla, into a main trunk, which continues into the forearm as a common interosseous artery, and a common stem, which is

called the superficial brachial artery, which divides at a variable level into its radial and ulnar branches. This variant is said to occur in about 1% of subjects.

2. A superficial radial artery may be given off in the upper arm. This anomaly, in about 14% of subjects, is of little clinical importance as the artery continues in a manner similar to a normal radial artery. It might cause some confusion if it is seen on an upper limb angiogram.

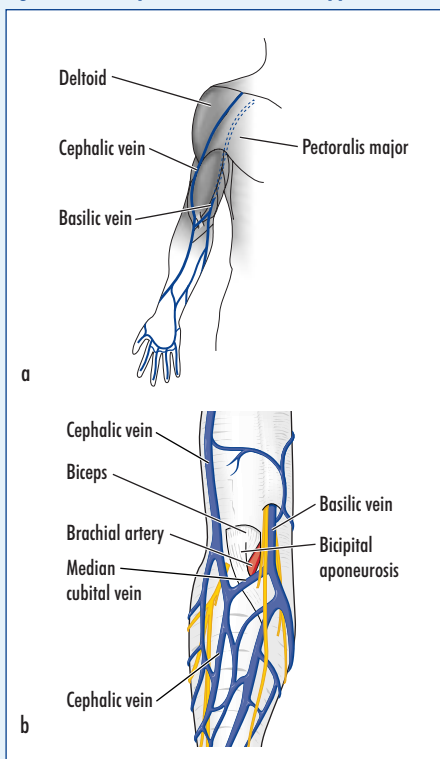
3. A superficial ulnar artery may be given off in the upper arm in 2% of cases. It descends nearly always superficial to the forearm flexor muscles. It then sweeps down on the radial side of flexor carpi ulnaris to take up, in the distal forearm, the normal relationships of the ulnar artery. This superficial ulnar artery may lie beneath the deep fascia throughout its course, but a particular danger is that it may lie subcutaneously, either at the elbow or in the upper forearm. You can suspect this anomaly when you are taking a patient’s blood pressure and you note a surprisingly prominent pulse at the elbow.

It is this anomaly, when the anomalous artery lies immediately deep to the vein, and without the protection of the bicipital aponeurosis, which renders inadvertent intra-arterial injection more likely when using the median cubital vein for attempted intravenous injection. **BJHM**

Figures 1 and 2 are reproduced from Ellis et al (2004) by kind permission of Blackwell Publishing. Conflict of interest: none.

Ellis H, Feldman S, Harrup-Griffiths W (2004) *Anatomy for Anaesthetists*. 8th edn. Blackwell Publishing, Oxford

Figure 2. The superficial veins of the upper limb.



KEY POINTS

- The antecubital fossa is the space through which the principal vascular and nervous trunks pass into the forearm.
- It is also the site of possible injury to the brachial artery in fractures around the elbow.
- It is also a convenient site for arterial cannulation and for anaesthetic blocks of the nerves to the forearm.
- Clinically important structures in the antecubital fossa include the superficial veins, the bicipital aponeurosis and the brachial artery.