

Radial arterial lines

Introduction

Intra-arterial cannulae in the radial artery are used for invasive arterial blood pressure (IABP) measurement and for collection of blood for analysis. The radial artery is the preferred site for insertion because of low complication rates. Arterial lines are the gold standard for accurate blood pressure (BP) measurement. They may be used in intensive care units (ICU) and high dependency units and in anaesthetized patients undergoing surgical procedures. An understanding of basic principles enables arterial lines to be used safely in these settings.

Indications

The indications for a radial arterial line are:

1. Continuous, beat-to-beat BP measurement. Examples include patients on the ICU requiring inotropic support, or patients with severe cardiovascular disease undergoing surgery.
2. Frequent arterial blood gas analysis in patients with respiratory failure, or severe acid/base disturbance.

Choice of arterial site

The radial artery has low complication rates compared with other sites. It is a superficial artery which aids insertion, and also makes it compressible for haemostasis.

The ulnar, brachial, axillary, dorsalis pedis, posterior tibial, femoral arteries are alternatives.

Preparation

Allen's test is recommended by many textbooks before the insertion of a radial arterial line. This is used to determine

collateral perfusion between the ulnar and radial arteries to the hand: poor collateral perfusion is said to be present in 12% of people. If ulnar perfusion is poor and a cannula occludes the radial artery, blood flow to the hand may be reduced. The test is performed by asking the patient to clench their hand. The ulnar and radial arteries are occluded with digital pressure. The hand is unclenched and pressure over the ulnar artery is released. If there is good collateral perfusion, the palm should flush in less than 6 seconds. In practice the usefulness of this test is questionable.

Equipment

- Arterial cannulae. Made from polytetrafluoroethylene (Teflon) to minimize the risk of clot formation (Figure 1), they are short, with parallel sides to minimize the effect on blood flow distally. A 20G (pink) cannula is used in adult patients, a 22G (blue) for paediatrics, and a 24G (yellow) for neonates and small babies. Larger gauge cannulae increase the risk of thrombosis, smaller cannulae cause damping of the signal. The cannula is connected to an arterial giving set.
- Arterial giving set (Figure 2). Specialized plastic tubing, short and stiff to reduce resonance (see below), connected to a 500 ml bag of saline.
- 500 ml bag of saline. This is pressurized to 300 mmHg using a pressure bag, i.e. a pressure higher than arterial systolic pressure to prevent backflow from the cannula into the giving set.



Figure 1. Two arterial cannulae.

The arterial giving set and pressurized saline incorporate a continuous slow flushing system of 3–4 ml per hour to keep the line free from clots. The arterial giving set and arterial line should be free from air bubbles. The line is attached to a transducer.

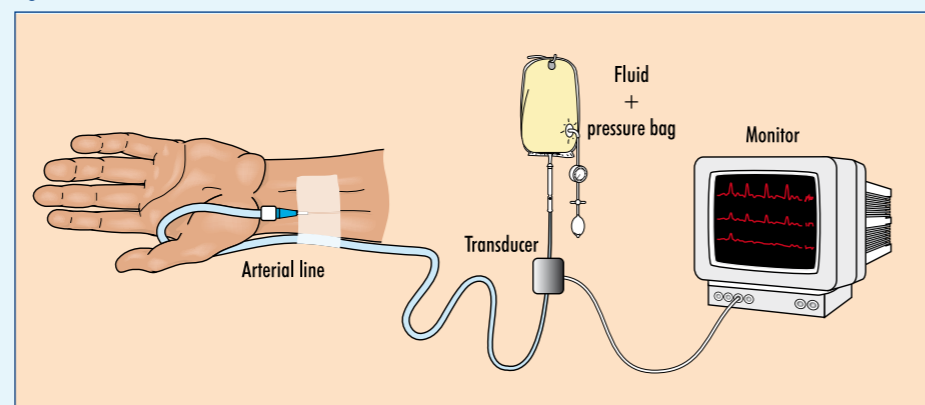
- Transducer, amplifier and electrical recording equipment. The transducer is zeroed and placed level with the heart.

Technique of radial line insertion

After cleaning the skin, lidocaine 1–2% is infiltrated over the radial artery. There are three common insertion techniques. Whichever technique is used, the cannula should never be forced along the artery as local damage may occur.

1. Direct cannulation (Figure 3). Insertion technique similar to that of a venous cannula. Extension of the wrist brings the artery closer to the surface. Stabilizing the wrist in this position either with tape or with the aid of an assistant makes insertion easier. The

Figure 2. Radial arterial line.



Dr Rachel Hignett is Specialist Registrar in Anaesthetics, Nuffield Department of Anaesthetics, The John Radcliffe Hospital, Oxford and **Dr Robert Stephens** is Academy of Medical Sciences/the Healthcare Foundation Clinical Research Training Fellow, Institute of Child Health, UCL, London WC1N 1EH

Correspondence to: Dr R Stephens

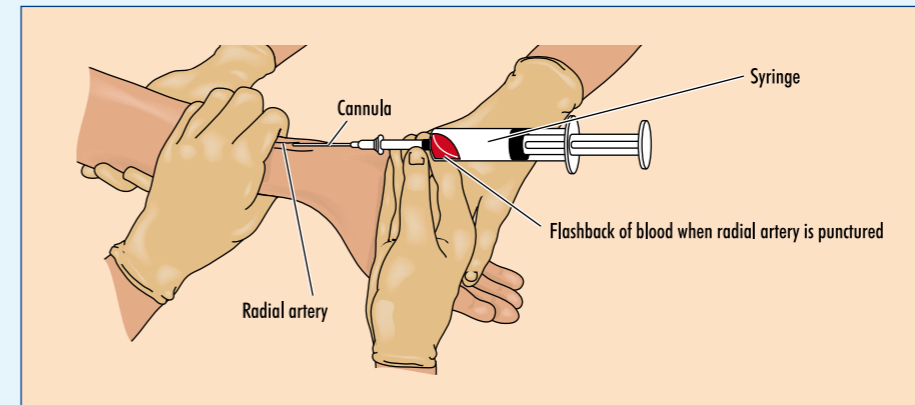


Figure 3. Direct cannulation of the radial artery.

radial artery is palpated. The cannula is inserted aiming to hit the middle of the artery at an angle of approximately 30° to the skin. When there is free flow of arterial blood back into the hub of the cannula, the cannula sheath is advanced over the needle into the artery.

2. Transfixion. After obtaining a flashback, the cannula is advanced through the posterior wall of the artery. The needle is removed and a syringe attached. The cannula is slowly withdrawn while aspirating. Once free aspiration is achieved, the cannula is advanced proximally along the artery. This is a particularly useful technique in paediatric patients.

3. Guidewire (Seldinger) technique. A guidewire may be used if advancement of the cannula sheath over the needle proves difficult, for example in atherosclerotic disease. The guidewire is inserted through the cannula sheath after removal of the cannula needle (or through needles which are provided in some arterial cannulation sets). The guidewire should advance freely along the artery. The cannula sheath is then advanced along the artery, and the guidewire is removed.

Complications

Haemorrhage

Haemorrhage may occur if there are leaks in the system. Connections must be tightly secured and the giving set and line closely observed. Appropriate BP alarm limits should be set.

Thrombosis

Thrombosis as a result of radial artery occlusion is rarely problematic. Natural history is recanalization of the arterial lumen:

- Partial occlusion occurs in 1.5–35% of cases. Risk factors include large cannula width, multiple attempts at insertion and long duration of use
- Permanent total occlusion occurs in 0.09% of cases; loss of digits is very rare. Risk factors for digital loss include pre-existing arterial disease, prolonged hypotension and use of vasopressors.

Infection

Sepsis or bacteraemia secondary to infected radial arterial lines is very rare (0.13%); local infection is more common. If the area looks inflamed the line site should be changed. Risk factors for infection include co-existing bacteraemia and long duration of use.

Drug injection

Accidental drug injection may cause severe, irreversible damage to the hand. To try to prevent this:

- No drugs should be injected via an arterial line

- The line should be labelled (in red) to reduce the likelihood of this occurring.

Emboli

Air or thromboemboli may occur. Care should be taken to aspirate air bubbles.

Other complications

Inaccuracy as a result of damping effects can occur (see below). Pseudoaneurysms can occur but are rare.

Mechanism of action

The principles of IABP measurement are the same in the radial artery as in other arteries. The column of saline in the arterial giving set transmits the pressure changes to the diaphragm in the transducer. This produces an electrical signal which is displayed as an arterial waveform.

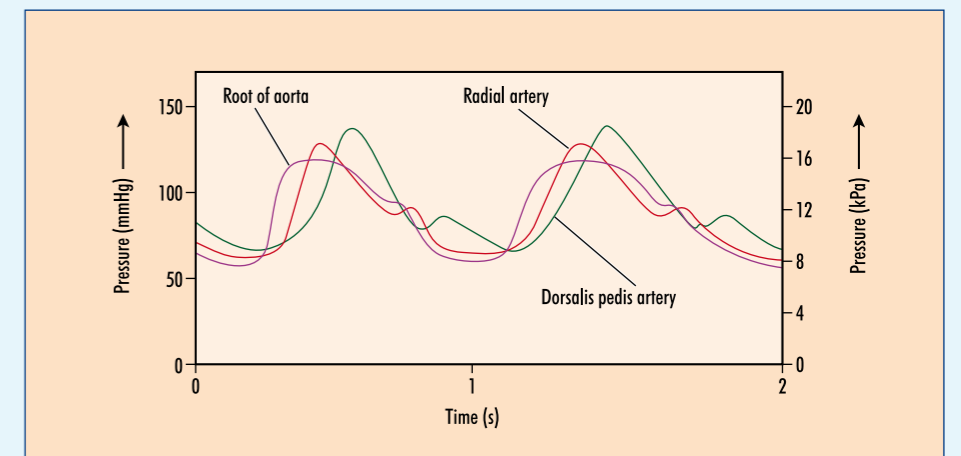
Arterial pressure waveform

Once inserted, an arterial waveform trace should be displayed at all times. This confirms that the IABP monitoring is set up correctly, and minimizes problems as a result of, for example damping (see below).

Peripheral and central arterial waveforms

Waveforms from a peripheral artery such as the radial artery differ from those of an aortic trace (Figure 4). A peripheral trace has a higher peak systolic pressure, a wider pulse pressure and a more prominent dicrotic notch, i.e. the systolic pressure in the dorsalis pedis artery is higher than in the radial artery, which is higher than in the aorta. This is because peripheral arteries are

Figure 4. Arterial pressure tracings from the aorta, radial and dorsalis pedis arteries.



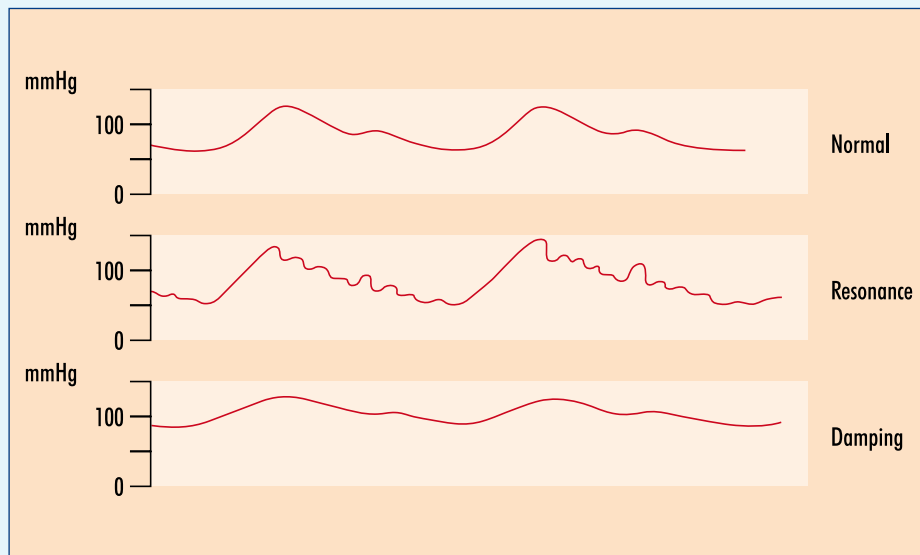


Figure 5. Comparison of normal, resonant and damped arterial traces.

smaller and less compliant than central arteries and therefore less distensible.

Additional information from arterial waveform

In addition to BP measurement, the shape of the waveform gives further useful information:

1. Myocardial contractility. Indicated by the rate of change of pressure by unit time (dP/dt), i.e. the slope of the arterial upstroke.
2. Hypovolaemia. Suggested by a narrow waveform, a low dicrotic notch and a peak pressure which varies with intermittent positive pressure ventilation breaths if the patient is ventilated, or with deep inspirations in the spontaneously breathing patient (also called an 'arterial swing').

Damping and resonance

Damping and resonance may distort the arterial pressure waveform (Figure 5), and

lead to inaccurate recording of systolic and diastolic pressures. Mean arterial pressure is usually still recorded accurately.

Any restriction in transmission of the arterial pressure to the diaphragm of the transducer results in a damped arterial waveform (Figure 5). The waveform is smoothed out without sharp changes displayed. Damping is caused by the dissipation of stored energy and is the progressive diminution of oscillations in a resonant system. This may be the result of blood clots in the system, kinking, compression of air bubbles and viscous drag of saline in the line.

Resonance is where an oscillating system (such as the transducer, diaphragm and saline column in the arterial measurement system) oscillates at maximum amplitude to an alternating external driving force (such as the arterial pressure). Resonance is minimized by using a shorter, wider and stiffer connecting catheter.

Comparison with non-invasive BP

Arterial lines measure systolic BP approximately 5 mmHg higher and the diastolic BP approximately 8 mmHg lower compared to non-invasive BP measurement techniques.

Advantages of invasive BP measurement

- Continuous BP recording
- Accurate BP recording even when patients are profoundly hypotensive
- Other information from arterial trace such as 'arterial swing', indication of myocardial contractility.

Disadvantages of invasive BP measurement

- Potential complications as listed above
- Skilled technique
- Expensive compared with non-invasive BP. **BJHM**

The authors would like to thank Dr Duncan Young and Dr Ed Burdett for reviewing the manuscript.

Figure 3 is reprinted from Moyle and Davey (1998) with permission from Elsevier. Figures 4 and 5 are reprinted from Davis et al (1995) with permission from Elsevier.

Conflict of interest: none.

Davis PD, Parbrook GD, Kenny GNC (1995) *Blood Pressure Measurement in Basic Physics and Measurement in Anaesthesia*. Butterworth-Heinemann, Oxford: 221–32

Moyle JTB, Davey A (1998) Physiological monitoring: advanced monitoring systems. In: Moyle J, Davey A, Ward C, eds. *Ward's Anaesthetic Equipment*. 4th edn. Saunders, London: 293–7

Scheer B, Perel A, Pfeiffer UJ (2002) Clinical review: complications and risk factors of peripheral arterial catheters used for haemodynamic monitoring in anaesthesia and intensive care medicine. *Crit Care* 6: 198–204

KEY POINTS

- Radial arterial lines are associated with low complication rates.
- Serious complications are very rare.
- They provide a means of accurate and continuous blood pressure measurement.
- They provide a means of repeated arterial blood gas analysis.
- They should only be used by trained staff in high dependency or intensive care unit environments.