

Management of epistaxis

Table 1. Aetiology

Local	Idiopathic (85%)
	Trauma (fractures, foreign bodies, nose picking)
	Isotrogenic
	Inflammatory (rhinosinusitis)
	Neoplastic
Systemic	Inadequately controlled hypertension
	Coagulopathies, e.g. haemophilia
	Isotrogenic, e.g. warfarin anticoagulation
	Hereditary haemorrhagic telangiectasia
	Malignancy, e.g. leukaemia

Introduction

With changes in working hours it is becoming more common for the on-call ear, nose and throat (ENT) doctor to be non-resident. There is also a trend for junior doctors to provide cover for a number of specialities on-call. It is therefore important for foundation doctors to understand the basics in management of the major ENT emergencies.

Epistaxis is a common problem presenting to both accident and emergency (A&E) and ENT departments affecting patients of all ages. Significant volumes of blood can be lost from epistaxis resulting in haemodynamic compromise, and thus epistaxis can be a life-threatening medical emergency. Effective management with appropriate senior support is key to avert complications. This article summarizes the key aspects of epistaxis management for foundation doctors to become familiar with. The aetiology is summarized in Table 1.

First aid measures

Uncontrollable epistaxis can be a life-threatening condition. Initial management is therefore the same as in any other medi-

Mr Peter Tassone is Specialist Registrar in Ear, Nose and Throat Surgery and **Dr Irfan Syed** is Senior House Officer in Ear, Nose and Throat Surgery, Department of Ear, Nose and Throat, Norfolk and Norwich University Hospital, Norwich NR4 7UY

Correspondence to: Mr P Tassone

cal emergency: assess airway, breathing and circulation.

Airway: Profuse bleeding posteriorly can obstruct the airway.

Breathing: Ventilation rate is the most sensitive clinical indicator of compromise.

Circulation: Pulse, blood pressure and oxygen saturation (pulse oximetry).

The patient should be managed sitting upright and leaning slightly forward to limit blood swallowing.

The nostrils should be pinched together firmly and the patient should be advised to breathe normally through the mouth. The patient should be encouraged to spit any blood accumulating in the mouth into a bowl held underneath the chin.

From the history (Table 2 summarizes the most pertinent points) and examination one can decide the most appropriate method of treatment (Table 3). The flow chart (Figure 1) describes the simple steps in assessing and managing epistaxis.

Table 2. Key points of a history

Which side is bleeding?
Duration of bleed?
More from nose or down throat?
Estimate of the amount of blood loss?
Previous history of epistaxis?
History of trauma or surgery to nose?
Past medical history particularly bleeding disorders, liver problems, hypertension?
Drug history, particularly aspirin or warfarin?

How to cauterize a nose

This is indicated if there is an obvious bleeding point on the anterior part of the septum, i.e. Little's area. Silver nitrate sticks (Figure 2) are the most widely available method of cautery. There is no age restriction to their use. The chemical is impregnated on the tip. They are kept in black plastic bags as the chemical degrades in sunlight. The nose should be anaesthetized topically with local anaesthetic spray, e.g. co-phenylcaine which also has vasoconstrictor properties.

The nostril should be widened with a thudicums speculum (Figure 2) to allow good visualization of Little's area. There may be an active bleeding vessel, a prominent vessel or leash of vessels or perhaps a small raised spot of mucosa (containing a vessel). It is advisable to control active bleeding with direct pressure over the nostrils or by insertion of Vaseline gauze for a few minutes, because silver nitrate does not work as effectively if there is active bleeding. Electrocautery does work well for active bleeding but this is normally used (if available) by ENT specialists and will not be given any further consideration here.

The silver nitrate stick should only be applied to the mucosa for a short period. The mucosa will turn white (as a result of the chemical burn) after a few seconds. There is a risk of perforation of the septum if the same point on both sides of the septum is cauterized. Antiseptic cream, e.g. naseptin (check for peanut allergy, as it contains peanut oil), should be applied to the area and continued for about a week, to help prevent crusting of the site

Table 3. Treatment options

Direct pressure: over nostrils
Silver nitrate (AgNO ₃) cautery
Electrocautery
Nasal tampon
Vaseline ribbon gauze
Bismuth iodoform paraffin (BIPP) paste gauze
Foley catheter
Surgery

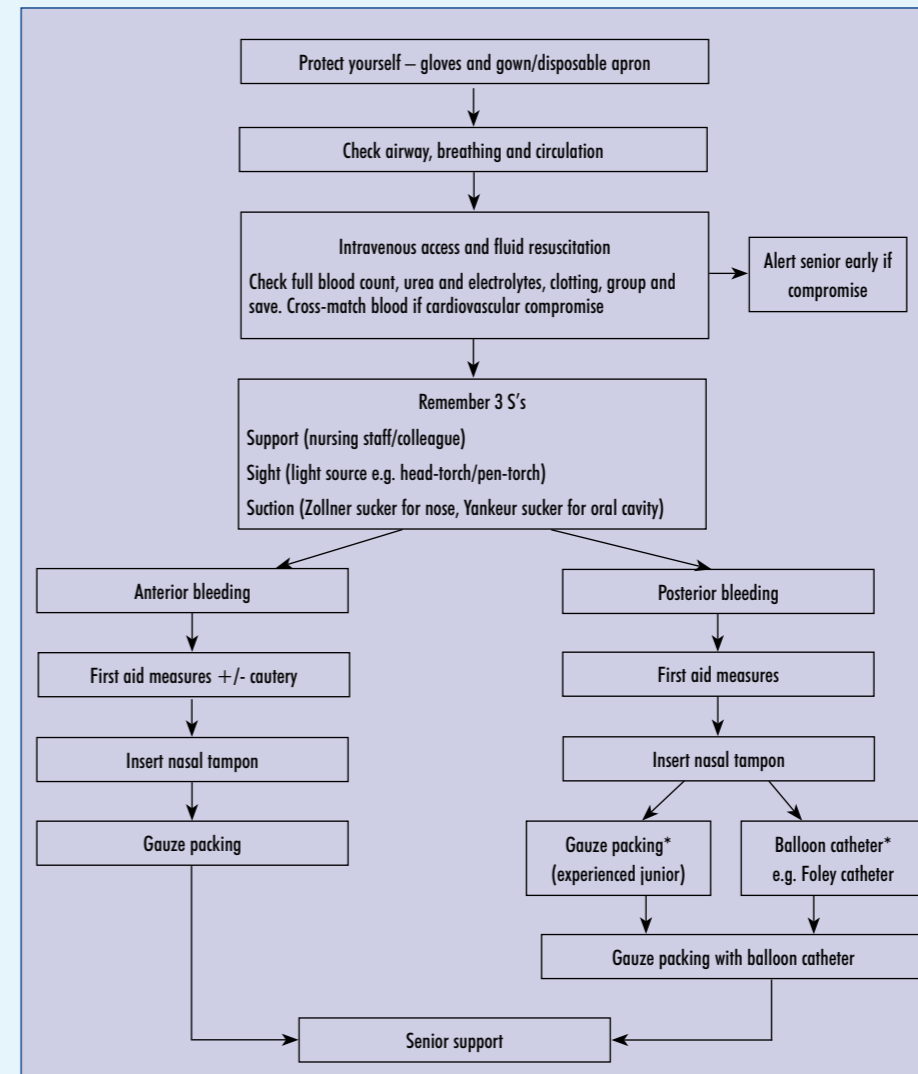


Figure 1. Management of epistaxis. *Achieving good posterior haemostasis with gauze packing can sometimes be difficult for the novice and so it is reasonable for the inexperienced doctor to position a balloon catheter initially and then to insert gauze proximally.

and consequent bleeding. There is a risk of black discoloration to the skin below the nostrils through nasal discharge after cautery. If this does occur patients are advised to clean the area immediately with a wet saline swab. The saline reacts with the silver nitrate to form a white precipitate and inactivates it.

How to insert a nasal tampon

Nasal tampon insertion is indicated if you are unable to stop anterior bleeding, despite simple first aid measures or

Figure 2. Basic ear, nose and throat equipment. From left to right: Yankeur sucker, Zollner sucker, silver nitrate stick, nasal tampon, Tilly's forceps, tongue depressor, thudicums speculum, umbilical cord clip, Foley catheter.

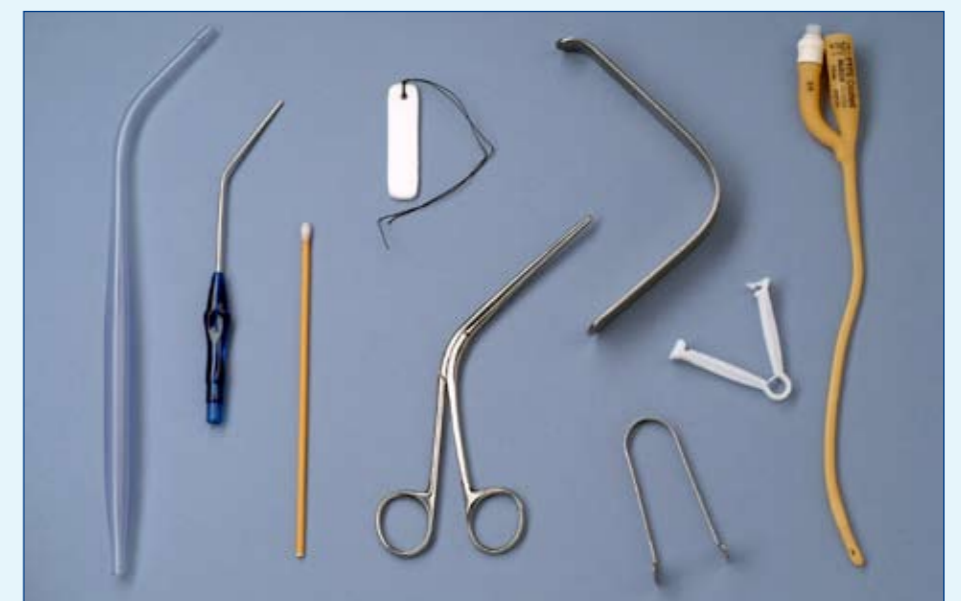

Figure 3. Nasal tampon before and after saline application.

cautery. It can also be used for posterior bleeding. The pack comprises a sponge which expands on absorption of liquid (Figure 3).

One should insert the nasal tampon in the space between the inferior turbinate and the nasal septum along the floor of the nose parallel to the septum. The anatomy is visualized better with a thudicums speculum. It is a common mistake to insert the tampon too laterally, medially or superiorly (Figure 4). This will not only restrict the insertion of the pack but will also cause increased discomfort to the patient and trauma to the nasal mucosa. The correct angle of insertion is shown in Figure 5. Naseptin or KY gel can be applied at the distal end and along the base of the nasal tampon to aid insertion.

Once in place the pack should expand as it is soaked with blood, but saline flush may be used to assist expansion. There is normally a suture string attached which can be taped to the side of the face

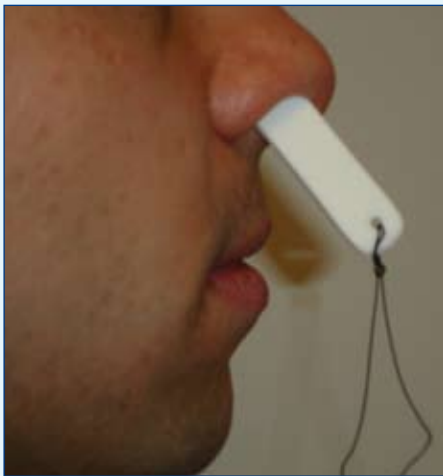

Figure 4. Incorrect angle of insertion of nasal tampon.

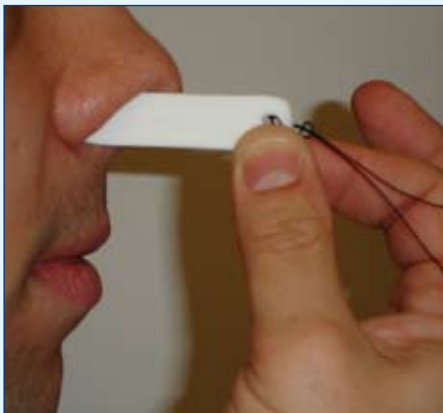

Figure 5. Correct angle of insertion of nasal tampon.

(Figure 6). This will prevent displacement of the pack into the oropharynx or airway. After packing, it is important to view the oropharynx to ensure that there is no active bleeding posteriorly (which may be present even if anterior bleeding appears to be controlled). If active bleeding posteriorly continues alternative packing should be considered.

Nasal packing should normally be removed after 24 hours. Any appropriate areas may be cauterized and antiseptic cream applied for a week as previously described.

How to insert ribbon or gauze

Ribbon or BIPP (bismuth iodoform paraffin paste) gauze insertion using Tilley's packing forceps (Figure 2) is indicated in cases when nasal tampon insertion has failed. An assistant is recommended to support the head during insertion. As with nasal tampon insertion, the thudicums

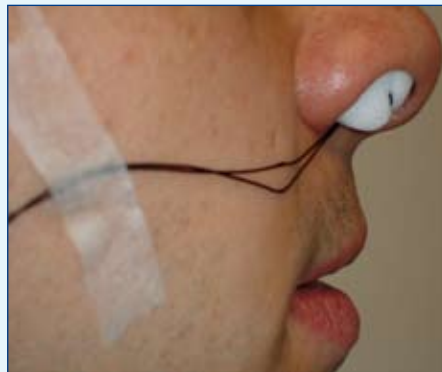

Figure 6. Nasal tampon inserted and secured.

speculum should be used to visualize the pertinent anatomy as previously described. The gauze should be unravelled completely and placed in a container just beneath the patient's chin so that it hangs tension-free. The gauze should be layered inside the nose. The initial passes of the pack should be inserted as posteriorly as possible. The BIPP can then be layered in smaller passes as the nose narrows superiorly.

It is not necessary to pack the contralateral nostril if there is no bleeding from that side. Contralateral packing may provide some additional pressure to curb ipsilateral bleeding. However, such packing may prove more difficult as the primary packing deflects the septum to the opposite side of the nose.

Insertion of Vaseline gauze packing requires a slight modification of technique. Vaseline gauze tends to stick to the inserting forceps. A more rapid action with smaller passes will allow the gauze to be inserted along the nasal floor without sticking to the forceps.

How to insert a Foley catheter

Foley catheter (Figure 2) insertion is indicated for posterior bleeding which has not been controlled with the previous techniques described. The combined action of packing inserted anteriorly with the

inflated balloon of the catheter occluding the nose posteriorly achieves haemostasis. A Foley catheter with a 10 ml balloon capacity is normally recommended.

The catheter should be inserted with direct visualization of the oropharynx. If the catheter is passed too distally and the balloon is inflated, there is a risk of airway obstruction. Once the tip of the catheter is visualized in the oropharynx it should be retracted a few centimetres and an assistant should inflate the balloon slowly with normal saline or water. Some clinicians suggest that using air to inflate the balloon may be less effective as air leak could deflate the balloon and result in further bleeding.

The catheter should be pulled tight against the back of the nose. The gauze may then be inserted anteriorly with an assistant holding the catheter in position. An umbilical cord clamp (Figure 2) should be used to secure the catheter and prevent posterior displacement into the airway. Gauze should be placed between the clamp and the nostril to prevent pressure necrosis of the underlying skin and cartilage.

Continued bleeding

If bleeding persists despite all the above measures described urgent senior ENT help must be sought.

It is likely that these patients will require insertion of post-nasal pack under general anaesthetic or surgery (endoscopic or open approach). **BJHM**

Conflict of interest: none.

Further reading

Corbridge R, Hellier W (1998) *Essential ENT Practice. A Clinical Text*. Hodder Arnold Publishing, London
 Dhillon R, East C (1999) *Ear, Nose and Throat and Head and Neck Surgery*. 2nd edn. Churchill Livingstone, Edinburgh
 O'Donoghue GM, Bates GJ, Narula AA (1992) *Clinical ENT An Illustrated Textbook*. Oxford University Press, Oxford

KEY POINTS

- Epistaxis may be a life-threatening emergency.
- Take a stepwise approach starting with simple conservative measures and methodically work your way through the active interventions described.
- Make sure that you have an assistant.
- Seek senior support at an early stage if required.