

Breast abscess

Introduction

The management of breast abscesses has continued to evolve over the last decade despite its decreasing frequency in developed countries. A breast abscess can occur at any age although is seen most commonly in adult premenopausal women. It may be difficult but should be distinguished from mastitis where there is inflammation without pus. Appropriate management is needed to provide symptom control and minimize long-term complications including chronic infection, recurrence and scarring.

Classification

Abscesses may be primary which are usually divided into neonatal, lactational and non-lactational or secondary to an underlying skin disorder such as sebaceous cyst or hidradenitis suppurativa (Table 1).

Clinical features

Erythema, pain, swelling and tenderness of the breast are usually present (Figure 1). There may be a fluctuant mass with overlying shiny red skin. Axillary nodes are unusual. Pyrexia and leucocytosis are relatively common.

Management

All patients should be offered analgesia. The abscess should then be classified to decide the optimal treatment. Pus can be aspirated

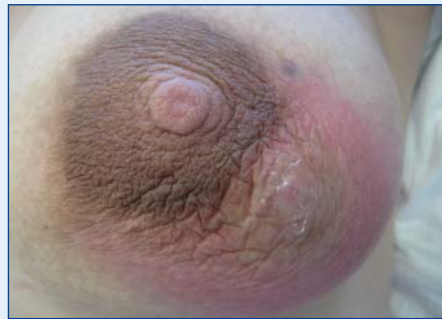

Figure 1. Central non-lactating abscess.

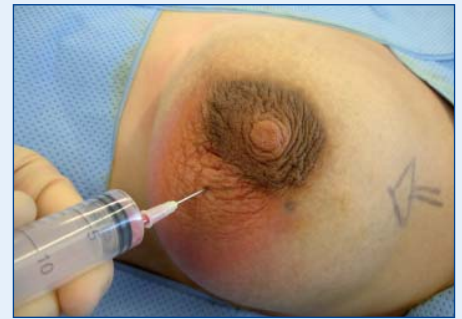

Figure 2. Pus being aspirated from abscess.

(Figure 2) using a white 19-gauge needle, either freehand or under ultrasound control if the facility exists, and sent for microbiological analysis. If no pus is aspirated, the aspirate should be sent for cytology. A management algorithm is shown in Figure 3.

If the skin overlying the abscess cavity is thinned or necrotic, a mini incision and drainage procedure can be carried out. Local anaesthetic cream should be applied for approximately 45 minutes to 1 hour before the procedure. If the skin is necrotic,

the skin can be excised without the prior application of anaesthetic cream. The cavity should then be irrigated with saline. Standard incision and drainage under general anaesthetic rarely needs to be carried out and should be reserved for children and those unsuitable for local anaesthetic procedures.

The patient does not usually require hospital admission and should be discharged with appropriate antibiotics and followed up in the breast clinic in the next 2–3 days,

Figure 3. Management protocol for breast abscess treatment. * If allergic to penicillin use alternative antibiotics.

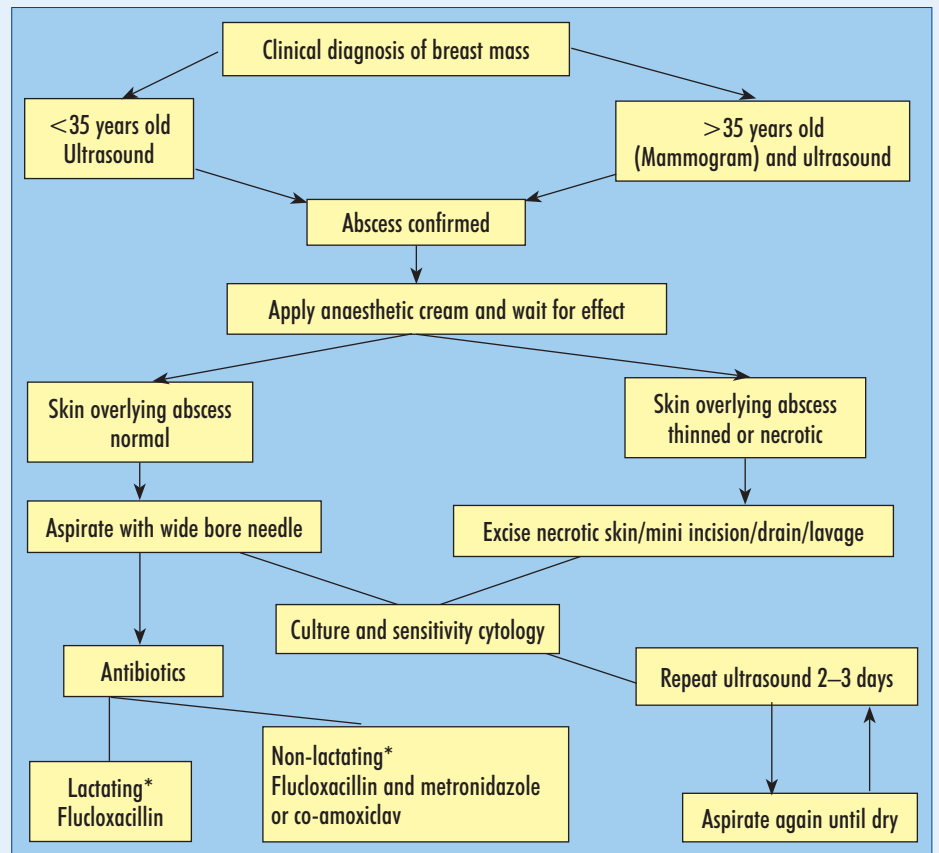


Table 1. Classification of breast abscess

Neonatal abscess
Lactating abscess
Central/periareolar non-lactating abscess
Peripheral non-lactating abscess
Primary cutaneous abscess

Mr Avi Agrawal is Consultant Surgeon in the Breast Unit, Portsmouth NHS Hospitals, Portsmouth and Mr Mark Kissin is Consultant Surgeon in the Breast Unit, The Royal Surrey County Hospital, Guildford, Surrey GU2 7XX

Correspondence to: Mr M Kissin

to ensure adequate resolution of the abscess, or for repeat aspiration. This process may involve the patient returning to the clinic on two or three separate occasions.

Other newer described techniques used to drain breast abscesses include injecting local anaesthetic into the abscess cavity to dilute the pus and alternately infusing local anaesthetic and aspirating the abscess to dryness. The proposed advantage is that it relieves pain and allows aspiration even when the pus is viscous. This needs repeating every 2–3 days until no pus is aspirated.

A mammotome is a handheld vacuum-assisted core biopsy device with a suction mode and has also been used to aspirate thick pus and debris from an abscess cavity, particularly after a non-satisfactory outcome with needle aspiration. Advantages include concurrent biopsy and the decreased need for repeat aspiration.

Instillation of antibiotic and lockable irrigating catheters into the abscess cavity has also been described.

Most studies comparing aspiration with or without antibiotics and incision and drainage have been uncontrolled description of case series with small numbers. There have been no recorded large randomized controlled trials. However, the general consensus from breast surgeons seems to be that aspiration of breast abscesses is the treatment of choice, with successful outcome more likely for smaller abscesses with lower recurrence rates.

Neonatal abscess

The breast bud is enlarged in the first few weeks of life when infection is most common. The neonate may be severely ill. *Staphylococcus aureus* and occasionally *Escherichia coli* are the responsible organisms. Antibiotics should be given and the preferential placement of any incision to drain pus should be peripheral as possible to avoid damaging the breast bud.

Lactating abscess

These are usually caused by *Staph. aureus* but can also be caused by *Staph. epidermidis* and streptococci. There are usually abrasions or cracks in the nipple. Organisms that enter the breast multiply in areas that are draining poorly which contain stagnant milk. It is most commonly seen in the first month after delivery but can also develop during weaning.

It has been common in the past for women with lactating breast infection to stop breast-feeding completely or to only breast feed from the normal side. Patients should not be discouraged from breast-feeding as this provides effective mild drainage of the breasts and neither the bacteria or certain antibiotics including flucloxacillin, erythromycin and co-amoxiclav within milk are harmful to the infant. Tetracyclines and ciprofloxacin can enter the milk and be harmful and should be avoided. The infant should be transferred to bottle-feeding if the mother finds continued breast-feeding too painful.

Central or periareolar non-lactating abscess

This is usually seen in women in their mid-30s and arises as a result of periductal mastitis, a condition where there is inflammation around non-dilated subareolar breast ducts, almost exclusively in smokers. It has been suggested that toxins in cigarette smoke damage the wall of these ducts, which then get secondarily infected. Clinically as well as periareolar inflammation, there may be nipple discharge or retraction. *Staph. aureus* is the commonest infecting organism although anaerobic bacteria are often involved as well.

There is a reasonably high recurrence rate and up to a third of patients develop a mammary duct fistula after drainage of a non-lactating breast abscess, as the underlying diseased ducts have not been removed with aspiration or incision and drainage alone. With recurrent episodes, the subareolar ducts should be excised with perioperative antibiotic cover.

Peripheral non-lactating abscess

Peripheral breast abscesses are less common than periareolar abscesses associated with periductal mastitis. These may be associated with diseases such as diabetes, rheumatoid arthritis, granulomatous lobular mastitis, trauma and steroid treatment. However, some develop in the absence of any predisposing factor and a suspicion for underlying malignancy should be held.

Primary cutaneous abscess

These abscesses arise from a primary infection of the skin of the breast. Primary skin infections tend to occur in women who have poor hygiene, are overweight and have

large breasts. Recent radiotherapy or surgery may also be causative. Sebaceous cysts in the breast skin can also get infected as can hidradenitis suppurativa. Management should include treating the condition as one would if it were anywhere else on the body.

Conclusions

A breast abscess is a serious condition where prompt treatment is important to prevent further loss of normal tissue. Repeated aspiration with concurrent use of antibiotics can be carried out effectively in the majority of cases, with few breast abscesses requiring standard incision and drainage under general anaesthesia. It is important to ensure the cooperation of a skilled breast radiologist in the management of breast abscesses. **BJHM**

Conflict of interest: none.

Further reading

- Dixon JM (2000) Breast infection. In: Dixon JM, ed. *ABC of Breast Diseases*. BMJ Publishing Group, London: 21–5
- Leborgne F, Leborgne F (2003) Treatment of breast abscesses with sonographically guided aspiration, irrigation and instillation of antibiotics. *Am J Roentgenol* **181**: 1089–91
- Ullrich D, Nyman MK, Carlson RA (2004) Breast abscess in lactating women: US-guided treatment. *Radiology* **232**: 904–9
- Varey AH, Shere MH, Cawthorn SJ (2005) Treatment of loculated lactational breast abscess with a vacuum biopsy system. *Br J Surg* **92**: 1225–6

KEY POINTS

- Early administration of antibiotics can prevent abscess formation.
- Repeated aspiration of breast abscesses with antibiotics is increasingly the preferred treatment option over traditional incision and drainage.
- The majority of breast abscesses can be treated without a general anaesthetic.
- Ultrasound can both confirm the presence of pus and allow a targeted percutaneous drainage.
- A mammogram should be carried out, in women aged over 35 years, following resolution of non-lactational abscesses, to exclude the rare possibility of an infected area of comedo necrosis associated with ductal carcinoma in situ.
- Breast cancer should be excluded, in presence of continued inflammation or an associated mass lesion, after appropriate treatment of breast abscess.