

The applied anatomy of examination of the knee

Introduction

Injuries of the knee are common. Accurate diagnosis of the precise site of structural damage entirely depends on a clear knowledge of its anatomy.

The knee is a hinge joint, made up of the articulations between the femoral and tibial condyles and between the patella and the patellar surface of the femur (*Figure 1*). The capsule of the joint is attached to the margins of these articular surfaces, but it communicates superiorly with the suprapatellar bursa, which extends a hands-breadth above the patella between the lower femoral shaft and the quadriceps muscle. An effusion of blood or serous exudate following trauma produces a characteristic swelling above the patella; often the diagnosis can be made at a glance.

The joint capsule also communicates posteriorly with a bursa under the the medial head of gastrocnemius and often, through it, with a bursa under the tendon of semitendinosus – a common site for cyst formation.

Anteriorly, the capsule is powerfully strengthened by the ligamentum patellae and, on either side, by the medial and lateral collateral ligaments. The latter passes to the head of the fibula, which is easily felt, and therefore lies free from the capsule (*Figure 1*).

Within the knee joint are a number of important structures (*Figures 1* and *2*). The cruciate ligaments are extremely strong bands between the tibia and femur. They arise from the anterior and posterior intercondylar areas of the superior aspect of the tibia, taking their names from their tibial origins, and pass obliquely upwards to attach onto the intercondylar notch of the femur. The function of the anterior cruciate is to resist forward movement of the tibia on the femur and it becomes taut in forward displacement of the knee. It also resists rotational strain. The posterior cruciate resists backward displacement of the tibia (*Figure 3*).

Professor Harold Ellis is Clinical Anatomist, Guy's, King's and St Thomas' School of Biomedical Science, London SE1 1UL

The semilunar cartilages (menisci) are crescent-shaped and are triangular in cross section, the medial being larger and less curved than the lateral (*Figure 2*). They

Figure 1. The knee, anterior view. The knee is flexed and the patella has been turned downwards.

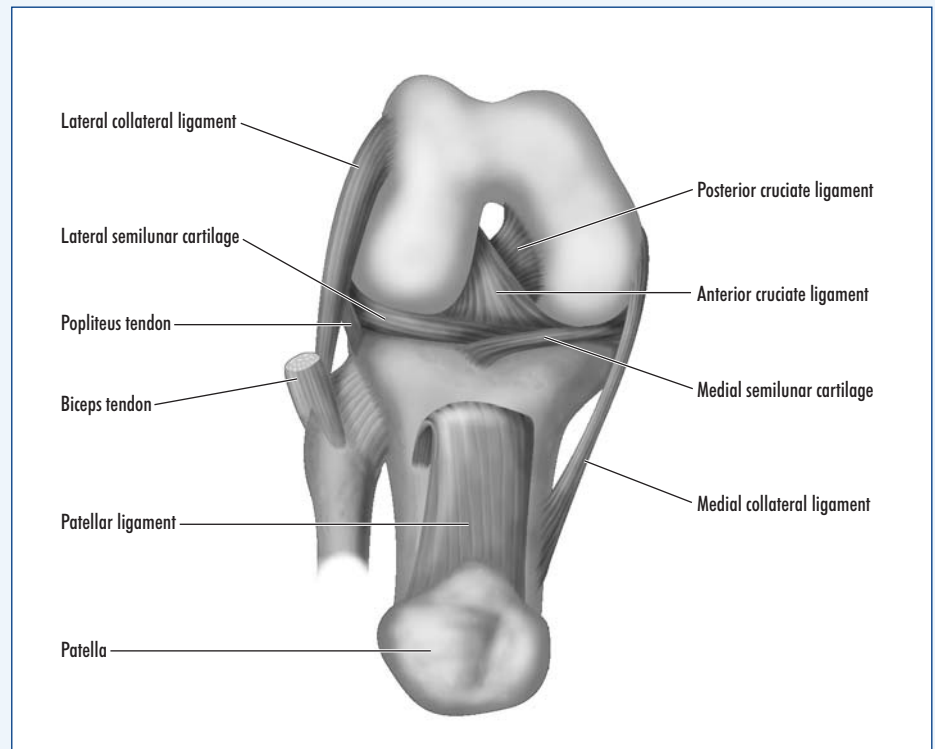
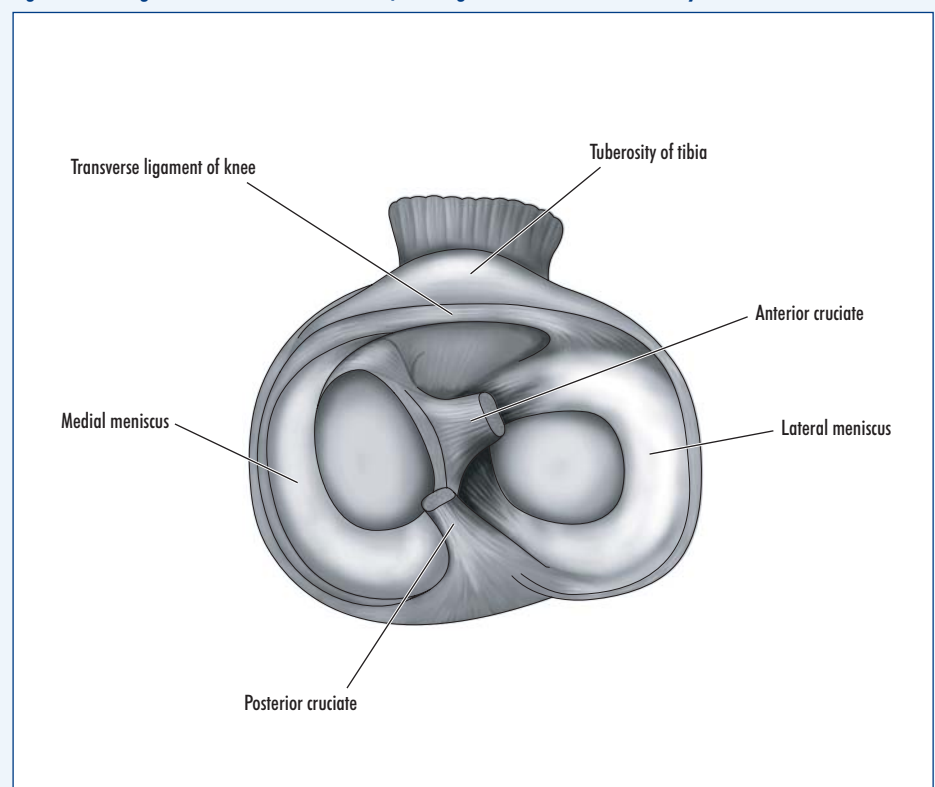


Figure 2. The right knee in transverse section, looking down onto the tibial condyles.



are attached by their tips to the tibial intercondylar area and by their periphery to the joint capsule, although the lateral cartilage is only loosely adherent, and therefore less likely to be trapped and torn in rotational injuries of the knee than the medial cartilage.

These cartilages deepen, but only to a negligible extent, the articulations between the femoral and tibial condyles. Their function is probably to act as shock absorbers. However, if both cartilages are removed, the knee can regain complete functional efficiency.

An infrapatellar pad of fat fills the space between the patellar ligament and the femoral intercondylar notch. The synovium which covers this pad projects into the joint as the alar fold on each side.

The main movements of the knee are flexion and extension, but note on yourself when standing that, when the knee is flexed, some degree of rotation is possible. In full extension the medial condyle of the tibia, being larger than the lateral, rides forwards on the medial femoral condyle, thus 'screwing' the knee firmly together; at the same time, the collateral ligaments are at maximum tension. The first step in flexing the knee is 'unscrewing', or internal rotation. This is brought about by popliteus, which arises from the lateral side of the lateral femoral condyle, emerges from the joint capsule posteriorly and is inserted into the back of the upper tibia.

When thinking of soft tissue injuries of the knee, consider the three Cs that may be damaged: Collateral ligaments, Cruciates and Cartilages.

Collateral ligaments

The collateral ligaments are taut in full extension and are, therefore, only liable to be torn in violent abduction or adduction injury to the fully extended knee. If ruptured, the extended knee can be rocked away from the affected side.

Cruciate ligaments

The cruciate ligaments (*Figure 3*) may also be damaged in severe abduction or adduction injuries. The anterior cruciate may also be torn in violent hyperextension of the knee. Since it also resists rotation, it may be damaged, together with the medial

cartilage, in severe twisting injuries of the knee. The posterior cruciate may be torn in posterior dislocation.

To test, the knee is placed in the flexed position. If both cruciates are torn, unnatural antero-posterior mobility of the knee can be demonstrated. If the anterior cruciate alone is injured, there is increased forward mobility; if the posterior is alone torn, there is increased backward mobility.

Cartilages

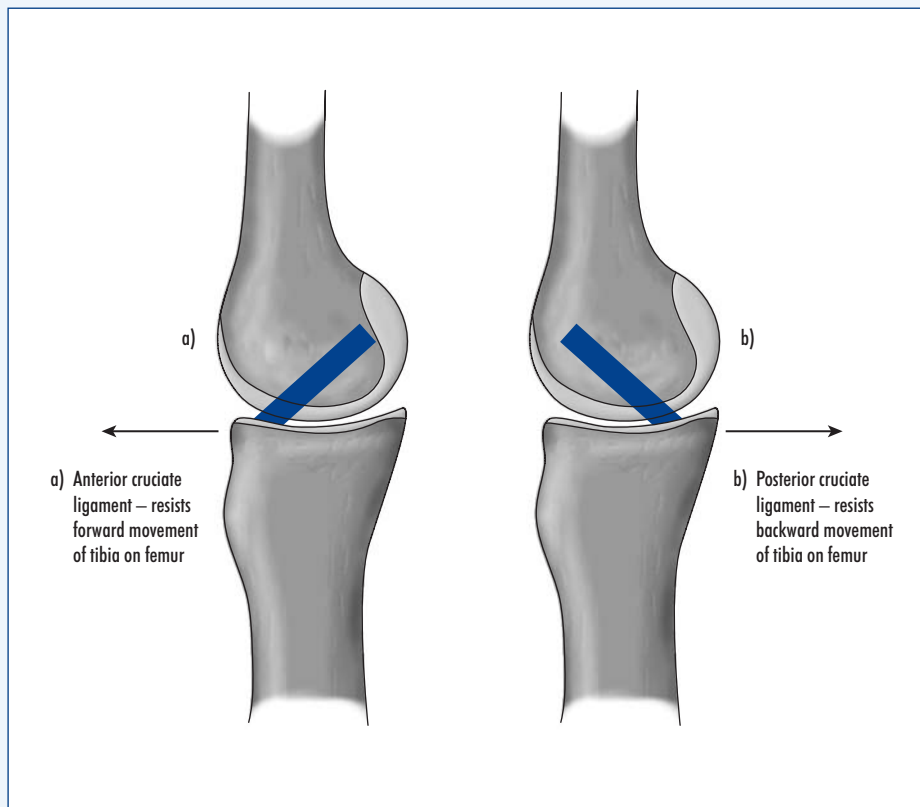
The semilunar cartilages can only tear when the knee is flexed and is thus able to rotate. If the flexed knee is abducted and externally rotated, the medial cartilage

may be drawn between, and then split by, the grinding surfaces of the medial condyles of the tibia and femur. This occurs typically when a footballer twists his flexed knee in a tackle. A severe adduction and internal rotational strain may similarly tear the lateral cartilage, but this is a less common injury.

The knee 'locks' in this type of injury because the torn piece of cartilage lodges between the condyles and prevents full extension of the knee. **BJHM**

Figures 1–3 are reproduced from Ellis H (2006) *Clinical Anatomy*. 11th edn. Blackwells, Oxford
Conflict of interest: none.

Figure 3. The action of the cruciate ligaments. a. Anterior cruciate ligament – resists forward movement of the tibia on the femur. b. Posterior cruciate ligament – resists backward movement of the tibia on the femur.



KEY POINTS

- The knee is a hinge joint, but allows minimal rotation when flexed.
- Important and common injuries involve: the medial and lateral collateral ligaments, damaged in the fully extended knee; the lateral and, more commonly the medial meniscus, damaged in torsional injuries of the flexed knee; and the cruciate ligaments.
- A knowledge of knee anatomy is essential in effective examination of this joint.