

BRITISH JOURNAL OF  
**HOSPITAL  
MEDICINE**

**MMC**  
Modernising Medical Careers

**MODERNISING  
MEDICAL CAREERS**

**Abdominal injuries** **M78**

*Ross Davenport, Mike Walsh, Nigel Tai*

**The clinical anatomy of  
lumbar puncture** **M82**

*Harold Ellis*

**Perish or publish: how to  
secure your first publication** **M86**

*Gwyn S Williams, Talvinder Singh*

**Team working: a guide for  
the foundation year doctor** **M88**

*Deepali Trivedi, Aveen Mitra, Rachel Hooke*

**Forearm fractures** **M90**

*RV Patel, FS Haddad*

**IN NEXT MONTH'S  
MMC SUPPLEMENT**

**Clinical anatomy of  
pericardiocentesis**

**Breast abscess**

**New ways of working: a guide for  
the foundation year doctor**

**Learning portfolio:  
how to get it right**

In association with



**WESLEYAN  
MEDICAL SICKNESS**

# Abdominal injuries

## Introduction

This article will give an overview of abdominal trauma and provide a broad framework for the initial management of injuries to the abdomen. Abdominal injury carries a high morbidity and mortality in all age groups, therefore a sound understanding of the patterns of injury, examination, investigations and resuscitation procedures is vital to the trauma surgeon's armamentarium.

## Mechanism of injury

Abdominal trauma can be categorized as either blunt or penetrating, the former presenting a greater diagnostic challenge as there may be few or no external signs.

## Blunt trauma

Road traffic accidents are the commonest cause of blunt injuries with falls from height, crush injuries and assault with blunt weapons comprising the remainder. Deceleration, shearing and direct compression are the main forces involved in blunt trauma and one can predict, and therefore must maintain a high degree of suspicion for, specific patterns of injury associated with the different mechanisms of injury. For example, rapid deceleration from either a fall or road traffic accident can cause rupture of the duodenum or pancreatic injury as these structures are partially fixed in the retroperitoneum. It is important to note that blunt abdominal trauma is often a feature of polytrauma which may complicate initial assessment.

## Penetrating trauma

Penetrating wounds are caused by low velocity projectiles (knives, shotgun pellets and hand gun bullets) and high velocity projectiles (rifle bullets, high energy fragments from bombs and blasts). The posi-

tion of the patient when shot or stabbed and the length of the blade are useful pieces of information but peritoneal penetration can be difficult to assess and indeed serious visceral injury may present with minimal physical signs. In addition, bullets follow the path of least resistance meaning entry and exit wounds are not always linearly related. One must always consider the possibility that other body cavities may have been damaged.

## Assessment and examination

Abdominal injuries can be considered as any that occur anteriorly below the nipples, above the groin skin crease and between the posterior axillary lines, and posteriorly from the tips of scapulas to the inferior gluteal folds.

The initial assessment and management of all injured patients should start with the primary survey and follow the principles of Advanced Trauma and Life Support (American College of Surgeons, 2004), namely airway with cervical spine control, breathing, circulation and neurological status. A full history of the events from witnesses and/or paramedics and information from the scene are valuable in ascertaining an injury pattern. Importantly, simultaneous evaluation, investigation and resuscitation must run in parallel to rapidly assess and treat the patient who may well be in significant haemorrhagic shock. In such cases it is vital to rapidly establish the primary source of haemorrhage, i.e. chest, abdomen, pelvis or externally and intervene decisively.

## Clinical examination

Be systematic and fully expose the abdomen paying careful attention to the flanks, back, buttocks and perineum looking for any abrasions, lacerations, haematoma and entry or exit wounds. The signs of peritoneal irritation as a result of the presence of blood or rupture of a hollow viscus may be slow to develop and caution must be used in patients with altered neurological status, lower chest injuries and following endotracheal intubation. Retroperitoneal haemorrhage from renal or vascular injury can often be difficult to detect. Certain signs may heighten the need for further investi-

**Mr Ross Davenport** is Trauma and Vascular Fellow, **Mr Mike Walsh** is Consultant Trauma and Vascular Surgeon, Clinical Lead for Surgery and **Major Nigel Tai** is Consultant Trauma and Vascular Surgeon, Royal Army Medical Corps, Trauma Service, Royal London Hospital, London E1 1BB

Correspondence to: Mr R Davenport

gation, for example the seat belt sign (*Figure 1*), which suggests intra-abdominal injuries are more likely to be present.

Other signs suggestive of injury include, lower limb fractures, haematuria, blood in the nasogastric tube, blood on digital rectal or vaginal exam, and diminished or absent lower extremity pulses. It is important to note, however, that clinical examination is unreliable in approximately 50% of blunt trauma cases.

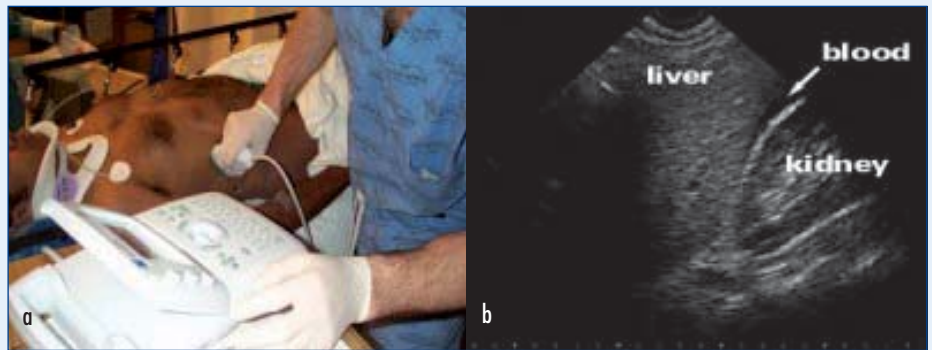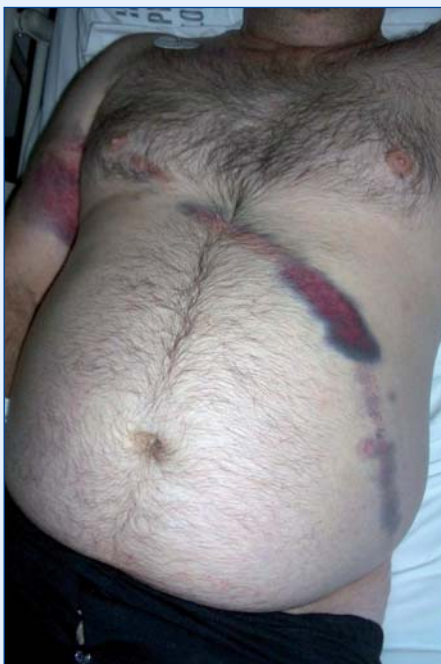Pelvic fracture should be assessed radiographically and not by 'springing the pelvis' which has a low yield for diagnosis and may actually dislodge a clot from the pelvis causing life-threatening haemorrhage. If pelvic injury is suspected the application of a pelvic binder should be applied until imaging has been obtained.

## Investigations

### The basics

As part of the primary survey, radiographical imaging of the chest and pelvis must be performed. Radiological clearance of the cervical spine can be delayed if the patient is cardiovascularly unstable. Large bore venous access must be secured and baseline blood tests requested: full blood count, cross-match, urea and electrolytes, and amylase. A urethral urinary catheter should be inserted unless there are clinical signs of urethral injury, i.e. blood at the external meatus, high riding prostate, scro-

**Figure 1. Seat belt sign.**



**Figure 2. Focused Assessment with Sonography in Trauma (FAST).** a. Probe position for left upper quadrant and the hepatorenal view. b. Blood shows as a hypoechoic black stripe on ultrasound, in this case between the capsule of the liver and the fatty fascia of the kidney.

tal or perineal haematoma. Urinalysis should be performed on everyone including beta-human chorionic gonadotropin (hCG) in females.

### Focused assessment with sonography in trauma

The polytrauma patient in haemorrhagic shock presents a challenge to the surgeon in knowing where to direct their efforts to arrest the source of bleeding. Focused assessment with sonography in trauma (FAST) is a simple non-invasive investigation which can be carried out by appropriately trained non-radiologists at the bedside in the resuscitation room (Thomas et al, 1997). For sonography to be a useful tool in the initial assessment of the injured patient it must be immediately available to the trauma team.

The purpose of FAST is to make a timely diagnosis of potentially life-threatening haemorrhage and to guide the need for transfer to the operating room, computed tomography (CT) scanner or angiography suite. It is an abbreviated ultrasound examination and directed solely at identifying the presence of free fluid using four windows: perisplenic, perihepatic (*Figure 2*), pelvic and pericardial – it is not a reliable modality for identifying specific injuries (Rozycki et al, 2005).

For the hypovolaemic patient FAST has a high degree of accuracy in determining the need for emergency laparotomy (Wherret et al, 1996). However, there is a significant false-negative rate as blood may take time to appear in identifiable quantities although if clinical suspicion remains high, FAST can be repeated to check for free intraperitoneal fluid. Images in obese patients or in the presence of surgical

emphysema are often limited and not reliable. In addition, pelvic fractures can cause free fluid to appear in the pelvis.

### Diagnostic peritoneal lavage

The advent of FAST has largely replaced diagnostic peritoneal lavage (DPL) as an investigational tool. Its use is mainly confined to areas where CT or ultrasound are not available but laboratory facilities must be on hand to analyse the peritoneal fluid.

### CT scanning

The CT scanner is no place for the hypotensive trauma patient and therefore is contraindicated when there is an obvious need for laparotomy. In the haemodynamically normal patient, CT with intravenous contrast is excellent at assessing the degree of solid organ injury (liver, kidney, spleen) and retroperitoneal injury (Shanmuganathan, 2004). It is therefore a useful tool in guiding non-operative management of solid organ injuries (Demetriades et al, 2006).

In the absence of solid organ injury, free fluid on CT scan indicates a hollow viscous injury until proven otherwise. It is important to note that this investigation may miss these types of injury (especially small bowel) as well as diaphragmatic injuries.

### Management

An increasing number of patients with abdominal trauma can be managed non-operatively. Nevertheless, those displaying signs of haemodynamic compromise or peritonitis will almost certainly need some form of intervention. The key questions one needs to ask and how the answers form a coherent treatment strategy are summarized in *Table 1*.

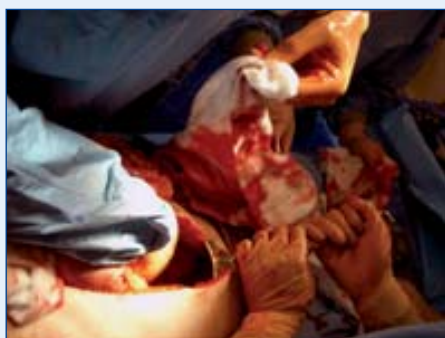<b>Table 1. Management strategy for abdominal trauma</b>		
<b>Key questions</b>	<b>Key information</b>	<b>Key interventions</b>
Is there intraperitoneal bleeding and is it ongoing?	Mechanism of injury Clinical evidence of shock Response to initial resuscitation FAST scan CT scan (if stable)	Active bleeding → Laparotomy No active bleeding* → Close observations
Is there intraperitoneal or retroperitoneal contamination?	Mechanism of injury Clinical examination CT scan (if stable) Amylase (for pancreatic injury)	Hollow organ injury likely → laparotomy Equivocal evidence → Close observation on high dependency unit + laparotomy if: • Peritonitis • Fever • Raised white cell count
Is there retroperitoneal bleeding and is it ongoing?	Mechanism of injury Clinical evidence of pelvic fracture and X-ray Evidence of shock Response to initial resuscitation FAST scan (to rule out intraperitoneal cause) CT scan (if stable)	Evidence of pelvic fracture and shock → Pelvic splint Proceed to angiography suite for possible embolization if no free fluid on FAST scan Involve orthopaedic surgeons early for definite fixation

\*No ongoing fluid requirements, normal pulse and blood pressure. No drop in haemoglobin levels. No blush or active bleed on CT scan. CT = Computed Tomography; FAST = Focused Assessment with Sonography in Trauma

**Permissive hypotension**

For many years the concept of ‘hypotensive resuscitation’ has been well understood in the treatment of traumatic vascular injury and rupture of abdominal aortic aneurysms. Permissive hypotension describes the approach in which the systolic blood pressure is deliberately kept below the normal levels seen in health, with the aim of maintaining vital organ perfusion, in particular cerebral function, without exacerbating haemorrhage. Pressures greater than 80–90 mmHg are likely to dislodge a clot and lead to continued haemorrhage (Mattox, 2003). Hyper-resuscitated patients are more likely to re-bleed and go on to develop a coagulopathy leading to further problems in haemorrhage control.

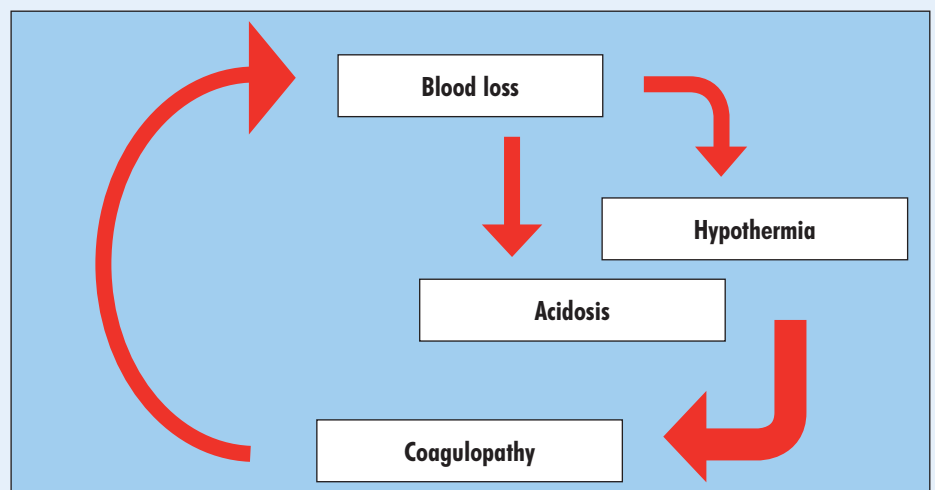
**Figure 3. Packing of the abdomen to arrest haemorrhage.**



**Trauma laparotomy**

The treatment of bleeding is to stop the bleeding. It follows therefore that the exsanguinating patient must be taken immediately to the operating theatre for emergency laparotomy. They should be prepped from neck to knees with plenty of large abdominal packs available. A midline incision from xiphisternum to pubis is performed to allow adequate exposure. Four quadrant packing (Figure 3) is used to achieve immediate control

**Figure 4. The bloody vicious cycle: blood loss, dilutional coagulopathy, hypothermia and acidosis all occur after severe haemorrhage. Massive transfusion of blood and clotting products can compound the metabolic failure leading to the so-called ‘bloody vicious circle’.**



before a thorough inspection of the abdominal cavity is made to identify and repair any obvious vascular injuries. Solid organ bleeding can often be controlled with packing alone.

**Damage control**

The severely shocked patient will undoubtedly require large volumes of blood and blood products to replace the massive losses. This is not without detriment and can give rise to a state of traumatic coagulopathy which if not corrected can be lethal (Figure 4).

In order to limit the extent of the metabolic derangement, the concept of ‘damage control’ surgery must be used. First the trauma surgeon must quickly identify the need for damage control, namely, haemodynamic instability, complex abdominal injury or severe metabolic derangement. Damage control is then defined by an abbreviated laparotomy consisting of rapid control of haemorrhage and contamination, temporary closure, resuscitation to normal physiology in an intensive care unit before return to theatre for definitive repair (Table 2). Studies have shown significant improvements in survival rate with damage control when compared to definitive laparotomy (Rotondo et al, 1993; Hirshberg and Mattox, 1995).

**Angiography**

Interventional radiology certainly has an expanding role in the management of blunt and penetrating trauma through the

**Table 2. The four phases of damage control surgery – the primary aim in the early stages (parts I and II) is the restoration of normal physiology rather than reconstruction of normal anatomy**

<b>Damage control 0: 'Ground zero' recognition</b>	Pre-hospital triage and rapid transport
	Resuscitation
	Oxygen, blood, decision
<b>Part I: Operating theatre</b>	Control haemorrhage
	Control contamination
	Intra-abdominal packing
	Temporary closure – laparostomy
<b>Part II: Intensive care unit</b>	Rewarming
	Correct coagulopathy
	Maximize haemodynamics
	Ventilatory support
	Re-examination
<b>Part III: Operating theatre</b>	Pack removal
	Definitive repairs
	Closure

From Johnson et al (2001)

methods of angio-embolization and endovascular stenting. Hypotensive patients with evidence of a pelvic fracture and no free fluid on FAST should undergo early angiography to assess bleeding from the pelvic vasculature with embolization of any arterial injury. Haemodynamically stable patients with evidence of ongoing bleeding, on CT or angiography, at the site of liver or splenic injury can also be managed using this approach (Figure 5). It must be stressed though that shocked patients with free fluid on FAST need to be managed surgically, i.e. emergency laparotomy, to arrest the source of haemorrhage.

**Non-operative management**

Regular re-examination and close observation in an appropriate unit to elicit the signs of intra-abdominal bleeding is fundamental to this management strategy (Knudson and Maull, 1999). Suitable patients are those with:

- Solid organ injury and no sign of continued bleeding, e.g. splenic laceration
- Penetrating injuries where peritoneal breach is suspected but the patient has only localized tenderness.

The important caveats to the above are cardiovascular stability and a CT scan which has demonstrated a low likelihood of hollow organ damage. **BJHM**

**Figure 5. Liver injury with evidence of active bleeding.**

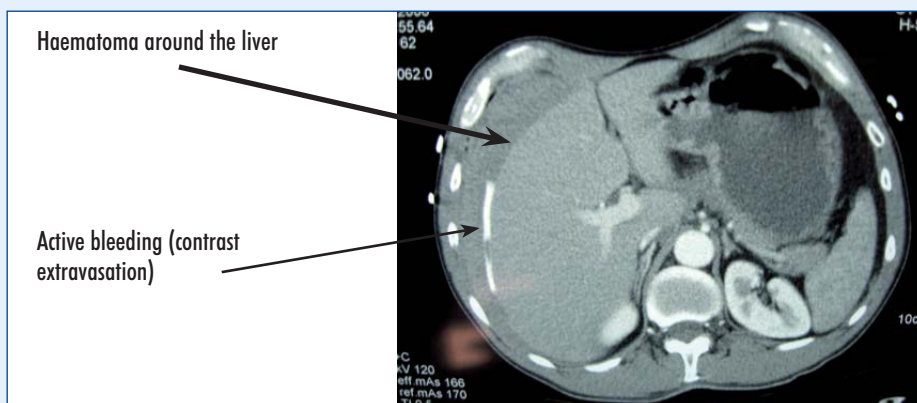


Figure 2 is reproduced courtesy of K Brobi ([www.trauma.org](http://www.trauma.org)).

Conflict of interest: none.

American College of Surgeons (2004) *Advanced Trauma Life Support Program for Doctors*: TLS, 7th edn. Chicago, IL

Demetriades D, Hadjizacharia P, Constantinou C (2006) Selective nonoperative management of penetrating abdominal solid organ injuries. *Ann Surg* **244**(4): 620–8

Hirshberg A, Mattox KL (1995) Planned reoperation for severe trauma. *Ann Surg* **222**: 3–8

Johnson JW, Gracias VH, Schwab CW et al (2001) Evolution in damage control for exsanguinating penetrating abdominal injury. *J Trauma* **51**(2): 261–71

Knudson MM, Maull KI (1999) Nonoperative management of solid organ injuries. Past, present, and future. *Surg Clin North Am* **79**(6): 1357–71

Mattox K (2003) Permissive hypotension – online editorial (Jan [www.trauma.org](http://www.trauma.org) 8:1

Rotondo MF, Schwab CW, McGonigal MD et al (1993) Damage Control - an approach for improved survival in exsanguinating penetrating abdominal injury. *J Trauma* **35**(3): 375–82

Rozycki GS, Knudson MM, Shackford SR, Dicker R (2005) Surgeon-performed bedside organ assessment with sonography after trauma (BOAST): a pilot study from the WTA Multicenter Group. *J Trauma* **59**(6): 1354–64

Shanmuganathan K (2004) Multi-detector row CT imaging of blunt abdominal trauma. *Semin Ultrasound CT MR* **25**(2): 180–204

Thomas B, Falcone RE, Vasquez D et al (1997) Ultrasound evaluation of blunt abdominal trauma: program implementation, initial experience, and learning curve. *J Trauma* **42**(3): 384–90

Wherret LJ, Boulanger BR, McLellan BA et al (1996) Hypotension after blunt abdominal trauma: the role of emergent abdominal sonography in surgical triage. *J Trauma* **41**(5): 815–20

**KEY POINTS**

- The surgeon must maintain a high index for suspicion for intra-abdominal injuries on the basis of likely injury patterns.
- Clinical examination may be normal and therefore unreliable despite injury to abdominal viscera.
- Focused Assessment with Sonography in Trauma is an excellent adjunct to the assessment of the hypovolaemic trauma patient.
- The computed tomography scanner is no place for the exsanguinating patient.
- Permissive hypotension is likely to preserve clots already formed at the site of injury and reduce further haemorrhage.
- Damage control surgery helps limit metabolic derangement and improves survival.
- Both non-operative and angiographic management has a role in the treatment of solid organ injury.