

The clinical anatomy of lumbar puncture

Lumbar puncture is a commonly performed clinical procedure. It may be used for diagnosis (meningitis, encephalitis, subarachnoid haemorrhage) and/or for therapeutics (introduction of antibiotics, spinal anaesthesia).

Its anatomical basis lies in the fact that the spinal cord terminates distally within the dural sac well above the level that the needle is inserted into the theca and on the anatomy of the spines of the lumbar vertebrae and their ligamentous connections.

The termination of the spinal cord

The spinal cord in the adult is 45 cm (18 inches) long, a measurement it shares with the length of the femur and of the vas deferens and with the distance from the lips to the oesophago-gastric junction. Up to the third month of fetal life, the cord extends the length of the vertebral canal. The vertebrae then grow considerably faster than the cord, so that, at birth, the cord terminates at the lower end of the third lumbar vertebra and, in the adult, on average, at the disc between L1 and 2 (*Figure 1*). However, there is considerable variation in this level, ranging from T12 (rarely) to L3.

This differential growth results in the lumbar and sacral nerve roots becoming considerably elongated to reach their corresponding intervertebral foramina, thus forming the cauda equina.

The lumbar vertebrae

The bodies of the lumbar vertebrae are large and kidney-shaped (*Figure 2*). The laminae are short, broad and strong, but – importantly – do not overlap, as they do in the thoracic region. If the articulated vertebral column is inspected from behind, it will be seen that the laminae and spines overlap so that the vertebral canal is completely hidden, except in the lower lumbar region. This interlaminar

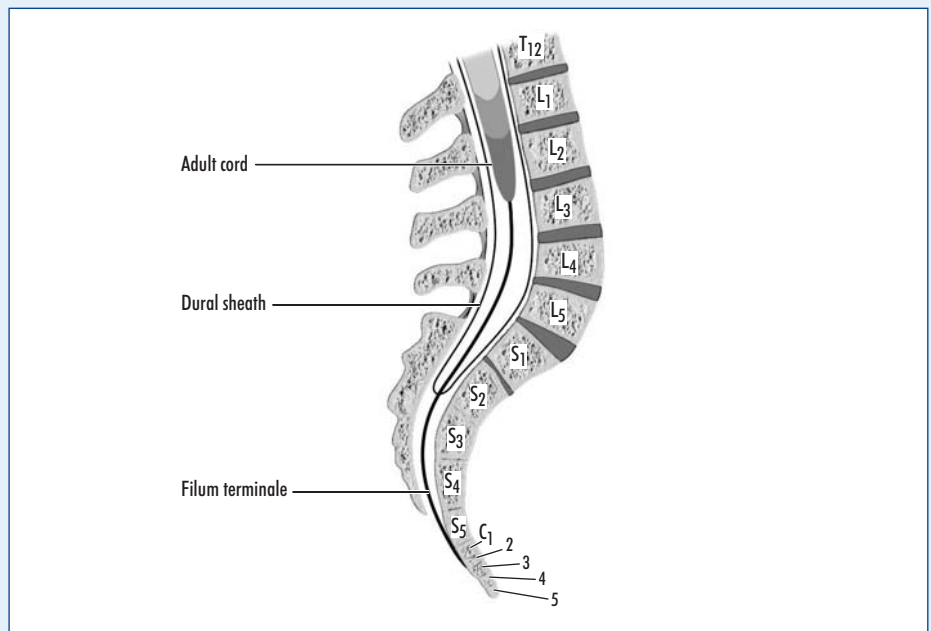


Figure 1. Termination of the spinal cord in the adult, and its range of variation.

gap is increased when the spine is flexed and it is this combination that makes lumbar puncture possible.

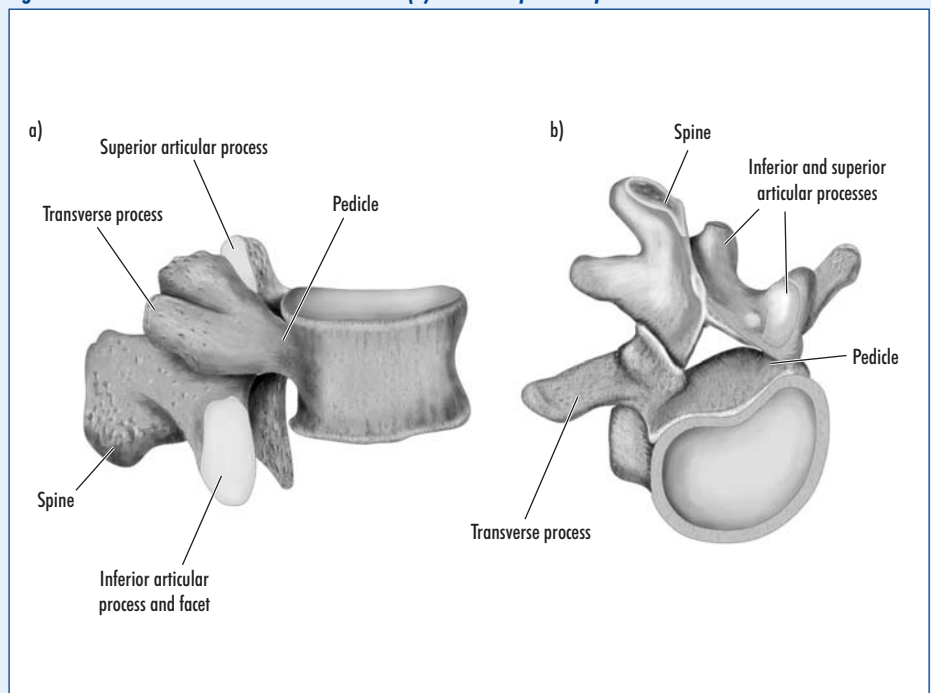
The lumbar intervertebral ligaments

The individual vertebrae are linked to each other by a complex system of articular fac-

ets and ligaments (*Figure 3*). Only slight flexion, extension and rotation can take place between adjacent vertebrae but these summate into the considerable flexibility of the vertebral column as a whole.

The vertebral bodies are linked by the intervertebral cartilages (or discs). Each is made up of peripheral fibrous tissue

Figure 2. A lumbar vertebra. a. The lateral and (b) antero-superior aspect.



Professor Harold Ellis is Clinical Anatomist, Guy's, King's and St Thomas' School of Biomedical Science, London SE1 1UL

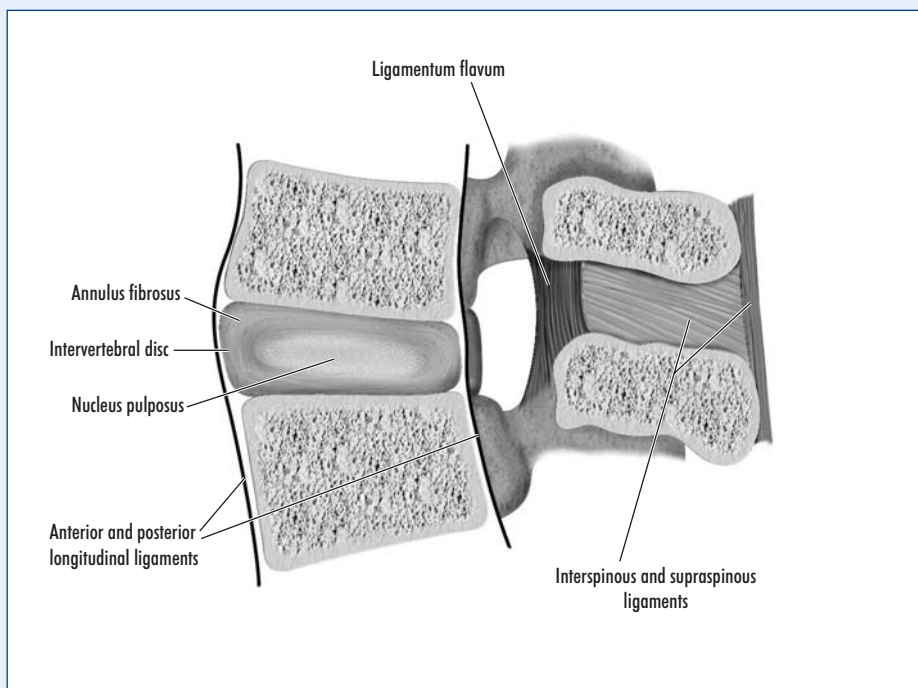


Figure 3. The principal intervertebral ligaments connecting the lumbar vertebrae.

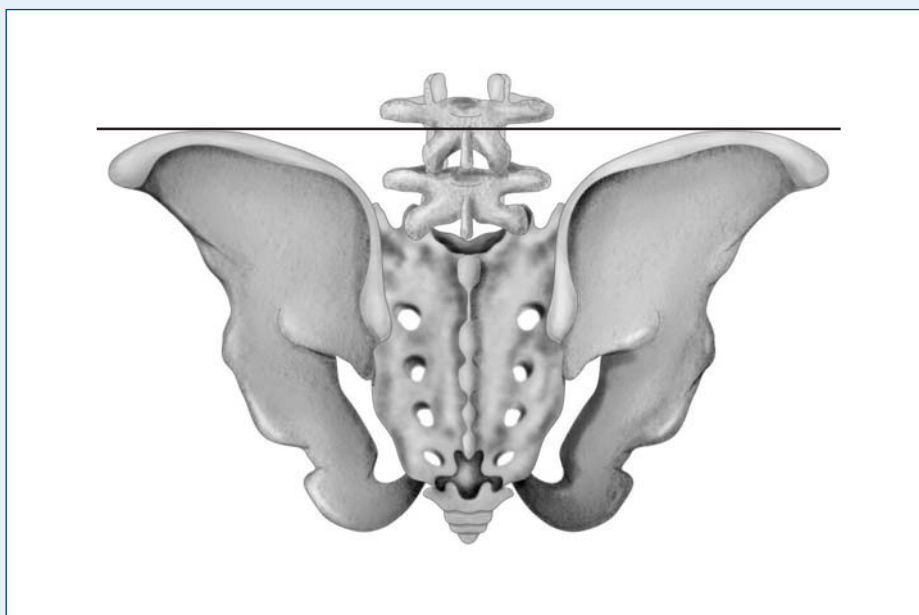


Figure 4. The line joining the iliac crests is the vital landmark to identify the tip of the fourth lumbar spine.

KEY POINTS

- Lumbar puncture may be performed for diagnostic or therapeutic reasons.
- It depends on the spinal cord terminating at approximately L1, leaving the dural sac below this level free of danger of cord injury.
- The lumbar vertebrae have short, non-overlapping spines, allowing easy ingress of a lumbar puncture needle.
- The intercristal line is the landmark for the fourth lumbar vertebra – puncture at or below this level is safe.

arranged in concentric rings (the annulus fibrosus), with a central core of soft pulpy tissue (the nucleus pulposus). This latter degenerates after the age of about 50 years, so that a 'prolapsed disc' cannot occur in patients after this age.

The anterior and posterior longitudinal ligaments run along the fronts and backs of the vertebral bodies and discs from C2 above to the upper sacrum below. They are powerful fibrous structures that adhere to the fronts and backs of the vertebral bodies respectively and to the intervening discs between.

Posteriorly lie:

- The ligamentum flavum, made up of elastic, yellow fibres (hence the name 'flavum'), which connect the adjacent laminae
- The interspinous ligaments – thin and tenuous – which connect the shafts of the adjacent spines
- The supraspinous ligament, a powerful column of fibrous tissue that connects the vertebral spines.

Anatomical basis of lumbar puncture

Lumbar puncture can be performed with the patient in the lateral or sitting position. In either case the patient is asked to flex the spine as much as possible. This widens the gaps between the lumbar spinous processes.

The iliac crests are identified. The line joining these crests (the supracristal line) invariably passes through the body of L4 (Figure 4). By identifying the tip of the lumbar spine at or below this level, the operator is confident of entering the dural sac at the L4/5 level, well below the termination of the spinal cord (Figure 1). Just above this level, L3/4, is also acceptable. The lumbar puncture needle in the mid-line traverses: skin, subcutaneous tissue, supraspinous and interspinous ligaments, ligamentum flavum and dura mater. On puncturing the dura, a characteristic 'give' is often appreciated, and on removing the stylet from the needle, CSF is obtained. **BJHM**

Conflict of interest: none.

Further reading

Ellis H, Feldman S, Harrup-Griffiths W (2004) *Anatomy for Anaesthetists*. 8th edn. Blackwell Publications, Oxford