

The clinical examination of the thyroid gland

Accurate examination of a thyroid swelling requires a good knowledge of its anatomy, and appreciation of its congenital anomalies is aided by an understanding of its embryological development.

Embryology

The thyroid gland develops as an outgrowth from the floor of the pharynx, which then descends to its definitive position in the neck (*Figure 1*). Normally all connection of the gland to its origin is lost; it is marked, however, by a pit – the foramen caecum – seen at the junction of the middle and posterior thirds of the tongue, and by the inconstant pyramidal lobe attached to the thyroid isthmus. Occasionally the thyroid gland descends into the superior mediastinum – a retrosternal thyroid – and very rarely (I have

only seen two examples in a long clinical experience) all, or more commonly part, of the gland may be found as a lump at the junction of the middle and posterior thirds of the tongue – a lingual thyroid.

Anatomy

The thyroid comprises the isthmus, which overlies the second and third rings of the trachea (*Figure 2*), and the lateral lobes, on each side, tethered to the sides of the thyroid cartilage and extending downwards to the sixth ring of the trachea.

Relations

The gland is enclosed within the pretracheal fascia, which forms a sheath containing the thyroid, the parathyroids, the larynx and upper trachea, and the pharynx and upper oesophagus (*Figure 3*). An important step in the surgical exposure of the gland is defining and opening this fascial plane. Anteriorly, the thyroid is overlapped by the strap muscles and the sternocleidomastoids. When the gland enlarges, the strap muscles stretch and adhere to the pretracheal fascia and may appear, at operation, to be thin layers of fascia. The anterior jugular veins descend vertically on either side over the isthmus.

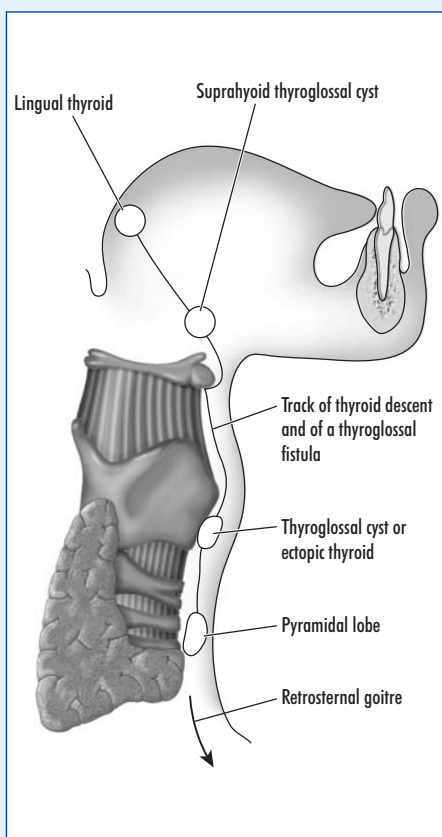
The parathyroid glands, usually two on each side, lie on the posterior surface, while on the deep aspect lie the larynx and trachea, with pharynx and oesophagus behind, and with the carotid sheath (containing common carotid artery, internal jugular vein and vagus nerve) on either side. The deep cervical chain of lymph nodes, the principal lymphatic drainage of the thyroid, lies on the carotid sheath.

Two nerves lie in close relationship to the thyroid. The recurrent laryngeal nerve lies in the groove between the oesophagus and the trachea as it passes up to the larynx, while deep to the upper pole lies the external branch of the superior laryngeal nerve as it passes to supply the cricothyroid muscle. Both may be injured in thyroid surgery.

Blood supply

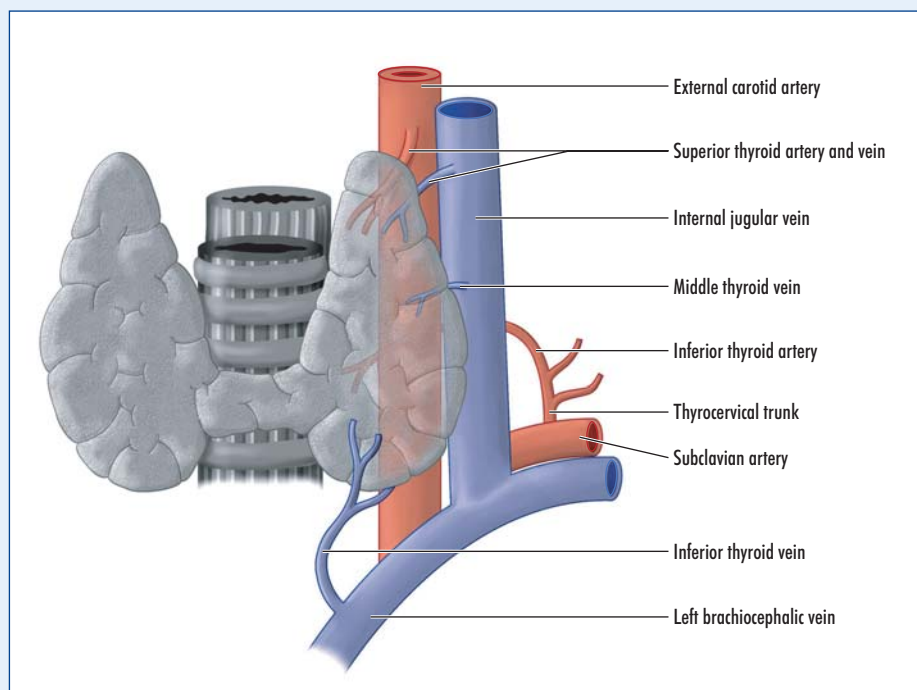
The thyroid, like all the endocrine glands, has an extremely rich vascular supply; the named vessels are shown in *Figure 2*. As well as these, numerous small vessels pass to the gland from the pharynx and trachea, so that even when all the main vessels are tied, the gland still bleeds, often quite profusely, when it is cut across in a partial thyroidectomy.

Figure 1. The development of the thyroid gland.



Professor Harold Ellis is Clinical Anatomist, Guy's, King's and St Thomas' School of Biomedical Science, London SE1 1UL

Figure 2. The anatomy of the thyroid gland and its blood supply.



Examination of the thyroid gland

The normal thyroid gland is invisible and impalpable.

Inspection is carried out with the patient sitting and with the neck fully extended, in order to thrust the gland forwards. If a swelling is visible, the patient is given a glass of water and instructed to swallow; if the mass moves upwards, it is part of the 'thyroid apparatus', that is to say, it is the thyroid itself or a thyroglossal cyst, situated above the usual site of the thyroid gland and usually to one or other side. It is a good working rule that no other masses in the neck, apart from these, move on swallowing. If a thyroglossal cyst is suspected, the patient is then asked to protrude and retract the tongue, keeping the mouth open throughout – a thyroglossal cyst, attached as it is to the base of the tongue by the thyroglossal tract, moves upwards; the diagnosis is clinched (*Figure 1*).

Next, palpation. This is carried out with the examiner standing behind the seated patient, who invariably will extend the neck for examination, but who must be instructed to flex the neck fully, so that the sternocleidomastoid and the strap muscles are fully relaxed. Without this manoeuvre, accurate palpation of the gland is quite impossible. Determine whether the gland is diffusely enlarged or if there is a local mass; is the enlargement smooth or irregular? What is its consistency?

Next consider the surrounding structures. A benign enlargement of the thyroid may narrow or displace the trachea or oesophagus, with resultant difficulty in breathing or swallowing. Palpate the trachea – is it displaced to one or other side? Palpate the common carotid artery on each side; a large benign thyroid mass may displace it posteriorly. A carcinoma of the thyroid invades rather than displaces. Under these circumstances the trachea or oesophagus may be eroded, and the carotid pulse may disappear into the mass as this vessel becomes surrounded by tumour. This involvement rather than displacement of the common carotid pulse is a differential physical sign which was first described by Sir James Berry of the Royal Free Hospital. In the same way, a malignant thyroid mass may invade the adjacent recurrent laryngeal nerve, so that voice change is a sinister symptom. This

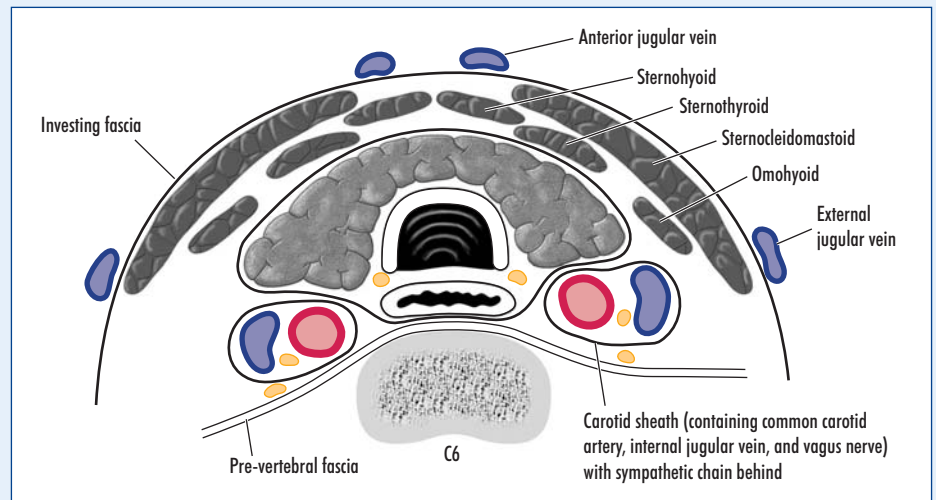


Figure 3. Transverse section of the neck at the level of the sixth cervical vertebra to show the relations of the thyroid gland.

feature, of vocal chord paralysis, is confirmed – or detected before clinically quite obvious – by performing a laryngoscopy and detecting loss of movement of the affected vocal cord. An advanced tumour of the gland may even involve the cervical sympathetic chain and produce a Horner's syndrome, with a constricted pupil and ptosis (lid lag) on the affected side.

As with any lump anywhere in the body, examination must include the regional lymph nodes, in this case the deep cervical chain running along the carotid sheath. There is a well-known syndrome, especially seen in young women, where a small, impalpable papillary carcinoma of the thyroid presents as a clump of enlarged cervical nodes.

The thyroid gland is enclosed, as we have noted, in the pretracheal fascia. This is rather badly named, since this fascia, although indeed pretracheal, actually forms a fascial sheath which encloses the larynx, pharynx, trachea, oesophagus,

thyroid and parathyroids, and extends downwards from the thyroid cartilage above to blend with the fascial sheath of the aortic arch in the superior mediastinum. This fascia is denser in front than behind, so that the enlarging gland tends to be pushed posteriorly around the sides and even the back of the trachea and the oesophagus. Moreover, a very large thyroid mass will extend downwards within this sheath into the superior mediastinum ('a plunging goitre'). Both this and an enlarged retrosternal thyroid may produce tracheal and/or oesophageal compression, as described above, and also features of superior mediastinal obstruction, with distended neck veins. Indeed, a useful aphorism is 'the commonest cause of a superior mediastinal mass is a retrosternal goitre'.

An X-ray of neck and chest is valuable in the confirmation of tracheal compression and/or displacement. **BJHM**

Conflict of interest: none.

KEY POINTS

- The thyroid gland develops from the base of the tongue and descends to its definitive position. This accounts for its various congenital anomalies.
- The gland comprises an isthmus and lateral lobes and is invested in the pretracheal fascia. It is closely related to the larynx and trachea, hence the diagnostic sign that an enlarged thyroid moves on swallowing.
- Other important relationships are the recurrent laryngeal nerve, carotid sheath (with the deep cervical chain of lymph nodes, providing lymphatic drainage), adjacent parathyroid glands and oesophagus.
- A clear understanding of the anatomy of the gland and its surrounds defines accurate clinical examination of the thyroid.