

Scrotal cystocele: a surgical pitfall

Discussion

This case demonstrates the importance of an adequate urological history and physical examination in patients with large irreducible scrotal hernias.

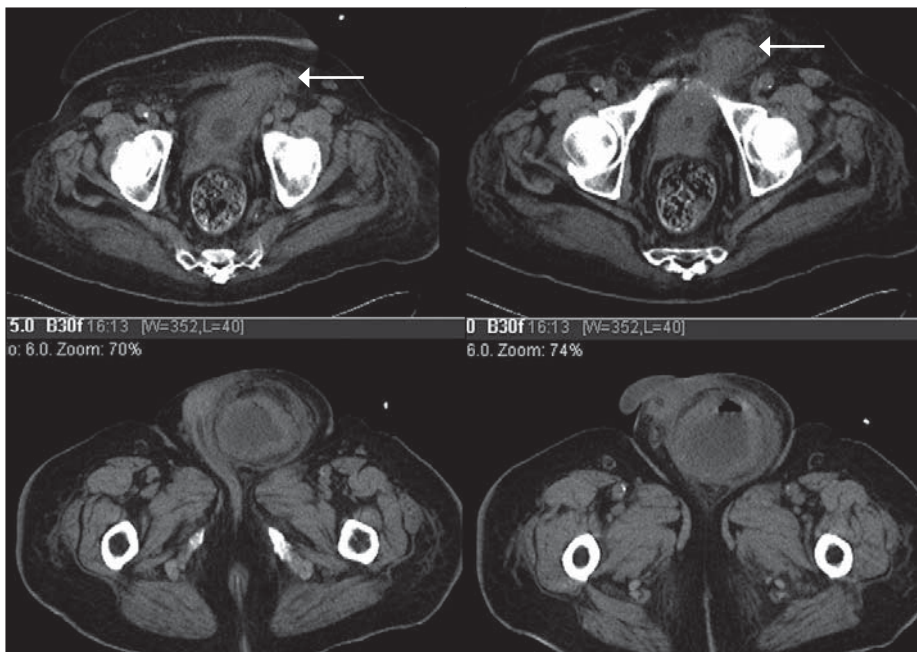
The bladder is involved in as many as 4% of all inguinal hernias and as many as 10% of hernias in men over 50 years of age (Gomella et al, 1985). Most are diagnosed at the time of hernia repair and are usually in the form of a sliding hernia. Massive inguinoscrotal bladder herniation or scrotal cystocele, however, is a surgical rarity. Any portion of the blad-

der can herniate into the scrotum from a small segment or diverticulum to the majority of the bladder as seen in this patient.

Depending on the size, location, width of the neck and the patient's functional capacity, the herniated portion can be preserved or excised. Inguinal herniation of a large bladder diverticulum can be a potentially difficult surgical problem and should be considered in the differential diagnosis of inguinoscrotal hernias, particularly in patients with obstructive symptoms of the bladder outlet.

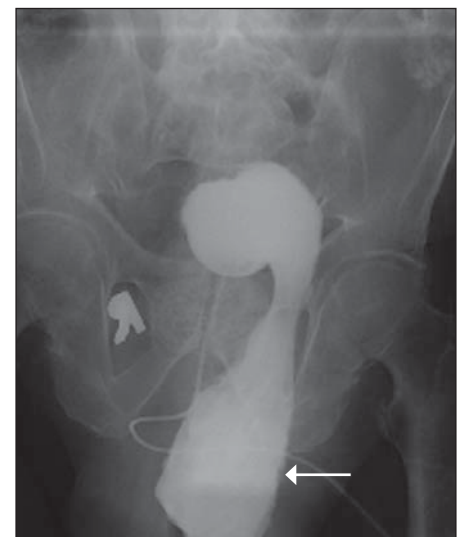
A two-stage micturition pattern, where, after emptying the abdominal portion of the bladder, the patient may void again by elevation or compression of the hernia, can also be an important diagnostic clue (Bell and Witherington, 1980). If a bladder cystocele is diagnosed preoperatively, it may alter the surgical approach and minimize the risk of inadvertent bladder injury during herniorrhaphy. **BJHM**

Figure 1. Computed tomography scan showing bladder herniation into scrotal sac.



Bell DB, Witherington R (1980) Bladder hernias. *Urology* **15**: 127–30
 Gomella LG, Spires SM, Burton JM, Ram MD, Flanigan RC (1985) The surgical implications of herniation of the urinary bladder. *Arch Surg* **120**: 964–7

Figure 2. Cystogram showing herniated bladder in scrotal sac.



Dr LD George Angus is Vice-Chairman and Director of Trauma in the Department of Surgery and **Dr Supriya Cardoza** is Resident in the Department of Radiology, Nassau University Medical Center, New York 11554, USA

Correspondence to: Dr LDG Angus

Case Report

A 91-year-old male nursing home patient with numerous medical problems was admitted to the medical service with rapid atrial fibrillation and congestive heart failure. A large scrotal hernia was noted and surgical consultation obtained. His past urological history was significant for chronic urinary retention secondary to benign prostatic hypertrophy, intermittent haematuria and recurring urinary tract infections. Given his overall poor general health, his outlet obstruction had been managed with an indwelling Foley catheter.

Examination of the scrotum revealed a large, oedematous left hemiscrotum that could not be transilluminated. Scrotal content was not reducible and no bowel sounds were audible. A computed tomography scan of the abdomen revealed herniation of bladder into the left scrotal sac (*Figure 1*). Owing to persistent swelling and drainage from the scrotum, retrograde cystography was performed and demonstrated massive herniation of the bladder through the inguinal canal and into the scrotum (*Figure 2*). Given his overall general condition, a decision was made to manage the herniation non-operatively.