

Richard Bright (1789–1858): pioneer of nephrology

This year marks the 150th anniversary of the death of Richard Bright (Figure 1), who certainly deserves the title of the founder of modern renal medicine and whose name is perpetuated in the name ‘Bright’s disease’ – until recently, the eponym commonly used for chronic nephritis. Bright was born in Bristol in 1789. His father was a banker and he was one of ten children. In 1808 he entered the University of Edinburgh in the Faculty of Arts, but soon transferred to Medicine, spent 2 years at Guy’s Hospital, then returned to Edinburgh to graduate there as MD in 1813, with a thesis on ‘Contagious erysipelas’. Bright then went on an extensive tour of medical centres in Europe, arriving at Waterloo in 1815 on his way home just 3 weeks after the battle, where he found that there was still abundant work among the sick and wounded soldiers for both surgical and medical volunteers.

In 1816, Bright obtained his first post, as assistant physician to the London Fever Hospital, where he nearly died of a severe fever and might have ended his life as a young and unknown medical martyr. Fortunately he survived, became assistant physician at Guy’s Hospital in 1820 and was promoted 4 years later, at the age of 35 years, to full physician. Here he lectured

regularly for many years with another great clinical observer, Thomas Addison. Among his many distinctions, Bright served as Physician Extraordinary to Queen Victoria. He suffered from heart disease for some time and died suddenly, on December 16 1858, in his 69th year, having suffered a haematemesis. A post-mortem examination by Timothy Holmes, of St George’s Hospital, showed gross aortic stenosis, the valves being replaced by a ‘ring of horny matter’, its orifice being reduced to a small slit. Interestingly, the kidneys, apart from ‘two or three small serous cysts’ on the right side, were normal.

Bright was above all an acute clinical observer. In 1827 he published the first of his two volume text-book entitled *Reports of medical cases selected with a view of illustrating the symptoms and cure of diseases by reference to morbid anatomy*. He was an excellent artist, and the text is illustrated by 65 hand-coloured plates.

In the preface, Bright states that the aim of his book is ‘to connect accurate and faithful illustration after death with symptoms displayed during life’ which ‘must be, in some degree, the objects of our noble art’. The first section, comprising 126 pages, is entitled ‘Cases illustrative of some of the appearances observable in the examination of diseases terminating in dropsical effusion’ (i.e. ascites). Bright points out that occasionally in these patients autopsy shows changes in the kidneys and, when this occurs, the patient has had ‘albuminous urine coagulable on heat’. He states ‘I have never yet examined the body of a patient dying with dropsy attended by coagulable urine in whom some obvious derangement is not found in the kidneys’. There follows 23 cases, observed between 1825 and 1827, to illustrate this. Some of the specimens can be seen to this day carefully preserved in the Gordon Museum at Guy’s Hospital (Figure 2). Bright’s simple test for albuminuria was to boil the urine in a spoon held over a candle flame.

One of Bright’s young assistants at Guy’s, Owen Rees, who was promoted to assistant physician in 1843, proved the presence of urea in blood and Bright notes that ‘In many cases of albuminous urine there is an excess of urea in the blood’.

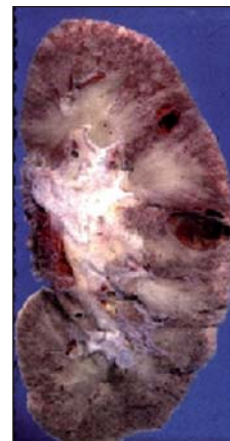
Bright stresses how little was then known about the aetiology of these gross changes in the kidneys and, apart from palliative measures, how little could be done for the patients; a situation largely unchanged for more than a century, until the modern era of renal dialysis and transplantation.

In 1842, a remarkable clinical study was carried out. The whole of the 41 beds in the clinical wards at Guy’s were set aside from May to October for renal cases to be admitted exclusively and under the care of Richard Bright – imagine such a thing being allowed today! He wrote ‘the first experiment which, as far as I know, has yet been made in this country to turn the complete resources of a hospital to the investigation of one particular disease by bringing the patients labouring under it into one ward properly arranged for its observation’. A small laboratory was attached to the ward. By the following year microscopic observations had been made on kidney specimens of over 100 patients suffering from nephritis.

Unfortunately, a proposed book on the anatomy and pathology of the kidney was never published. Bright’s achievement was quite remarkable – in 1826 nothing was known about chronic nephritis. Over the next 10 years he established the existence of a common serious condition, with effects on most of the organs of the body, and had correlated the clinical features with changes in the kidneys and other structures. This together with establishment

of a simple urine test for albuminuria and even the demonstration of laboratory changes in blood urea. Surely he deserves acknowledgment as a father of renal medicine. **BJHM**

Figure 2. One of Bright’s original specimens of chronic nephritis.



Figures 1 and 2 are reproduced by kind permission of the Gordon Museum at Guy’s Hospital. Conflict of interest: none.

Figure 1. Portrait of Richard Bright.



Professor Harold Ellis is Emeritus Professor of Surgery, Guy’s, King’s and St Thomas’ School of Biomedical Sciences, London SE1 1UL