

Cerebral venous sinus thrombosis in polycythaemia

Introduction

Cerebral venous sinus thrombosis is a serious condition that should be suspected in patients with severe and unexplained headache, especially in the presence of pro-thrombotic risk factors. This article reports a case of venous sinus thrombosis in a patient with polycythaemia, describes the initial and subsequent management of venous sinus thrombosis, and discusses the investigation and management of polycythaemia.

Discussion

Cerebral venous sinus thrombosis is a rare but serious event with an annual incidence of 3–4 cases per million of the population (Stam, 2005). It has a variable presentation but severe headache is the most common symptom, present in over 90% of cases (de Bruijn et al, 2001). The headache is usually subacute, severe and generalized but a thunderclap onset has been reported (Masuhr et al, 2004). Other common fea-

tures are focal neurological deficit (46%), papilloedema (41%), seizures (47%) or decreased consciousness (39%) (de Bruijn et al, 2001). Predisposing factors include inherited thrombophilias, pro-thrombotic systemic conditions (including pregnancy and the puerperium), blood dyscrasias (e.g. thrombocythaemia), some drugs (e.g. oral contraceptive pill, hormone replacement therapy) and local factors such as head injury, arteriovenous malformation or meningitis, as well as middle ear and facial infections (Kimber, 2002).

The diagnosis of venous sinus thrombosis can be made with computed tomography but the non-invasive imaging method of choice is magnetic resonance imaging venography (Kimber, 2002). Treatment is with anticoagulation, initially with heparin and then warfarin, for a period of 3–6 months, unless there is a persisting predisposing factor (Masuhr et al, 2004).

Polycythaemia is prothrombotic and the risk of thrombosis increases with haemat-

ocrit (Hart et al, 1990). The incidence of arterial stroke or transient ischaemic attack in patients with polycythaemia rubra vera is 4–5% per year (Hart et al, 1990) and is reduced by phlebotomy. Polycythaemia rubra vera is a clonal stem-cell process and mutation of an intracellular kinase, JAK2 (V617F), is found in up to 97% of patients with the condition (Chen et al, 2006). The mutation is not specific to polycythaemia but is useful in differentiating primary and secondary disease and in the context of raised haemoglobin, haematocrit and red cell count and a suppressed erythropoietin level, a diagnosis of rubra vera can be made (Chen et al, 2006). **BJHM**

- de Bruijn SFTM, de Haan RJ, Stam J (2001) Clinical features and prognostic factors of cerebral venous sinus thrombosis in a prospective series of 59 patients. *J Neurol Neurosurg Psychiatry* **70**: 105–8
- Chen G, Prchal JT (2006) Polycythaemia vera and its molecular basis: an update. *Best Pract Res Clin Haematol* **19**: 387–97
- Hart RG, Kanter MC (1990) Haematological disorders and ischaemic stroke. *Stroke* **21**: 1111–21
- Kimber J (2002) Cerebral venous sinus thrombosis. *QJ Med* **95**: 137–42
- Masuhr F, Mehraein S, Einhaupl K (2004) Cerebral venous and sinus thrombosis. *J Neurol* **251**: 11–23
- Stam J (2005) Thrombosis of the cerebral veins and sinuses. *N Engl J Med* **352**: 1791–8

Case Report

A 50-year-old man was admitted as an emergency with severe bilateral headache. For 1 month he had felt unwell with a gradual onset, dull, throbbing headache that kept him awake at night. Admission to hospital was precipitated by an increase in severity of headache, associated with nausea and photophobia.

There were no exacerbating factors and the headache was not positional. He denied red eye, lacrimation, blurred vision or visual fortification, dizziness, weakness or change in sensation. He had no other past medical history. He was an ex-smoker with a 10 pack-year history. On examination, he was plethoric. He was afebrile and blood pressure raised at 160/120 mmHg. There was no meningism and fundoscopy was normal. The remainder of the examination was unremarkable. Urine dipstick demonstrated 3+ protein, an electrocardiogram showed T-wave inversion inferiorly, with no evidence of left ventricular hypertrophy by voltage criteria, and a chest radiograph was normal. The initial diagnosis was hypertensive headache, but the patient was found to be significantly polycythaemic.

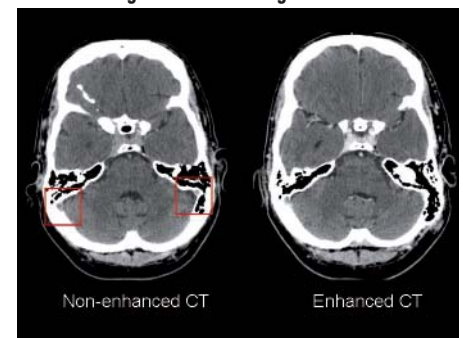
His test results were haemoglobin = 21.2 g/dl (normal range 13.0–17.0 g/dl); haematocrit = 0.656 (normal range 0.4–0.5); red cell count = 7.72×10^{12} /litre (normal range 4.5 – 5.5×10^{12} /litre); white cell count = 11.0×10^9 /litre (normal range 4.0 – 11.0×10^9 /litre); platelets = 295×10^9 /litre (normal range 150 – 400×10^9 /litre); clotting profile was normal; biochemical profile was normal; PaO₂ on room air was 10.8 kPa.

The diagnosis was amended to headache secondary to hyperviscosity and an urgent computed tomography scan of the brain was arranged to rule out cerebral venous sinus thrombosis. The computed tomography scan of the brain confirmed subacute thromboses of the right transverse and sigmoid sinuses.

To manage hyperviscosity, the patient underwent isovolaemic venesection of 450 ml of blood. The venous sinus thrombosis was treated by anticoagulation with low molecular weight heparin and the patient was commenced on warfarin.

Subsequent investigations revealed a suppressed erythropoietin (0.88 mU/ml; normal range 5–25 mU/ml) and the presence of the JAK-2 chromosomal mutation, which confirmed a diagnosis of polycythaemia rubra vera. The patient was discharged and returned for day case venesection.

Figure 1. Computed tomography scan of brain demonstrating thrombosis of right transverse sinus.



Dr D Thomson is Specialty Registrar (ST1) in Core Medical Training, Manchester Royal Infirmary, Manchester M13 9WL,
Dr P Vyas is Consultant Haematologist and **Dr MS Hammersley** is Consultant Physician, Nuffield Department of Medicine, John Radcliffe Hospital, Oxford

Correspondence to: Dr D Thomson