

# Current management of varicose veins

*There has been an increasing trend towards less invasive methods of treating varicose veins, e.g. foam sclerotherapy, radiofrequency ablation and endovenous laser ablation, which has led many to question the more conventional methods of treating varicose veins. This review focuses on current techniques of managing varicose veins.*

The traditional surgical treatment of varicose veins has yielded variable results in the past mainly because there has been less interest in venous surgery. However, an increase in the number of surgeons with a special interest in venous surgery has resulted in development of different surgical techniques to improve the management of varicose veins. This article gives an overview of the underlying pathology of varicose veins, clinical features which warrant referral to the surgeons for treatment, non-surgical and surgical treatment options with emphasis on newer surgical techniques and their efficacy, and finally the postoperative care of patients in the hospital and after discharge by GPs.

## Aetiology

The primary lesion is in the muscle cell of the vein wall where a degenerative fibrosis develops. This leads to loss of the vessel wall tone, causing dilatation of the vein wall in between the valves. Ultimately the valve ring also dilates, preventing valve cusps from meeting and causing disuse atrophy and venous reflux. This not only affects the superficial veins but also the perforators (Browse et al, 1999). Age, gender (Gundersen and Hauge, 1969; Cornu-Thenard et al, 1994), weight, occupation, posture and genetics have been proposed as predisposing factors for varicose vein formation (Browse et al, 1999).

## Clinical examination

This should begin with a general physical examination including age, weight and body mass index. The directed examination involves inspection and palpation of the legs in both supine and standing positions. In the standing position the palpable cough impulse, tap test, trendelenberg test and/or tourniquet tests are done. These are usually accompanied by hand-held Doppler examination to test saphenopopliteal and/or saphenofemoral junction incompetence (Bello et al, 1999; MacKenzie et al, 2004).

The CEAP classification was developed by an international consensus conference (Porter and Moneta, 1995), including clinical signs (C), aetiology (E), anatomical distribution (A) and pathophysiological condition (P), but for unknown reasons, it is rarely used in clinical practice.

Mr Umar Sadat is Clinical Research Associate Vascular Imaging and Fellow in Vascular Surgery and Mr Michael Gaunt is Consultant Vascular Surgeon in the Cambridge Vascular Unit, Addenbrooke's Hospital, Cambridge University Hospitals NHS Foundation Trust, Cambridge CB2 2QQ

Correspondence to: Mr U Sadat

## Investigations

### Hand-held Doppler

Continuous wave hand-held Doppler using an 8 MHz probe is useful in screening for venous insufficiency and is most commonly performed in outpatient clinics. It is performed, with the patient in the standing position, by insonating the saphenopopliteal and saphenofemoral junction as the release of distal calf compression is used to provoke reflux (Hoare and Royle, 1984). Doppler has been reported to have sensitivity and specificity of 97% and 73% respectively for identification of saphenofemoral junction reflux (Kim et al, 2000). However, its limitations include that the exact vein being insonated is known, being operator dependent and the significance of reflux of short duration may be uncertain. It is not an alternative to a duplex scan.

### Duplex scan

The duplex scan is the most widely used test for the diagnosis and management of chronic venous disease before a definite treatment plan is made. As it combines B mode imaging and pulsed Doppler, it can accurately localize valvular reflux (Szendro et al, 1986), delineate venous anatomy (Vasdekis et al, 1989) and rule out deep venous thrombosis (Hobbs, 1980). Provocative manoeuvres like manual or pneumatic compression can be used to elicit reflux.

### Other investigations

The venous drainage from the legs does not only depend on a normal functioning venous system; calf muscle pump also influences its overall function. Ambulatory venous pressure and plethysmography are other methods of assessing functional calf volumes, giving useful information about overall lower limb venous function. In straightforward varicose vein management, they are not required.

## Management

Varicose veins, telangiectatic blemishes and dilated tortuous (Figure 1), flat, blue green reticular veins are not normal physical findings. They are evidence of venous dysfunction.

### Symptoms

The aching pain is the most common symptom resulting from pressure of dilated vessels on the somatic nerve fibres adjacent to them. However, it is not related to the length or diameter of the malfunctioning vein (Goldman et al, 1994). Other symptoms include leg heaviness, leg fatigue, rapidly spreading superficial thrombophlebitis,

recurrent thrombophlebitis, external bleeding, hyperpigmentation in the gaiter area, lipodermatosclerosis and venous ulceration.

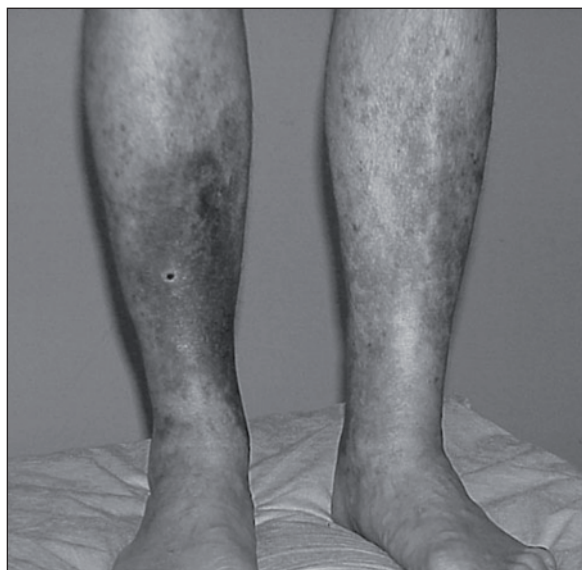
All the above symptoms warrant intervention and referral to a vascular surgeon. Patients presenting for cosmetic reasons cannot currently be offered treatment for varicose veins on the NHS. Similarly patients with recurrent deep vein thrombosis or recent deep vein thrombosis are not considered for surgical intervention.

### Non-surgical treatment

Although surgery has been perceived to be the gold standard treatment for varicose veins, the label 'varicose veins' covers a heterogeneous spectrum of venous disease including small varicose veins (flare or reticular veins) and the ideal treatment for small veins is non-surgical. Similarly, not all patients are suitable for surgery owing to other concurrent illnesses or personal choice.

### Compression therapy

Although compression stockings do not treat the underlying pathology, they can be effective in controlling symptoms like pain, leg heaviness and oedema. The reduction in leg swelling can prevent deterioration of skin changes (*Figure 2*). Although the precise mechanism is unclear, possible external graduated compression of the dilated varicosities facilitates venous drainage from the superficial system towards the deep venous system, thereby reducing venous hypertension and the complica-

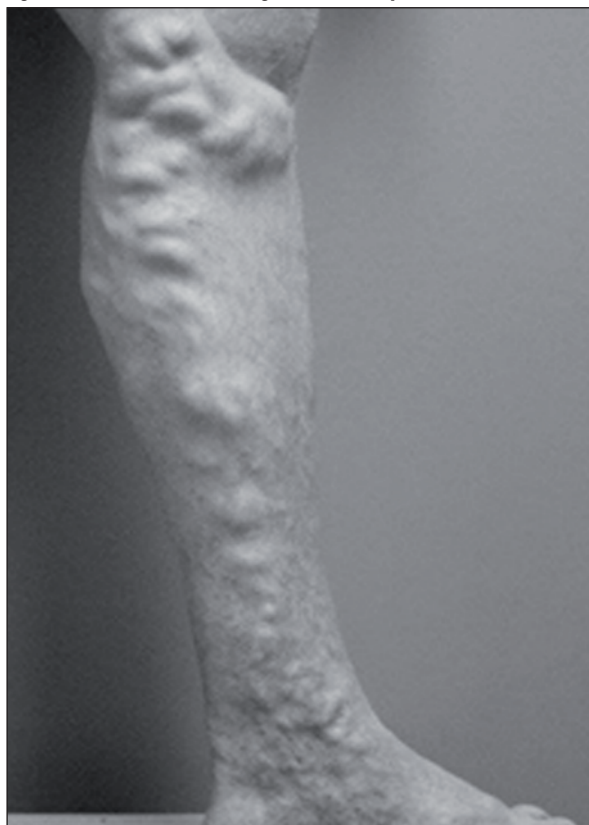

**Figure 2. Venous eczema: a sign of venous insufficiency.**

tions resulting from it (Sigel et al, 1973; Cornwall et al, 1987; Mayberry et al, 1991). Usually class II compression stockings are used during the daytime which provide moderate compression at absolute pressure of 22–32 mmHg. In the authors' practice, patients can choose to use them for 3–6 months while they await duplex imaging. If their symptoms improve, they can continue using them rather than having surgery.

Compression stockings are contraindicated in peripheral vascular disease, so peripheral pulses should always be checked before prescribing them.

**Figure 1. Varicose veins: enlarged tortuous superficial veins.**



### Sclerotherapy

Sclerotherapy is mainly used for treatment of small varicose veins which includes telangiectasias and reticular veins (Baccaglini et al, 1996). However, there is no consensus regarding the use of sclerotherapy in treatment of long varicose veins and perforators (Baccaglini et al, 1996). It is also an ideal choice for the treatment of post-operative residual veins and recurrent varicosities. The commonly used sclerosing agents are chromated glycerine 25–100%, polidocanol 0.2–1% or sodium salicylate 6–12% (Baccaglini et al, 1996). Small needles with gauges between 25 and 33 G are used.

Injection sclerotherapy is usually complemented by post-sclerotherapy compression dressings, which have shown reduction in symptoms (Fraser et al, 1985; Scurr et al, 1985). However, the long-term recurrence and persistence rate is high compared to surgery, ranging from 20% to 70% (Piachaud and Weddell, 1972; Beresford et al, 1978). Patients who undergo injection sclerotherapy do suffer from transient phlebitis which usually takes at least 7–10 days to settle. Non-steroidal anti-inflammatory medication along with reassurance can be used. Up to 25% of patients suffer quite marked skin staining which has made it an unattractive treatment option.

### Foam sclerotherapy

In this modification of conventional sclerotherapy the sclerosant is forcibly mixed with air so that it spreads widely through the lower limb veins (Cabrera et al, 2001). It is usually carried out under ultrasound guidance. Potential advantages include low cost and short treatment times on an outpatient basis (Tessari et al, 2001; Frullini and Cavezzi, 2002). However, phlebitis remains a problem as it is for injection sclerotherapy. As foam sclerotherapy can be repeated, failure to obliterate the long saphenous vein completely is less of an issue.

### Surgical options

#### Saphenous vein high tie and stripping

This is the traditional method of treating symptomatic varicose veins in large and/or short saphenous veins. Although initially high ligation alone was thought to suffice for removal of gravitational reflux while preserving the vein (Munn et al, 1981; McMullin et al, 1991), there is evidence of persistence of reflux and increased frequency of recurrence (Darke, 1992; Stonebridge et al, 1995) following high ligation only *vs* high ligation and accompanied stripping. This is true for both short and long saphenous vein incompetence. Although it is usually performed as day case surgery under general anaesthesia especially when one leg is operated upon, bilateral surgery may require overnight hospital stay. General patient health and co-morbidities may also influence the hospital stay.

Complications include bleeding, haematoma formation, wound infection, bruising, pigmentation, nerve damage, patches of numbness in the operated leg and recurrence. The bruising usually settles in 2–3 weeks, but pigmentation may be permanent. Similarly the numbness may be transient, settling in 6–12 months, or may be permanent. If wound infection develops, a course of antibiotics may have to be prescribed. The chances of recurrence are higher especially in redo operations. This group is also more prone to develop seromas and lymphocele.

Postoperatively patients are encouraged to mobilize the next day with good analgesic cover usually required in the form of non-steroidal anti-inflammatory drugs. Compression dressings are removed on the first postoperative day. The authors advise patients to wear compression stockings for 3–4 weeks and take analgesics as required. Patients can perform day-to-day activities as soon as they feel fit enough to do so, with return to a desk job in 7–10 days' time and to physical jobs in 2–3 weeks' time.

#### Avulsions

As stripping is not done for the long saphenous vein below the knee because of high risk of damage to the saphenous nerve, concomitant avulsions are performed through 1–2 mm stab incisions which are usually closed with steri-strips. However, large incisions may require a single inverted absorbable suture. They usually come off on their own in 5–7 days with no further dressing required. Isolated avulsions can also be performed in case of isolated

varicosities under local anaesthesia with concomitant high tie and stripping especially in cases of recurrences.

### Endovenous techniques

These include radiofrequency ablation and laser ablation, which have the potential to improve the outcome of treatment for varicose veins.

#### Radiofrequency ablation

Radiofrequency ablation using the VNUS Closure procedure (VNUS Medical Technologies Inc., California) was first used in Europe in 1998. Since then, it has been used mainly in private settings in the UK. It involves passage of a radiofrequency ablation catheter into the saphenous vein (long or short) through a small cut-down under ultrasound guidance with the patient in 30° Trendelenburg tilt. This can be done under general anaesthesia, when stab avulsions can be performed simultaneously, or under local anaesthesia with or without sedation. The part of the leg where the vein is ablated is compressed with an Esmark bandage to compress the vein around the catheter. Ablation is performed from just below the saphenofemoral junction downwards with target temperature set at 85±3 °C. In the authors' opinion, a patient with a vein diameter less than 2 mm or more than 12 mm, tortuous vein, or a thrombus in the vein is unsuitable for ablation. Vein occlusion rates 1 week after the procedure are between 88 and 100% (Navarro et al, 2001; Tessari et al, 2001; Frullini and Cavessi, 2002; Rautio et al, 2002; Lurie et al, 2003). At 2 years, 85–90% of those treated remain occluded (Navarro et al, 2001; Rautio et al, 2002). Complete absence of symptoms or a significant improvement has been seen in 94–100% of patients (Navarro et al, 2001; Frullini and Cavessi, 2002) with patient satisfaction ranging from 92–100% (Cabrera et al, 2001; Navarro et al, 2001; Frullini and Cavessi, 2002; Rautio et al, 2002).

VNUS Closure FAST is a newer way of treating varicose veins, as fast as laser ablation devices, with minimal pain and bruising. The entire procedure, from insertion of the catheter to removal, can be completed in approximately 16 minutes – less than half the time required for previous radiofrequency-based procedures. Since the Closure FAST catheter received Food and Drug Administration clearance, many physicians in the USA and Europe have used the device, and it is now widely available.

The complications include thermal injury to the skin (0–3%) or saphenous nerve. Bruising, erythema or clinical phlebitis can be clinically significant in a small proportion of people. One of the downsides of this treatment modality is the high cost of the equipment. However, earlier return to normal activity and work may significantly reduce the number of lost working days.

#### Endovenous laser ablation

This method uses laser as the means of closing the saphenous vein in a similar manner to radiofrequency ablation. Min et al (2003) have reported the largest pub-

lished experience of this technique with an early success rate of 98% with 93% of long saphenous veins remaining occluded at 2 years after the procedure. Complications include possible damage to the nerves surrounding the vein and burning of the skin, but in expert hands the incidence of complications should be minimal. Clinical studies with greater number of patients need to be reported to assess its efficacy as compared to radiofrequency ablation and open surgery.

## Conclusions

Patients suffering from symptomatic varicose veins usually have to wait for long periods before receiving investigations and treatment on the NHS. Although the advent of newer endovenous procedures has attracted significant attention because of the benefits of earlier return to work and better cosmetic results, this service is not unavailable on the NHS. It has to be borne in mind that these new techniques have been reported by enthusiasts in private settings, where there is less pressure of audit. There may be unreported complications and hesitation in presenting poorer results. So, before these treatment modalities replace the traditional methods in NHS, large multicentre randomized controlled trials have to be conducted. Another concern will be further prolonged waiting times in an already overstretched UK health system if the radiofrequency ablation and endovenous laser ablation service was to be provided on the NHS. **BJHM**

*Conflict of interest: none.*

- Baccaglioni U, Spreafico G, Castoro C, Sorrentino P (1996) Sclerotherapy of varicose veins of the lower limbs. Consensus paper. North American Society of Phlebology. *Dermatol Surg* **22**(10): 883–9
- Bello M, Scriven M, Hartshorne T, Bell PR, Naylor AR, London NJ (1999) Role of superficial venous surgery in the treatment of venous ulceration. *Br J Surg* **86**(6): 755–9
- Beresford SA, Chant AD, Jones HO, Piachaud D, Weddell JM (1978) Varicose veins: A comparison of surgery and infection/compression sclerotherapy. Five-year follow-up. *Lancet* **i**: 921–4
- Browse NL, Burnand KG, Irvine AT, Wilson NM (1999) Varicose veins; pathology. In: Browse NL, Burnand KG, Irvine AT, Wilson NM, eds. *Disease of the Veins*. Oxford University Press, New York: 145–62
- Cabrera J, Cabrera J Jr, Garcia-Olmedo MA (2001) Sclerosants in microfoam. A new approach in angiology. *Int Angiol* **20**(4): 322–9
- Cornu-Thenard A, Boivin P, Baud JM, De Vincenzi I, Carpentier PH (1994) Importance of the familial factor in varicose disease. Clinical study of 134 families. *J Dermatol Surg Oncol* **20**(5): 318–26
- Cornwall JV, Dore CJ, Lewis JD (1987) Graduated compression and its relation to venous refilling time. *BMJ* **295**: 1087–90
- Darke SG (1992) The morphology of recurrent varicose veins. *Eur J Vasc Surg* **6**(5): 512–17
- Fraser IA, Perry EP, Hatton M, Watkin DF (1985) Prolonged bandaging is not required following sclerotherapy of varicose veins. *Br J Surg* **72**(6): 488–90
- Frullini A, Cavezzi A (2002) Sclerosing foam in the treatment of varicose veins and telangiectases: history and analysis of safety and complications. *Dermatol Surg* **28**(1): 11–15
- Goldman MP, Weiss RA, Bergan JJ (1994) Diagnosis and treatment of varicose veins: a review. *J Am Acad Dermatol* **31**(3 Pt 1): 393–413
- Gundersen J, Hauge M (1969) Hereditary factors in venous insufficiency. *Angiology* **20**(6): 346–55
- Hoare MC, Royle JP (1984) Doppler ultrasound detection of saphenofemoral and saphenopopliteal incompetence and operative venography to ensure precise saphenopopliteal ligation. *Aust NZ J Surg* **54**(1): 49–52
- Hobbs JT (1980) Peroperative venography to ensure accurate sapheno-popliteal vein ligation. *BMJ* **280**: 1578–9
- Kim J, Richards S, Kent PJ (2000) Clinical examination of varicose veins—a validation study. *Ann R Coll Surg Engl* **82**(3): 171–5
- Lurie F, Cretton D, Eklof B et al (2003) Prospective randomized study of endovenous radiofrequency obliteration (closure procedure) versus ligation and stripping in a selected patient population (EVOLVE Study). *J Vasc Surg* **38**(2): 207–14
- MacKenzie RK, Allan PL, Ruckley CV, Bradbury AW (2004) The effect of long saphenous vein stripping on deep venous reflux. *Eur J Vasc Endovasc Surg* **28**(1): 104–7
- Mayberry JC, Moneta GL, Taylor LM Jr, Porter JM (1991) Fifteen-year results of ambulatory compression therapy for chronic venous ulcers. *Surgery* **109**(5): 575–81
- McMullin GM, Coleridge Smith PD, Scurr JH (1991) Objective assessment of high ligation without stripping the long saphenous vein. *Br J Surg* **78**(9): 1139–42
- Min RJ, Khilnani N, Zimmet SE (2003) Endovenous laser treatment of saphenous vein reflux: long-term results. *J Vasc Interv Radiol* **14**(8): 991–6
- Munn SR, Morton JB, Macbeth WA, Mcleish AR (1981) To strip or not to strip the long saphenous vein? A varicose veins trial. *Br J Surg* **68**(6): 426–8
- Navarro L, Min RJ, Bone C (2001) Endovenous laser: a new minimally invasive method of treatment for varicose veins—preliminary observations using an 810 nm diode laser. *Dermatol Surg* **27**(2): 117–22
- Piachaud D, Weddell JM (1972) Cost of treating varicose veins. *Lancet* **ii**: 1191–2
- Porter JM, Moneta GL (1995) Reporting standards in venous disease: an update. International Consensus Committee on Chronic Venous Disease. *J Vasc Surg* **21**(4): 635–45
- Rautio T, Ohinmaa A, Perala J et al (2002) Endovenous obliteration versus conventional stripping operation in the treatment of primary varicose veins: a randomized controlled trial with comparison of the costs. *J Vasc Surg* **35**(5): 958–65
- Scurr JH, Coleridge-Smith P, Cutting P (1985) Varicose veins: optimum compression following sclerotherapy. *Ann R Coll Surg Engl* **67**(2): 109–11
- Sigel B, Edelstein AL, Felix WR Jr, Memhardt CR (1973) Compression of the deep venous system of the lower leg during inactive recumbency. *Arch Surg* **106**(1): 38–43
- Stonebridge PA, Chalmers N, Beggs I, Bradbury AW, Ruckley CV (1995) Recurrent varicose veins: a varicographic analysis leading to a new practical classification. *Br J Surg* **82**(1): 60–2
- Szendro G, Nicolaidis AN, Zukowski AJ, Christopoulos D, Malouf GM, Christodoulou C, Myers K (1986) Duplex scanning in the assessment of deep venous incompetence. *J Vasc Surg* **4**(3): 237–42
- Tessari L, Cavezzi A, Frullini A (2001) Preliminary experience with a new sclerosing foam in the treatment of varicose veins. *Dermatol Surg* **27**(1): 58–60
- Vasdekis SN, Clarke GH, Hobbs JT, Nicolaidis AN (1989) Evaluation of non-invasive and invasive methods in the assessment of short saphenous vein termination. *Br J Surg* **76**(9): 929–32

## KEY POINTS

- Varicose veins are enlarged tortuous superficial veins of the leg caused by malfunctioning valves in the veins, and decreased elasticity of the vein wall, allowing pooling of blood within the veins, and their subsequent enlargement.
- Compression stockings are often used as first-line treatment for varicose veins.
- Injection sclerotherapy may be more effective than compression stockings, but less effective than surgery, at improving symptoms and cosmetic appearance.
- Surgery (saphenofemoral ligation, stripping of the long saphenous vein, or avulsions) is beneficial in reducing recurrence, and improving cosmetic appearance, compared with sclerotherapy alone.
- Radiofrequency ablation and endovenous laser ablation are new effective methods of treating varicose veins with better cosmetic results and early return to normal activity which may significantly reduce the number of lost working days.