

Management of osteoarthritis of the glenohumeral joint

The National Institute for Health and Clinical Excellence will this year publish general guidelines for the management of osteoarthritis. The surgical management of shoulder arthritis has been an area of marked activity in the last decade. This article reviews current trends in the management of glenohumeral osteoarthritis.

Osteoarthritis is the commonest cause of joint disability in the developed world. It is uncommon in people under 40 years and increases with age thereafter. The UK population has increased by 7% in the last 35 years, from 55.9 million in 1971 to 60.5 million in 2006 (Office for National Statistics, 2008). However, the population is also ageing, with the proportion of people aged 65 years and over increasing from 13% to 16% in the last 30 years. Although weight-bearing joints are more commonly affected, there has been an increase in the number of patients presenting to their GP with osteoarthritis of the shoulder (McCormick et al, 1995).

Methods

A search for relevant articles in PubMed, Ovid Medline and the Cochrane library was performed. Keywords used were osteoarthritis, shoulder, pain, glenohumeral, arthritis, analgesia, paracetamol, anti-inflammatory, NSAIDs, tramadol, opioid, codeine, acupuncture, physiotherapy, local anaesthetic, arthroplasty, hemiarthroplasty, resurfacing, reverse shoulder prosthesis.

Basic anatomy

1. The glenohumeral joint of the shoulder is a ball and socket joint formed by the humerus and glenoid respectively
2. The shoulder joint has the widest range of movement of any joint in the body
3. The shoulder joint is primarily stabilized by the glenoid labrum, rotator cuff muscles and thickenings of the shoulder capsule (the superior, middle and inferior glenohumeral ligaments).

Diagnosis

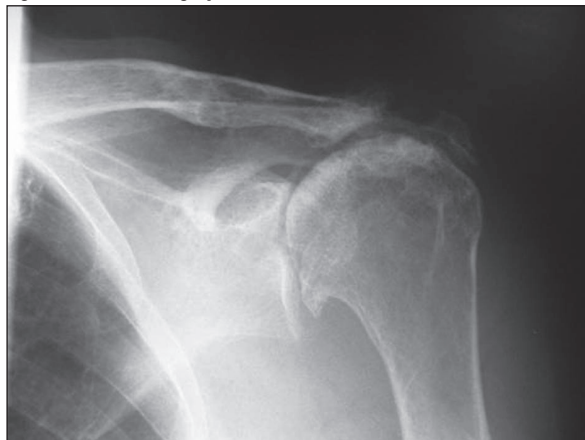
The clinical history of glenohumeral osteoarthritis is of progressive pain and stiffness. The pain usually intensi-

fies with use and interferes with sleep. The location of pain is related to the joint lines, anterior and posterior. It is felt less at the insertion of deltoid, an area more commonly associated with rotator cuff disease. Shoulder motion is restricted by synovial membrane inflammation and increased fluid production. Clinical examination reveals restricted, painful movements, with or without palpable crepitus. The integrity of the rotator cuff muscles should be assessed, but may be difficult in the presence of painful movements.

Plain radiographs will help to confirm the diagnosis. A true anteroposterior view of the glenohumeral joint and a transaxillary lateral are the most commonly used views. Radiographic features of glenohumeral osteoarthritis are the classic quartet of osteoarthritis: loss of joint space, osteophytes, sclerosis and bone cysts. In addition, look for proximal migration of the humeral head, suggesting a rotator cuff tear. These radiographic features are shown in *Figure 1*. Further imaging modalities are not routinely necessary, but computed tomography (CT) may help with preoperative planning to determine bone stock and bone quality, especially on the glenoid side. Occasionally, ultrasound scanning or magnetic resonance imaging (MRI) may be used to assess the rotator cuff, as the presence of a massive rotator cuff tear may preclude total shoulder replacement.

Serum studies may be helpful, but cannot be interpreted in isolation. Full blood count, autoantibodies (rheumatoid factor and antinuclear antibody), uric acid

Figure 1. Plain radiograph of osteoarthritis of left shoulder.



Mr Ian Sinha is Specialist Registrar in Orthopaedics and Trauma in the Department of Orthopaedics, Charing Cross Hospital, London W6 8RF, **Mr Marcus Lee** is Consultant Orthopaedic Surgeon and **Mr Carlos Cobiella** is Consultant Orthopaedic Surgeon in the Department of Orthopaedics, University College Hospital, London

Correspondence to: Mr I Sinha

and acute-phase reactant measurements, erythrocyte sedimentation rates and C-reactive protein are most often performed as an initial screening battery and most helpful when the diagnosis is in question.

The differential diagnosis includes adhesive capsulitis, rotator cuff disease, and conditions allied to osteoarthritis, namely posttraumatic arthritis, arthritis of dislocation, avascular necrosis, rheumatoid arthritis, crystalline arthritis, non-infectious inflammatory arthritis and miscellaneous arthropathies.

Management strategies

The management of glenohumeral osteoarthritis is broadly divided into non-operative and operative.

Non-operative

Depending upon the stage at which a patient presents, conservative measures should be considered before offering surgery. In addition, there is a substantial population that may not be ideal candidates for joint replacement. Such patients include those with coexisting medical morbidities that would prevent arthroplasty, and those young and active patients in whom a prosthetic replacement would be subject to excessive risk of failure. However, as highlighted below, the evidence base for conservative treatment of shoulder osteoarthritis is lacking.

Medication

There have been no randomized controlled trials comparing individual pharmacological agents in the treatment of, specifically, glenohumeral osteoarthritis.

Paracetamol is widely regarded as the cornerstone of pain management in osteoarthritis (American College of Rheumatology Subcommittee on Osteoarthritis Guidelines, 2000). Numerous randomized controlled trials and meta-analysis have confirmed and recommended the use, safety and effectiveness of paracetamol in the first-line management of osteoarthritis of the hip and knee (Pavelka, 2004; Temple et al, 2006). Non-steroidal anti-inflammatory drugs (NSAIDs) have been shown to be more effective but less safe (in terms of gastrointestinal, renal and cardiovascular side effects) than paracetamol and are recommended for use in the presence of acute inflammation on a background of osteoarthritis and/or in cases of moderate to severe pain when paracetamol is not effective.

In those patients in whom paracetamol and NSAIDs fail, studies have shown success with the use of tramadol and more potent opioids such as transdermal fentanyl and oxycodone (Malonne et al, 2004; Markenson et al, 2005; Langford et al, 2006). The authors suggest a similar analgesic ladder for the management of shoulder osteoarthritis in conjunction with the local pain team, but this is extrapolated from their success in other joints and there is no evidence of their efficacy in shoulder osteoarthritis.

Corticosteroids

There have been no studies of the role of intra-articular corticosteroids in the management of glenohumeral osteoarthritis. Meta-analyses of peer-reviewed literature regarding the use of corticosteroid injections for peri-articular and intra-articular shoulder pain document variable success (Blair et al, 1996; Buchbinder et al, 2003).

Local anaesthetic

The authors identified one randomized controlled trial investigating the role of suprascapular nerve blockades (using bupivacaine and methylprednisolone) in chronic shoulder pain secondary to degenerative or rheumatoid disease (Shanahan et al, 2003). Significant improvements in pain, disability and some range of motion scores were achieved at 1, 4 and 12 weeks post-treatment. These can be performed by experienced clinicians using anatomical landmarks or under radiological guidance (Shanahan et al, 2004). Referral to the pain team for suprascapular nerve blockade is a viable treatment option. There have been no studies of the role of intra-articular local anaesthetic in the management of glenohumeral osteoarthritis.

Glucosamine

The apparent mechanism of glucosamine/chondroitin is to favourably shift cartilage biology toward matrix synthesis instead of degradation. While numerous randomized controlled trials have determined the role of glucosamine in slowing disease progression in osteoarthritis in the lower limbs (Pavelka et al, 2002) and spine, its role in glenohumeral osteoarthritis is still to be determined.

Hyaluronic acid

One series has shown an improvement in pain and range of motion following injection of sodium hyaluronate (Itokazu and Matsunaga, 1995). Randomized controlled trials are required to confirm its benefits.

Acupuncture

A Cochrane review of the use of acupuncture in shoulder pain was published in 2005 (Green et al, 2005). This looked at randomized and quasi-randomized controlled trials comparing acupuncture with placebo or other treatment modalities in the management of a range of shoulder conditions including osteoarthritis, adhesive capsulitis and rotator cuff disease. The conclusion was that there was little evidence to conclude if acupuncture was beneficial or harmful in the treatment of the painful shoulder. The little evidence there was suggested that acupuncture may provide relief of symptoms from a painful shoulder over a 2–4-week period.

Physiotherapy

The role of physiotherapy in the treatment of osteoarthritis of the glenohumeral joint is to maintain and if possible improve range of motion, and to strengthen the rotator cuff muscles to maintain glenohumeral stability.

Postoperatively, physiotherapy plays a role in preventing stiffness and increasing mobility. However, a Cochrane review found that the evidence supporting the use of physiotherapy intervention for shoulder pain was poor (Green et al, 2003).

Operative management

Severe pain and disability with accompanying radiological changes in the glenohumeral joint are almost always the indications for joint replacement in patients where conservative treatment has failed or is futile. Occasionally there may be an indication to replace a shoulder because of progressive loss of movement and pain may not necessarily be the most significant factor.

Hemiarthroplasty or total shoulder replacement

Total shoulder replacement is the prosthetic replacement of both the humeral head and the glenoid. A hemiarthroplasty is replacement of the humeral head only, as shown in *Figure 2*.

Controversy exists between the comparative outcome of total arthroplasty *vs* hemiarthroplasty. A meta-analysis of four randomized controlled trials, with similar eligibility and surgical techniques, reported that at a minimum of 2-year follow up total shoulder arthroplasty provided better functional outcome than hemiarthroplasty (Bryant et al, 2005). Following this meta-analysis, a prospective randomized trial with a 2-year follow up showed improvements in both groups but no significant difference in disease specific or quality of life measurements between total shoulder arthroplasty and hemiarthroplasty (Lo et al, 2005). There is one series (which was not randomized) with a 15-year follow up comparing hemiarthroplasty and total shoulder arthroplasty (Perling et al, 2004). There

were significant improvements in long-term pain relief, active abduction and external rotation in each group, but no significant differences between the two. However, there was also a rate of revision surgery for hemiarthroplasties and the authors agree that great care must be taken and alternative treatment considered before proceeding with shoulder hemiarthroplasty or total shoulder replacement in patients under 50 years of age.

In the absence of randomized controlled trials with long-term follow up it is still not possible to conclusively state whether hemiarthroplasty or total shoulder replacement is superior with regards to treatment of osteoarthritis of the glenohumeral joint.

A review article recommended the use of hemiarthroplasty in the following circumstances:

1. When the glenoid is intact
2. When a glenoid component cannot be inserted for technical reasons
3. When the risk of glenoid component loosening and wear is high, as in young, active patients with osteoarthritis (Boileau et al, 2006a).

Resurfacing

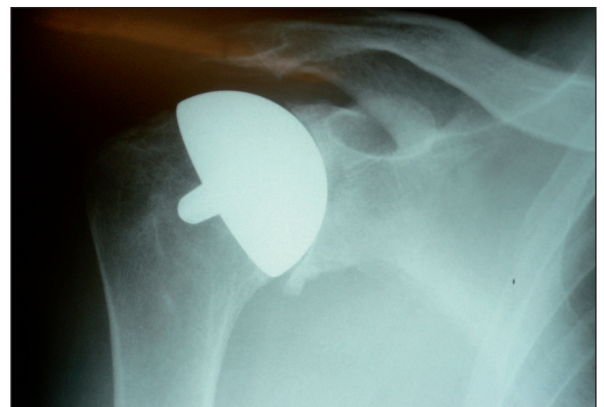
The principle of resurfacing arthroplasty is to replace damaged joint surfaces and restore normal anatomy with minimal resection of bone (Levy and Copeland, 2001). The resurfacing prosthesis uses a peg instead of a long stem for the humeral component (*Figure 3*), removing the need for intramedullary reaming. Resurfacing can be performed in the presence of moderate to severe humeral head erosion. If there is complete destruction of the humeral head, the resurfacing prosthesis cannot be used as it requires some degree of bone stock.

Copeland and colleagues have produced the largest series of shoulder resurfacing to date for osteoarthritis (Levy and Copeland, 2004). They reported the results of 79 cementless surface replacement arthroplasties, 42 total shoulder resurfacings (mean follow up 7.6 years) and 37 hemiarthroplasties (mean follow up 4.4 years). They found an improvement in Constant shoulder scores and active elevation in both the total shoulder resurfacing group and hemiarthroplasty resurfacing group. Four

Figure 2. Plain radiograph of shoulder hemiarthroplasty.

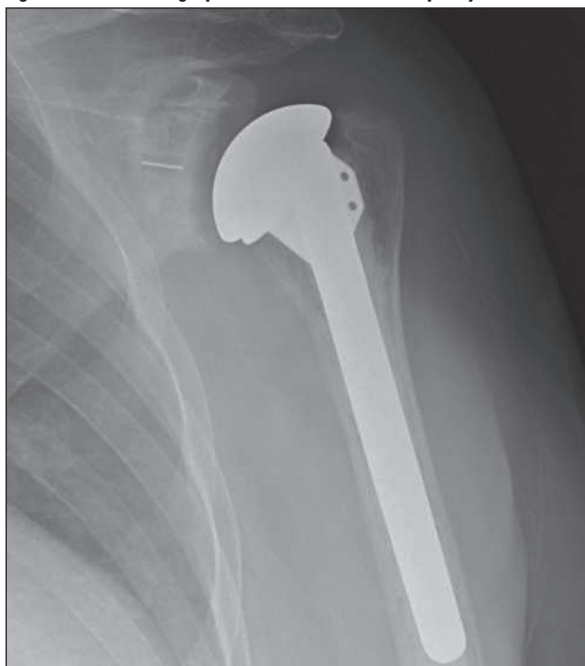

Figure 3. Plain radiograph of surface replacement arthroplasty.

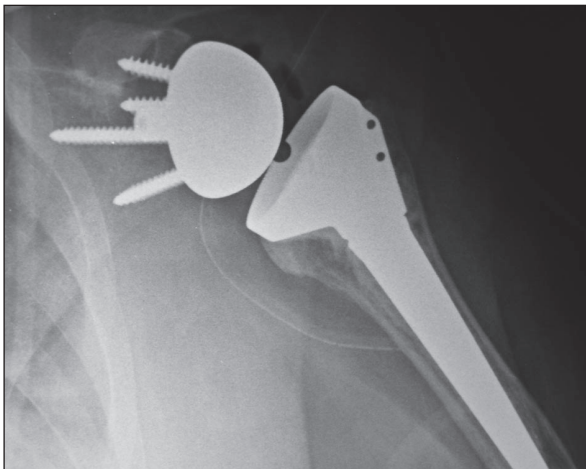


revisions were performed in the total resurfacing group and none in the hemiarthroplasty resurfacing group. Thus, resurfacing hemiarthroplasty is preferred to total shoulder resurfacing. Their findings have been reflected in subsequent series (Thomas et al, 2005). By minimizing bone resection and the extent of intramedullary reaming, the risk of humeral shaft fractures and periprosthetic fractures is theoretically reduced and if future revision surgery is required it is somewhat easier than revising a conventional stemmed total shoulder or hemiarthroplasty. However, there are no randomized controlled trials comparing resurfacing with stemmed total shoulder or hemiarthroplasties to conclude if resurfacing is superior.

Reverse prosthesis

The primary indication for using the reverse shoulder prosthesis is treatment of glenohumeral osteoarthritis secondary to a tear of the rotator cuff muscles (cuff arthropathy). The principle of the reverse shoulder prosthesis is to create a biomechanical environment in which the deltoid functions despite the lack of muscles of the rotator cuff. As the name suggests the normal joint geometry is reversed, with the replacement of the glenoid with a hemisphere (the glenoid becoming the ball) and the humeral head replaced with a humeral component with an almost horizontal head (the humeral head effectively becoming the socket), as shown in *Figure 4*. Studies to date have shown the prosthesis to improve pain and function (Boileau et al, 2006b; Frankle et al, 2006). The largest series to date, with 10-year follow up, showed improvement in pain and function, with a revision rate of 9% (Guery et al, 2006). In other studies, follow up has been short (median 33 months), with reported revision rates of 5–18%. Concerns have been raised about loosening of the glenoid component as a result of loosening around the inferior screws used to secure the glenoid hemisphere and the incidence of periprosthetic fractures. Shoulder replacement in the presence of a rotator cuff tear is a difficult, salvage procedure to relieve pain and hopefully improve function, but which has an associated revision rate. Long-term results from

Figure 4. Plain radiograph of reverse shoulder prosthesis.



multicentre trials are awaited. At present, some manufacturers recommend the prosthesis only for advanced rotator cuff arthropathy in elderly, low-demand patients.

Operative alternatives to joint replacement

Arthroscopic procedures

Arthroscopic debridement or lavage for arthritis has been successfully used in the knee (Hollingsworth et al, 1983). A placebo effect has been suggested in many cases (Moseley et al, 2002). There have been no randomized controlled trials comparing arthroscopic washout of the glenohumeral joint with other treatment modalities. The authors identified one small series which reported improvements in pain and range of movement following arthroscopic washout at an average 34-month follow up but recommended that it is limited to cases that have not responded to conservative measures, where the humeral head and glenoid are concentric and when there is a visible glenohumeral gap on the plain axillary radiograph (Weinstein et al, 2000). Thus there is no proven role for arthroscopic washout in the management of osteoarthritis of the shoulder with further research and clinical trials needed.

Interposition arthroplasty and biological glenoid resurfacing

The first description of the use of biological tissue for interposition arthroplasty in the shoulder was in 1918 by Baer, who used a pig's bladder. More recently, Tillmann and colleagues described an interposition arthroplasty for the rheumatoid shoulder using lyophilized dura mater to cover the articular surfaces. Over a 4–10-year follow up, results were encouraging for pain relief and range of motion, but outcomes worsened beyond 10 years with progressive wear and medialization of the centre of rotation (Fink et al, 2001).

The use of biological glenoid resurfacing was developed in 1988 as an alternative to total shoulder arthroplasty in selected younger patients with primary, post-traumatic or post-reconstruction glenohumeral arthritis, as a method to improve the results of humeral head replacement. Various surfaces have been combined with a hemiarthroplasty, including autogenous fascia lata, Achilles tendon allograft and human dermal collagen allografts as well as meniscal allografts.

Follow up of 2–15 years in a series of thirty-six shoulders has shown encouraging results, with Achilles tendon allograft as the preferred medium (Krishnan et al, 2007).

The future

As with the treatment of osteoarthritis in all other joints and various other pathologies in orthopaedics, and medicine in general, the future lies in biological treatment with gene therapy and stem cell therapy. The gold standard treatments would be identification of the gene(s) that give rise to osteoarthritis and intervention to prevent activation of that gene and/or replacement of degenerate articular cartilage with cartilage regenerated from stem cells.

Conclusions

Osteoarthritis of the shoulder is a painful, debilitating condition. It can have a significant impact upon the quality of life of patients. The approach to management of shoulder osteoarthritis should be evidence based and multidisciplinary. The multidisciplinary team should consist of the shoulder surgeon, the GP, physiotherapists, occupational therapists, social services and the pain team. Conservative measures should be used before proceeding with arthroplasty, but the results of joint replacement are encouraging. More research (specifically randomized controlled trials) is needed into the conservative and surgical management of this pathology, specifically the role of drugs, hyaluronic acid, glucosamine, physiotherapy and long-term follow up of the various shoulder prostheses to determine the superiority and definitive indications and clinical roles for each. **BJHM**

Conflict of interest: none.

American College of Rheumatology Subcommittee on Osteoarthritis Guidelines (2000) Recommendations for the medical management of osteoarthritis of the hip and knee: 2000 update. *Arthritis Rheum* **43**(9): 1905–15

Blair B, Rokito AS, Cuomo F, Jarolem K, Zuckerman JD (1996) Efficacy of injections of corticosteroids for subacromial impingement syndrome. *J Bone Joint Surg Am* **78**: 1685–9

Boileau P, Sinnerton RJ, Chuinard C, Walch G (2006a) Arthroplasty of the shoulder. *J Bone Joint Surg Br* **88**(5): 562–75

Boileau P, Watkinson D, Hatzidakis AM, Hovorka I (2006b) Neer Award 2005: The Grammont reverse shoulder prosthesis: results in cuff tear arthritis, fracture sequelae, and revision arthroplasty. *J Shoulder Elbow Surg* **15**(5): 527–40

Bryant D, Litchfield R, Sandow M, Gartsman GM, Guyatt G, Kirkley A (2005) A comparison of pain, strength, range of motion, and functional outcomes after hemiarthroplasty and total shoulder arthroplasty in patients with osteoarthritis of the shoulder. A systematic review and meta-analysis. *J Bone Joint Surg Am* **87**(9): 1947–56

Buchbinder R, Green S, Youd JM (2003) Corticosteroid injections for shoulder pain. *Cochrane Database Syst Rev* 1: CD004016

Fink B, Sallen V, Guderian H, Tillmann K, R  ther W (2001) Resection interposition arthroplasty of the shoulder affected by inflammatory arthritis. *J Shoulder Elbow Surg* **10**(4): 365–71

Frankle M, Levy JC, Pupello D, Siegal S, Saleem A, Mighell M, Vasey M (2006) The reverse shoulder prosthesis for glenohumeral arthritis associated with severe rotator cuff deficiency. A minimum two-year follow-up study of sixty patients. Surgical technique. *J Bone Joint Surg Am* **88**(Suppl 1 Pt 2): 178–90

KEY POINTS

- Osteoarthritis of the shoulder is increasing in incidence and presentation.
- It presents with pain, stiffness, reduced range of shoulder movement, or a varied combination of these, leading to a reduction in the quality of life of the patient.
- Conservative measures should be considered before offering surgery.
- A wide range of shoulder prosthesis are available: total shoulder replacement, hemiarthroplasty, resurfacing and reverse shoulder prosthesis.
- The gold standard treatment would be regeneration of articular cartilage – the potential of stem cell therapy may, in the future, make this a reality.
- There are no evidence-based national guidelines for the management of osteoarthritis of the shoulder. The National Institute for Health and Clinical Excellence is aiming to publish guidelines for the management of osteoarthritis in adults in 2008.

Green S, Buchbinder R, Hetrick S (2003) Physiotherapy interventions for shoulder pain. *Cochrane Database Syst Rev* 2: CD004258

Green S, Buchbinder R, Hetrick S (2005) Acupuncture for shoulder pain. *Cochrane Database Syst Rev* 2: CD005319

Guery J, Favard L, Sirveaux F, Oudet D, Mole D, Walch G (2006) Reverse total shoulder arthroplasty. Survivorship analysis of eighty replacements followed for five to ten years. *J Bone Joint Surg Am* **88**(8): 1742–7

Hollingworth GR, Ellis RM, Hattersley TS (1983) Comparison of injection techniques for shoulder pain: results of a double blind, randomized study. *Br Med J* **287**: 1339–41

Itokazu M, Matsunaga T (1995) Clinical evaluation of high-molecular-weight sodium hyaluronate for the treatment of patients with periartthritis of the shoulder. *Clin Ther* **17**(5): 946–55

Krishnan SG, Nowinski RJ, Harrison D, Burkhead WZ (2007) Humeral hemiarthroplasty with biologic resurfacing of the glenoid for glenohumeral arthritis. Two to fifteen-year outcomes. *J Bone Joint Surg Am* **89**(4): 727–34

Langford R, McKenna F, Ratcliffe S, Vojtassak J, Richarz U (2006) Transdermal fentanyl for improvement of pain and functioning in osteoarthritis: a randomized, placebo-controlled trial. *Arthritis Rheum* **54**(6): 1829–37

Levy O, Copeland SA (2001) Cementless surface replacement arthroplasty of the shoulder. 5- to 10-year results with the Copeland mark-2 prosthesis. *J Bone Joint Surg Br* **83**(2): 213–21

Levy O, Copeland SA (2004) Cementless surface replacement arthroplasty (Copeland CSRA) for osteoarthritis of the shoulder. *J Shoulder Elbow Surg* **13**(3): 266–71

Lo IK, Litchfield RB, Griffin S, Faber K, Patterson SD, Kirkley A (2005) Quality-of-life outcome following hemiarthroplasty or total shoulder arthroplasty in patients with osteoarthritis. A prospective, randomized trial. *J Bone Joint Surg Am* **87**(10): 2178–85

Malonne H, Coffiner M, Sonet B, Sereno A, Vanderbist F (2004) Efficacy and tolerability of sustained-release tramadol in the treatment of symptomatic osteoarthritis of the hip or knee: a multicenter, randomized, double-blind, placebo-controlled study. *Clin Ther* **26**(11): 1774–82

Markenson JA, Croft J, Zhang PG, Richards P (2005) Treatment of persistent pain associated with osteoarthritis with controlled-release oxycodone tablets in a randomized controlled clinical trial. *Clin J Pain* **21**(6): 524–35

McCormick A, Fleming D, Charlton J (1995) *Morbidity Statistics from General Practice 4th national study. 1991-1992*. HMSO, London

Moseley JB, O'Malley K, Petersen NJ et al (2002) A controlled trial of arthroscopic treatment for osteoarthritis of the knee. *N Engl J Med* **347**(2): 81–8

Office for National Statistics (2008) Population estimates. <http://www.statistics.gov.uk/cci/nugget.asp?id=6> accessed 28 January 2008

Pavelka K (2004) Symptomatic treatment of osteoarthritis: paracetamol or NSAIDs? *Int J Clin Pract* **Oct**(144 Suppl): 5–12

Pavelka K, Gatterova J, Alejarova M, Machacek S, Giacovelli G, Rovati LC (2002) Glucosamine sulfate use and delay of progression of knee osteoarthritis: a 3-year, randomized, placebo-controlled, double-blind study. *Arch Intern Med* **162**(18): 2113–23

Perling JW, Cofield RH, Rowland CM (2004) Minimum fifteen-year follow-up of Neer hemiarthroplasty and total shoulder arthroplasty in patients aged fifty years or younger. *J Shoulder Elbow Surg* **13**(6): 604–13

Shanahan EM, Ahern M, Smith M, Wetherall M, Bresnihan B, FitzGerald O (2003) Suprascapular nerve block (using bupivacaine and methylprednisolone acetate) in chronic shoulder pain. *Ann Rheum Dis* **62**(5): 400–6

Shanahan EM, Smith MD, Wetherall M, Lott CW, Slavotinek J, FitzGerald O, Ahern MJ (2004) Suprascapular nerve block in chronic shoulder pain: are the radiologists better? *Ann Rheum Dis* **63**(9): 1035–40

Temple AR, Benson GD, Zinsenheim JR, Schweinle JE (2006) Multicenter, randomized, double-blind, active-controlled, parallel-group trial of the long-term (6-12 months) safety of acetaminophen in adult patients with osteoarthritis. *Clin Ther* **28**(2): 222–35

Thomas SR, Wilson AJ, Chamberlain A, Harding I, Thomas M (2005) Outcome of Copeland surface replacement shoulder arthroplasty. *J Shoulder Elbow Surg* **14**(5): 485–91

Weinstein DM, Bucchieri JS, Pollock RJ, Flato EL, Bigliani LU (2000) Arthroscopic debridement of the shoulder for osteoarthritis. *Arthroscopy* **16**(5): 471–6