

Acute management of croup in children

Introduction

The expiratory wheeze of an obstructing lower airway in acute severe asthma is a common presentation in the emergency department and most physicians are well versed with the basic principles of initial assessment and management.

However, the child presenting with croup can be a daunting prospect for the physician in the emergency department as the acute management of upper airway obstruction is more unfamiliar territory. The primary concern is that partial upper airway obstruction may lead to fatal complete airway obstruction. Therefore, it is of prime importance that the junior doctor in the emergency department has some insight into the basic principles of initial assessment and management until specialist help arrives.

Terminology

Upper airway obstruction can result in various airway noises depending upon the site of obstruction.

Stridor is defined as the variably pitched noise of breathing associated with a partially obstructed upper airway. This is usually inspiratory but may also be expiratory or biphasic. Inspiratory stridor suggests an extrathoracic lesion. It occurs primarily with obstruction of the glottis but also with subglottic oedema (the latter may also be biphasic). Biphasic stridor implies involvement of trachea or major bronchi whereas expiratory sounds are associated with lower order bronchi or bronchioles, i.e. an intrathoracic lesion.

In contrast the term stertor is also used to describe a type of coarse inspiratory stridor or snoring sound, usually caused by

vibration of flaccid tissue or the presence of fluid in the nasopharynx.

Recognizing stridor is important for the initial assessment of the child presenting with croup; the type of stridor is less important as the initial management is the same and further assessment can be made by senior clinicians.

Aetiology and clinical course

Acute laryngo-tracheobronchitis is a viral inflammation of the upper respiratory tract (most commonly a parainfluenza virus; Marx et al, 1997) that can lead to upper airway obstruction. It is most common in children between the age of 6 months and 3 years. The disease is often mild and self-limiting and resolves without any active intervention. However, there can be significant progressive inflammation and subglottic swelling (especially around the level of the cricoid cartilage) which can lead to significant life-threatening airway obstruction.

Airway resistance is proportional to the fourth power of the radius. In this way, airway swelling in small children has a much greater impact than in adults as evidenced by the severe upper airway obstruction seen in viral croup compared to the much milder tracheitis and hoarseness caused by the same virus in an adult. Secondary bacterial tracheitis may also complicate an initial viral infection resulting in an accumulation of thick viscid purulent secretions within the airway which the child is unable to clear, further exacerbating the airway obstruction.

History and examination

The child with croup presents with a gradual development of stridor, hoarseness and a typical 'seal-like' barking cough. The parent may report a history of preceding

upper respiratory tract infection before symptoms of croup appear. The child may be afebrile and as a rule of thumb does not generally look as toxic and unwell as the acute epiglottitis patient (*Table 1*). Croup symptoms are typically worse at night which may be a result of circadian fluctuations in endogenous serum cortisol (Bjornson and Johnson, 2008).

Differential diagnosis

The physician must be aware of other pathology that may present in a similar fashion with symptoms of stridor and respiratory distress (*Table 2*). It is particularly important to be able to differentiate a presentation of croup from acute epiglottitis. The child with acute epiglottitis is usually toxic, drooling and unable to swallow. Cough is not a prominent symptom unlike the child with croup where the barking cough is a typical feature.

The incidence of acute epiglottitis has decreased significantly since the introduction of *Haemophilus influenzae* B vaccine (Hib vaccine). The child with a peritonsillar or parapharyngeal abscess may present in a similar fashion. Neck stiffness and unilateral neck swelling or lymphadenopathy are suspicious findings that may suggest abscess formation. When there is significant supraglottic swelling in patients with acute epiglottitis or peritonsillar or parapharyngeal abscess, the child may extend the neck and lean forward in an attempt to open the airway.

Foreign body aspiration may be a witnessed event or may present with sudden onset stridor and respiratory distress, choking or gagging in a previously well child. Hoarseness and barking cough are usually absent.

The child suffering from an anaphylactic reaction may also present with stridor

Mr Irfan Syed is Specialist Registrar ST3,

Ear, Nose and Throat Surgery, Torbay General Hospital, Torquay TQ2 7AA,

Mr Peter Tassone is Specialist Registrar,

Ear, Nose and Throat Surgery, Addenbrooke's Hospital, Cambridge, **Dr Peter Sebire** is

Consultant Paediatrician and

Mr Nigel Bleach is Consultant

Otolaryngologist, Wexham Park Hospital, Slough

Correspondence to: Mr I Syed

Table 1. Distinguishing features of croup and acute epiglottitis

	Acute epiglottitis	Croup
Speed of onset	Rapid onset	Slower onset
Cough	Cough not prominent symptom	Barking cough
Swallowing	Drooling – unable to swallow/speak	Usually swallowing normal
Temperature	Looks toxic, pyrexial	Usually not as toxic, pyrexial

Table 2. Differential diagnosis

Infection	Acute epiglottitis
	Bacterial tracheitis
	Retropharyngeal or peritonsillar abscess
	Diphtheria
Inflammation	Anaphylaxis
	Angio-neurotic oedema
Foreign body aspiration	

and respiratory distress. Distinguishing features that are suggestive of anaphylaxis include urticaria, facial swelling and exposure to a known precipitating allergen. Bronchospasm may result in expiratory wheeze in addition to upper airway obstruction.

Laryngeal diphtheria is extremely rare because there has been widespread immunization. There is a several day history of pharyngitis (which has a typical membranous appearance) and low grade fever with subsequent development of barking cough, hoarseness and stridor.

Management

If the symptoms and signs suggest croup then the most important assessment is the initial assessment of severity. The degree of stridor should not be used in isolation as a reliable estimate of the level of airway obstruction. A child with soft stridor may have impending respiratory collapse. There are several scoring schemes and grading systems, e.g. Westley score, that are used by specialists but the most important clas-

Table 3. Assessment of severity of croup in the emergency department

Mild croup	Occasional barking cough
	No or minimal stridor at rest
	No or minor suprasternal retraction
Moderate croup	Persistent barking cough
	Stridor at rest
	Some chest wall recession at rest
Severe croup	Stridor at rest
	Marked chest wall recession
	Distressed or agitated
Note that cyanosis and fatigue are late features and indicate imminent respiratory collapse	

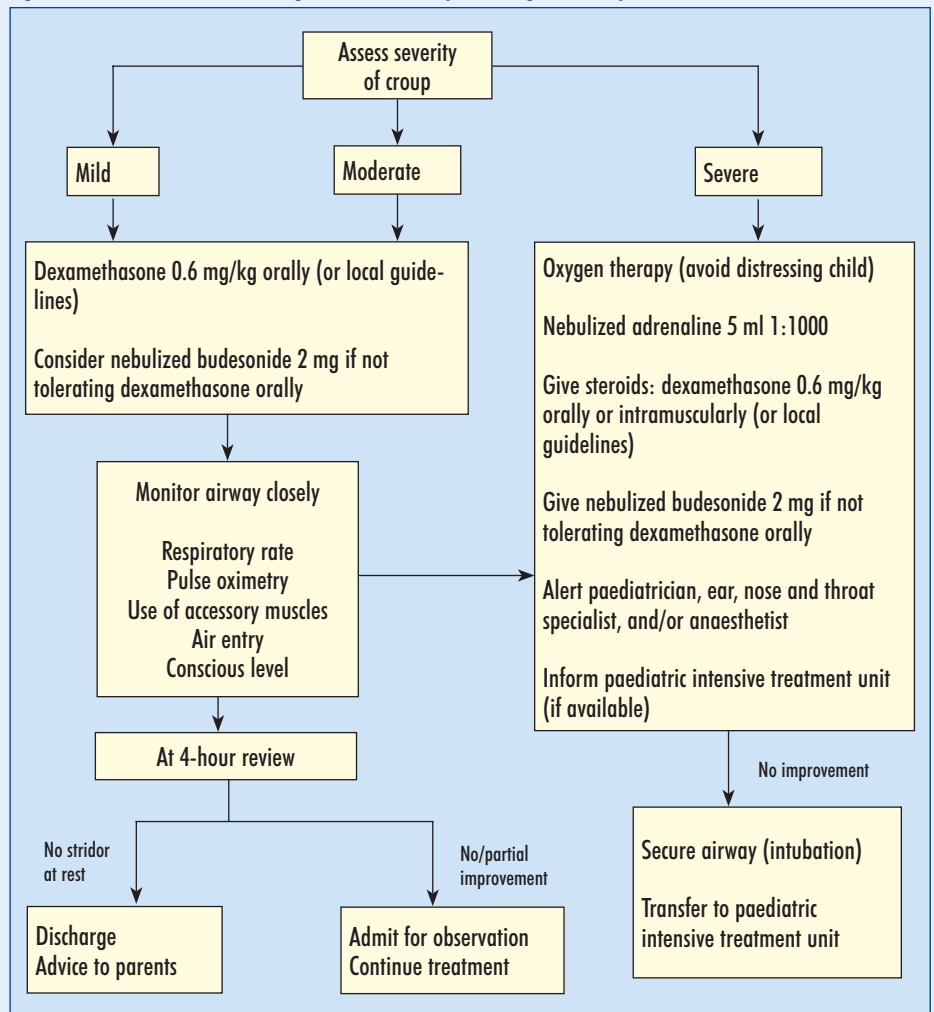
sification that affects management is establishing whether the airway compromise is mild, moderate or severe (Table 3) (Westley et al, 1978).

Figure 1 summarizes the acute management of croup. The principles are to make a rapid assessment, keep the child calm and to initiate steps to relieve the obstruction and ensure adequate oxygenation of the patient. Oxygen should be provided if there is respiratory distress, by a parent holding the delivery device close to the child's face. Heliox has been shown in some small trials to improve clinical croup scores, although there is no evidence of significant clinical benefits that would merit advocating universal use (Terregino et al, 1998). Steroids play a part in the management of stridor regardless of severity. It has been estimated that the use of corticosteroids in children with severe croup translates to a fivefold reduction in the need for intubation.

Dexamethasone is the most commonly used glucocorticoid and there is some evidence that it is more effective than prednisolone for mild to moderate croup (Sparrow and Geelhoed, 2006). Oral administration is the route of choice as this is less likely to distress the patient and there is no significant superior efficacy with an intramuscular dose (Bjornson et al, 2004). A range of doses between 0.15 and 0.6 mg/kg are featured in trials but none have been of sufficiently high power to allow conclusive differences to be established (Johnson, 2007). The attending physician should make him/herself aware of local hospital guidelines with regard to steroid dosages.

The role of nebulized budesonide in the management of croup is controversial. Nebulized steroids have the advantage of being deposited in the upper airway, have minimal systemic effects, and may have a more rapid onset of action than oral steroids (Klassen et al, 1996). However, close

Figure 1. Guidelines for the management of a child presenting with croup.



application of the face mask to the child is required for adequate drug delivery (Everard et al, 1992). Therefore, using nebulized therapy risks increasing distress to the child which may exacerbate stridor. A 1 mg nebulized dose of budesonide costs around £2.23, whereas 2 mg dexamethasone (soluble tablet) costs around £0.16 (Joint Formulary Committee, 2008).

Oral dexamethasone has been shown to be as effective as nebulized budesonide at reducing symptom severity in children with moderate to severe croup. In addition, oral dexamethasone alone is as effective as oral dexamethasone plus nebulized budesonide at reducing severity of symptoms after 4 hours in children with moderate to severe croup (Klassen et al, 1996; Johnson, 2007). Based on this evidence the authors advocate the use of budesonide when the child with croup is not tolerating oral dexamethasone.

Nebulized adrenaline causes vasoconstriction of the subglottic mucosa which reduces oedema and swelling. Nebulized racemic adrenaline has been shown to improve croup scores within 10–30 minutes of initiation in several randomized controlled trials (Taussig et al, 1975; Kristjánsson et al, 1994; Marx et al, 1997). Only L-adrenaline is available in the UK but this is cheaper and has been shown to be as effective as racemic adrenaline in the treatment of croup (Waisman et al, 1992).

The authors would advocate the use of nebulized adrenaline 5 ml (1 in 1000 solution) in the treatment of severe croup.

Cardiac monitoring is essential because of the risk of cardiac ischaemia – electrocardiography leads can be applied to the back to avoid further distressing the child. Nebulized adrenaline is short acting and can be repeated every 15–20 minutes.

A patient with severe croup requires urgent senior review by the ear, nose and throat specialist and anaesthetist. Early referral is imperative. It is also useful for the ear, nose and throat specialist and anaesthetist to be made aware of patients with moderate croup and for them to be informed if the patient shows no signs of improvement after delivering steroids. **BJHM**

Conflict of interest: none.

- Bjornson CL, Klassen TP, Williamson J, et al; for the Pediatric Emergency Research Canada Network (2004) A randomized trial of a single dose of oral dexamethasone for mild croup. *N Engl J Med* **351**: 1306–13
- Bjornson CL, Johnson DW (2008) Croup. *Lancet* **371**: 329–39
- Everard ML, Clark AR, Milner AD (1992) Drug delivery from jet nebulisers. *Arch Dis Child* **67**: 586–91
- Johnson D (2007) BMJ Clinical Evidence: Child Health – Croup. (http://staging.clinicalevidence.com/ceweb/conditions/chd/0321/0321_11.jsp accessed 6 December 2008)
- Joint Formulary Committee (2008) *British National*

Formulary 56. BMJ Publishing Group Ltd and RPS Publishing, London

- Klassen TP, Watters LK, Feldman ME et al (1996) The efficacy of nebulised budesonide in dexamethasone-treated out-patients with croup. *Pediatrics* **97**: 463–6
- Kristjánsson S, Berg-Kelly K, Winsö E (1994) Inhalation of racemic adrenaline in the treatment of mild and moderately severe croup. Clinical symptom score and oxygen saturation measurements for evaluation of treatment effects. *Acta Paediatr* **83**(11): 1156–60
- Marx A, Torok T, Holman R, Clarke M, Anderson L (1997) Pediatric hospitalizations for croup: biennial increases associated with human parainfluenza virus 1 epidemics. *J Infect Dis* **176**: 1423–7
- Sparrow A, Geelhoed G (2006) Prednisolone versus dexamethasone in croup: a randomised equivalence trial. *Arch Dis Child* **91**: 580–3
- Taussig LM, Castro O, Beaudry PH, Fox WW, Bureau M (1975) Treatment of laryngotracheobronchitis (croup). Use of intermittent positive-pressure breathing and racemic epinephrine. *Am J Dis Child* **129**(7): 790–3
- Terregino C, Nairn S, Chansky M (1998) The effect of heliox on croup: a pilot study. *Acad Emerg Med* **5**: 1130–3
- Waisman Y, Klein BL, Boenning DA et al (1992) Prospective randomized double-blind study comparing L-epinephrine and racemic epinephrine aerosols in the treatment of laryngotracheitis (croup). *Pediatrics* **89**: 302–6
- Westley CR, Cotton EK, Brook JG (1978) Nebulized racemic epinephrine by IPPB for the treatment of croup: a double blind study. *Am J Dis Child* **132**: 484–7

KEY POINTS

- Rapid assessment of severity and avoiding causing distress to the child are extremely important.
- Maintaining the airway and early institution of steroid therapy is key regardless of croup severity.
- All patients with severe croup and those not responding to initial measures should be referred for specialist review.