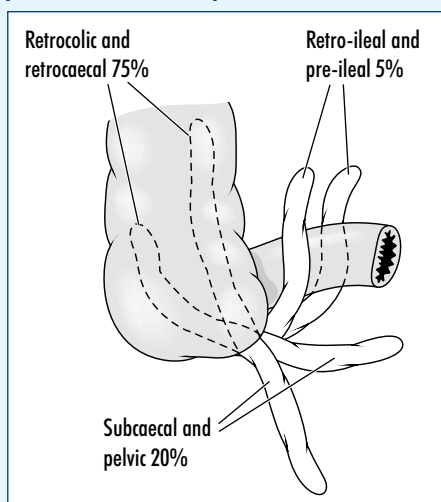


# The applied anatomy of appendicectomy

Acute appendicitis is a common surgical emergency and appendicectomy is the most commonly performed emergency abdominal operation in the western world. The satisfactory performance of this operation depends on a clear understanding of the anatomy of the appendix and its variations. In man, the appendix is a vestigial organ, small and functionless, compared with the large bulky structure seen in herbivores. In these grass-eating animals the mucosa of the appendix secretes the enzyme cellulase, which digests the cellulose walls of the ingested plant food. The appendix arises from the postero-medial aspect of the caecum, about 2.5 cm inferior to the ileocaecal valve (*Figure 1*). Its length varies greatly, from a tiny structure 12 mm long to an impressive 22 cm. One patient the author operated upon had an appendix which passed from its right iliac fossa origin on the caecum across the lower abdomen to reach the sigmoid colon, against which its perforated gangrenous tip was adherent.

In the fetus the appendix is a direct out-pouching of the caecum, but differential overgrowth of the lateral caecal wall results in its medial displacement. Rare cases of a double appendix have been recorded. The

**Figure 1. The anatomy of the appendix and the positions in which it may be found.**

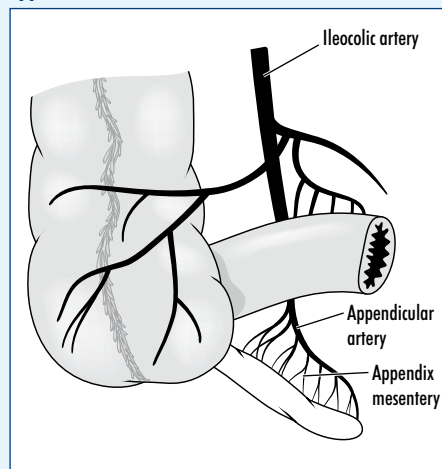


**Professor Harold Ellis** is Clinical Anatomist, Guy's, King's and St Thomas' School of Biomedical Science, London SE1 1UL

position of the appendix is very variable – it has been called 'the only organ with no fixed anatomy' (*Figure 2*). Most often, it is found lying behind the caecum (the retro-caecal appendix) either lying freely within the peritoneal cavity or sometimes hidden beneath the peritoneal covering of the caecum. A long appendix may extend more proximally, and come to lie in the right paracolic gutter, or extraperitoneally behind the ascending colon (retrocolic) and, if long enough, may abut against the duodenum or the lower pole of the right kidney. The appendix may be found just below the caecum (subcaecal), or hanging down into the true pelvis (pelvic). Uncommonly it extends behind or, even less commonly, in front of the terminal ileum (retro-ileal and ante-ileal).

The appendix is supplied by a solitary end artery – the appendicular branch of the ileocolic artery, which itself is derived from the superior mesenteric artery. The accompanying appendicular vein drains to the superior mesenteric vein, which joins the splenic vein to form the portal vein. The appendicular vessels pass to the organ in the appendix mesentery, which descends behind the ileum as a triangular fold (*Figure 2*). Another peritoneal sheet, termed the ileocaecal fold, is often present and passes to the appendix or to the base of the caecum from the front of the ileum. This ileocaecal fold is termed the 'bloodless fold of Treves', although, in fact, it may quite often contain a small vessel and

**Figure 2. The arterial blood supply of the appendix.**



prove to be far from bloodless if divided. (Sir Frederick Treves, of the Royal London Hospital, drained the appendix abscess of King Edward VII the day before he was due to be crowned in 1902, and did much to 'popularize' appendicectomy.)

Unlike the rest of the alimentary canal, which is supplied along its various mesenteries by a series of richly anastomosing blood vessels, the appendicular artery is an end-artery and represents the entire vascular supply of the appendix. It runs first in the edge of the appendicular mesentery and then, distally, along the wall of the appendix. Acute infection of the appendix may result in thrombosis of this vessel. The combination of ischaemia and infection, unless the appendix is removed, results in gangrene of the appendix, which then ruptures – either freely into the peritoneal cavity, with resultant general peritonitis or, if wrapped in inflammatory adhesions (to the omentum, for example), with the formation of a localized appendix abscess. It is for this anatomical reason that early operation in a case of acute appendicitis is mandatory.

In passing, note the contrast with the pathology of acute cholecystitis. The gall bladder, in addition to its blood supply from the cystic artery, a branch of the hepatic artery, has a rich collateral supply from a series of vessels passing to it from its liver bed. Gangrene of the gall bladder is an uncommon complication of an attack of acute cholecystitis since it is unusual for its blood supply to be lost in the inflammatory process – most cases can therefore be treated conservatively, with an excellent chance that the inflammatory process will subside.

The lumen of the appendix is relatively wide in the infant and is frequently totally occluded in old age. Since obstruction of the lumen of the appendix, by a faecolith or an inflammatory kink, is the usual predisposing factor in an attack of acute appendicitis, it is not surprising that acute appendicitis should be uncommon at the two extremes of life.

## Appendicectomy

Although the appendix can be removed at laparoscopic surgery, the majority of cases of acute appendicitis are still treated by

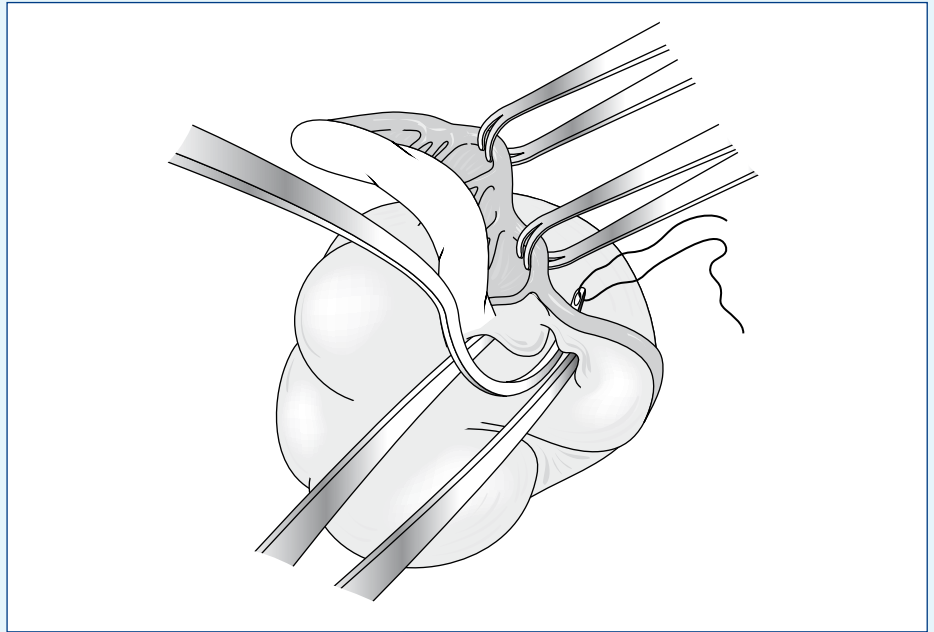
open operation. The details of the incisions used to open the abdomen have been described and illustrated in a previous article in this series (Ellis, 2010). Usually a skin crease or oblique right iliac fossa muscle split incision is used, which gives excellent access to the caecum and appendix. In a difficult case, the incision can be enlarged by splitting the lateral muscles of the abdominal wall. Occasionally, when the surgeon is exploring the 'acute abdomen' and when not confident of the diagnosis, the lower mid-line abdominal incision may be used.

On opening the peritoneal cavity, the caecum is identified, held in a wet swab and delivered into the wound. The appendix may become immediately apparent. If not, it can be found by gently palpating with the index finger behind and below the caecum. If still not obvious, it can be located by tracing the taeniae coli along the caecal wall; they come together at the base of the appendix. If the appendix is lying tucked behind the ascending colon, it may be necessary to mobilize this part of the colon by incising the avascular peritoneal attachment of this part of the colon to the posterior abdominal wall laterally along the so-called 'white line' of this adherence.

The appendix mesentery, containing the appendicular vessels, is divided between artery forceps or by passing a ligature through its base and ligated – if long, several ties may be necessary (Figure 3). The base of the appendix is then divided between artery clamps, the stump ligated and invaginated into the caecum, although some surgeons leave the stump uninvaginated (Figure 4). Usually this operation is a straightforward procedure, which a competent senior house officer should be able to carry out neatly under supervision, but removal of a necrotic appendix in a grossly obese patient who has a long appendix with its tip hidden behind the ascending colon may require a good deal of skill and experience. Occasionally it will be found necessary to commence the removal by dividing the stump of the appendix first between clamps and then to dissect the organ free from the proximal end towards its tip – 'retrograde appendicectomy'. **BJHM**

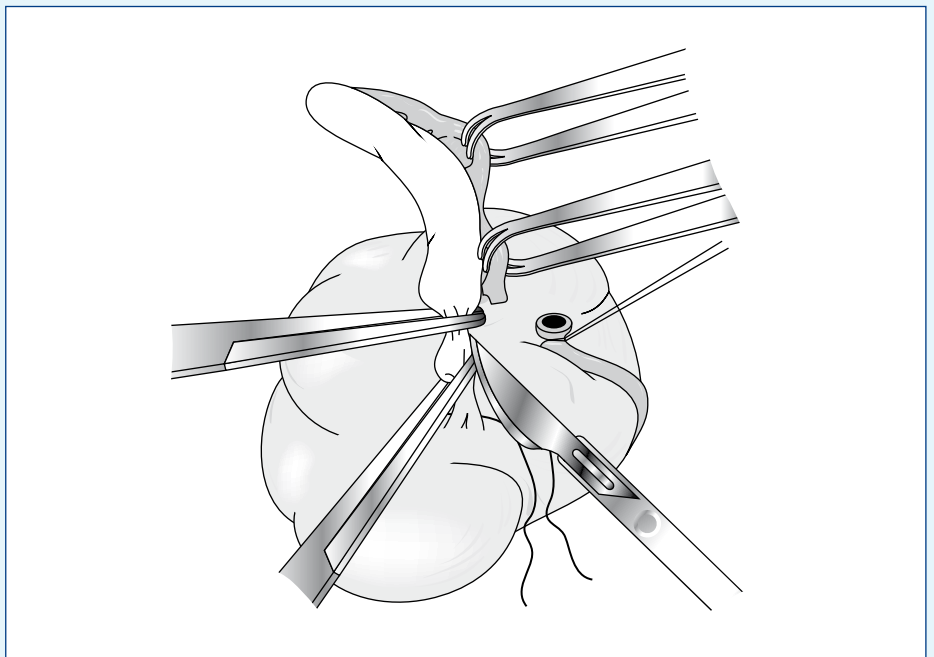
*Conflict of interest: none.*

Ellis H (2010) Applied anatomy of abdominal incisions. *Br J Hosp Med* 71(3): M36–M37



**Figure 3. Ligation of the appendix mesentery.**

**Figure 4. Division of the appendix stump between artery forceps.**



## KEY POINTS

- Acute appendicitis is common and appendicectomy is the most commonly performed emergency abdominal operation in the western world.
- The appendix varies widely in its length and is very variable in its pathology.
- Most commonly the appendix lies behind the caecum or projects further behind the ascending colon. Less often it is subcaecal or pelvic, and occasionally is pre- or post-ileal.
- Appendicectomy involves ligation of the appendix mesentery and division, ligation and (usually) invagination of the appendix stump.