

Tonsillectomy: a routine procedure?

Introduction

Tonsillectomy is one of the most common elective otolaryngology operations, often undertaken by relatively junior otolaryngology trainees. The most common complication is postoperative haemorrhage, with overall rates in the region of 3%, irrespective of technique. Bleeding is often non-life threatening with the vast majority undergoing an uneventful course. Although extremely rare, death and stroke resulting from tonsillectomy have been described and are still unfortunately experienced in current practice (Windfuhr, 2003).

This article presents the case of a young patient listed for an elective tonsillectomy, which was cancelled intraoperatively following the discovery of an abnormal pulsation on the pharyngeal wall. The case highlights a number of important points, including the potential risks that can occur in so-called 'routine surgery' and the importance of a thorough assessment of patient anatomy before starting any operation.

Discussion

Tonsillectomy is considered a safe procedure with a low risk profile. Reported mortality figures are exceedingly low, ranging from 1 in 3000 to 1 in 27 000 (Dunne et al, 2003; Carvalho et al, 2007). Haemorrhagic injuries resulting from vascular anomalies are the exception rather than the rule. In a series from Germany, examining fatalities post-tonsillectomy over a 26-year period, 29 deaths were reported, with 18 of these occurring in children (Wasserman et al, 2006). In post-mortem studies, the facial artery was the commonest vessel injured, followed by the pharyngeal branch of the descending palatine, with damage to the external carotid artery occurring in only a single case.

Mr Priyamal Silva is Specialist Registrar in Otolaryngology, **Mr Vinay Varadarajan** is Specialist Registrar in Otolaryngology and **Mr Sean Loughran** is Consultant Otolaryngologist in the Academic Department of Otolaryngology and Head and Neck Surgery, Manchester Royal Infirmary, Manchester M13 9WL

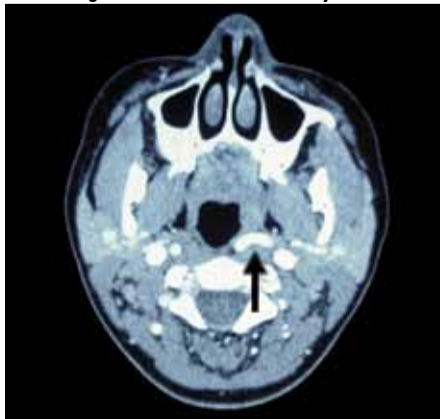
Correspondence to: Mr P Silva

While anatomy textbooks describe the cervical course of the internal carotid artery as running a direct course to the skull base without branching, in cadaveric studies a third exhibited anomalous anatomy, with the internal carotid artery in direct contact with the tonsillar fossa in 3% (Paulsen et al, 2000).

If large vessel injury does occur, then endovascular management may be possible in a stable patient. In the exsanguinating haemodynamically unstable patient, full resuscitative measures coupled with intraoperative attempts to achieve haemostasis (including carotid artery ligation) are the only real options available.

Ultimately prevention is better than cure, but correct preoperative assessment, awareness of such vascular anomalies and meticulous dissection will all reduce the chance of an unfortunate outcome.

Figure 1. Axial computed tomography angiogram illustrating left internal carotid artery.

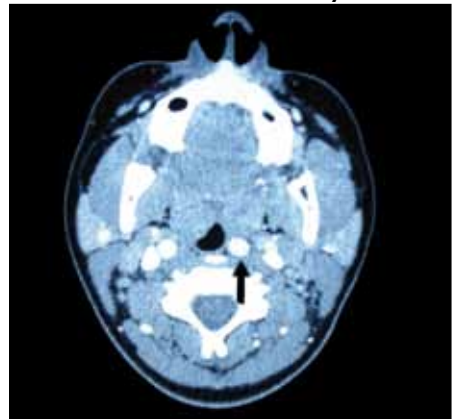


Conclusions

Careful examination of every patient before any surgical procedure is mandatory, to avoid potential rare pitfalls. While tonsillectomy is considered a routine surgical procedure, this case illustrates that this may not necessarily be so. **BJHM**

- Carvalho KS, Edwards-Brown M, Golomb MR (2007) Carotid dissection and stroke after tonsillectomy and adenoidectomy. *Pediatr Neurol* 37(2): 127–9
- Dunne AA, Granger O, Folz BJ et al (2003) Peritonsillar abscess- critical analysis of abscess tonsillectomy. *Clin Otolaryngol* 28: 420–4
- Paulsen F, Tillmann B, Christofides C et al (2000) Curving and looping of the internal carotid artery in relation to the pharynx: Frequency, embryology and clinical implications. *J Anat* 197: 373–81
- Wasserman JM, Sclafani SJA, Goldstein NA (2006) Intraoperative evaluation of a pulsatile oropharyngeal mass during adenotonsillectomy. *Int J Pediatr Otorhinolaryngol* 70: 371–5
- Windfuhr JP (2003) Lethal post-tonsillectomy hemorrhage. *Auris Nasus Larynx* 30: 391–6

Figure 2. Further section demonstrating submucosal left internal carotid artery.



Case Report

A 20-year-old woman was referred with a 2-year history of recurrent tonsillitis. Her past medical history was unremarkable. After discussion with the patient about the options, including the risks of the procedure, she was placed on the waiting list for a tonsillectomy. Preoperative screening tests and careful examination were normal, and she was admitted as scheduled.

Following routine general anaesthetic induction and intubation, a gag was placed into the mouth to allow visualization of the oropharynx. The surgeon examined the oropharynx and noted an abnormal pulsatile structure on the posterior pharyngeal wall, adjacent to the left tonsil and close to the intended plane of dissection. This was not seen previously in the clinic setting. A vascular anomaly was suspected, and in view of the risk for potentially intractable haemorrhage, the surgeon decided to cancel the procedure and wake the patient up. The patient was extubated uneventfully and told what had happened. A computed tomography angiogram was subsequently requested, demonstrating effacement of the left oropharyngeal surface by the presence of a prominent medially deviated internal carotid artery lying immediately submucosal (Figures 1 and 2). The patient was counselled appropriately and elected for conservative management.