

Full body low radiation radiography using Lodox Statscan

Lodox Statscan provides high-speed, high-quality, low radiation, full body imaging in a single scan, combined with three-dimensional reconstructive and zooming functionality. Several trauma centres have incorporated it into their advanced trauma life support protocol. This review gives a brief overview of the system.

The initial evaluation of a critically injured poly-trauma patient is a challenging task and every minute can make the difference between life and death. Mortality decreases as the time from injury to diagnosis and treatment is shortened (Gens, 2003). Assessment of trauma patients has evolved over recent years, as a result of improved understanding of the mechanisms that contribute to morbidity and mortality in trauma, and this has led to the development of advanced trauma life support (American College of Surgeons Committee on Trauma, 2004; Moore et al, 2004).

Radiographic imaging studies provide crucial diagnostic data that guide the initial evaluation. The sequence and timing of these studies are important. Staging the imaging studies so that life-saving interventions are not impeded, and ensuring that the patient is haemodynamically stable enough to tolerate transfer to the radiology suite are crucial and can, at times, prevent obtaining those studies (Dries, 2010).

Lodox Statscan is a digital X-ray machine with a low dose of radiation exposure that provides rapid (13 seconds) whole-body scans. Owing to its extremely low radiation dose, it permits trauma and emergency staff to continue to provide critical life support while images are obtained without interrupting their life-saving and resuscitation procedures. The system was first developed for the South African mining industry, where it was used in an effort to detect hidden diamonds.

Medical imaging consultants involved in the development of this technology were quick to identify the digital system's potential for use in emergency and trauma venues. With the help of De Beers Consolidated Mines, Industrial Development Group of South Africa, and Netcare Hospital Management, Lodox Systems modified the Statscan for use in trauma bays and emergency departments throughout the world. The first medical use was reported at Groote Schuur Hospital, Cape Town in 1999. The quality of Lodox Statscan images was comparable to that of conventional radiographs, and this culminated in the unit being approved for diagnostic use by the United States Food and Drug Administration in 2002 and the European Union in 2004. So far, about 35 trauma centres worldwide have incorporated this technology into their emergency management protocols.

This article describes the advantages, efficiency, reliability, sensitivity and specificity of Lodox Statscan, as well as its use in trauma patients.

System description

The Lodox Statscan has an X-ray tube mounted on one end of a C-arm (*Figure 1*), which emits a low-dose, collimated fan beam of X-rays. The X-ray detector unit is attached to the opposite end of the C-arm and consists of scintillator arrays optically linked to charge-coupled devices (Deyle et al, 2009). The C-arm travels along the table length at up to 138 mm/s, and a whole-body anterior-posterior scan takes 13 seconds. The C-arm can be rotated axially around the patient to any angle up to 90°. If desired, subsequent whole-body, horizontal beam, shoot-through lateral, erect and oblique views can be taken. The unit includes an integrated docking resuscitation table to eliminate transfer from and to the trolley and allow complete patient access for ongoing resuscita-

Figure 1. Lodox Statscan at Inselspital resuscitation bay.

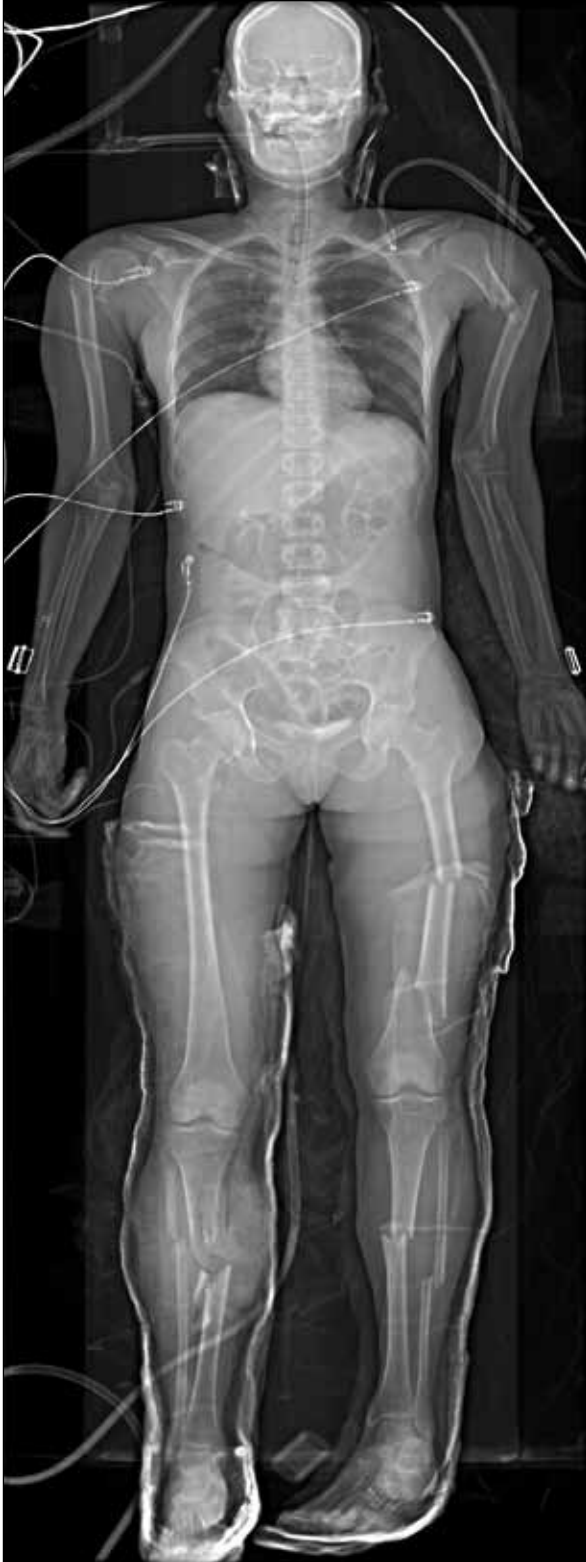

Dr Malek Tabbara is Visiting Clinical Fellow, **Dr Dimitrios S Evangelopoulos** is Visiting Consultant, **Professor Heinz Zimmermann** is Chair and **Dr Aristomenis Exadaktylos** is Senior Lecturer/Clinical Lead in the Department of Emergency Medicine, Inselspital, Bern University Hospital, Bern, 3010, Switzerland

Correspondence to: Dr M Tabbara

tion. The whole-body images, which can be enlarged for better viewing, are immediately available via a conventional personal computer and picture archiving and communication system.

Figure 2. A whole body antero-posterior Lodox Statscan view, showing fractures of the right tibia, right fibula, left tibia, left fibula, left femur and left humerus.



The digital radiation dose relative to the conventional dose varies from 72% (chest) to 2% (pelvis), with a simple average of 6% (Parry et al, 1999; Beningfield et al, 2003). The radiation skin-entry dose averages 36 mrem (range 18–67 mrem), compared with a conventional dose of 591 mrem (range 20–2280 mrem) (Mervis et al, 2005). Effective doses are between 9% and 75% of the United Nations Scientific Committee Report on the Effects of Ionizing Radiation Doses for Standard Examinations (Irving et al, 2008).

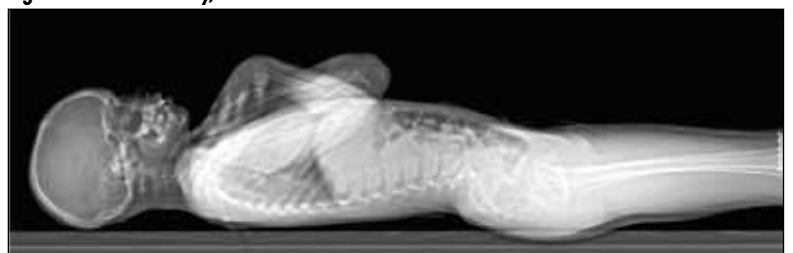
Adult trauma patients

The use of Lodox Statscan was first described in adult trauma patients by Beningfield et al (2003). Their study, conducted on 39 patients at the Trauma Unit of Groote Schuur Hospital, Cape Town, during the period 1 June 1999 to 30 November 2001, showed that Lodox Statscan had equivalent diagnostic performance and overall functionality to conventional radiography. They also concluded that it was promising for clinical and radiographic work, since it provided physicians with easy digital imaging of any region, up to a full body view, with minimal interruption of the patient's management.

Boffard et al (2006) conducted a trial of Lodox Statscan in major trauma and compared it to conventional radiography. Their study included 115 patients. They demonstrated that Lodox Statscan was able to replace conventional radiography, especially in the anterior-posterior plane of the chest, pelvis and identification of long bone fractures and metallic foreign bodies (Figures 2 and 3). They also found that, because of its effectiveness and speed of imaging, Lodox Statscan could shorten the total time taken to resuscitate a patient with major injury. They concluded that, given its significantly lower radiation (only 6% of conventional radiography) and its imaging speed, Lodox Statscan could have an important role to play in the initial management of the trauma patient, offering a dramatic reduction in the time spent in the trauma bay.

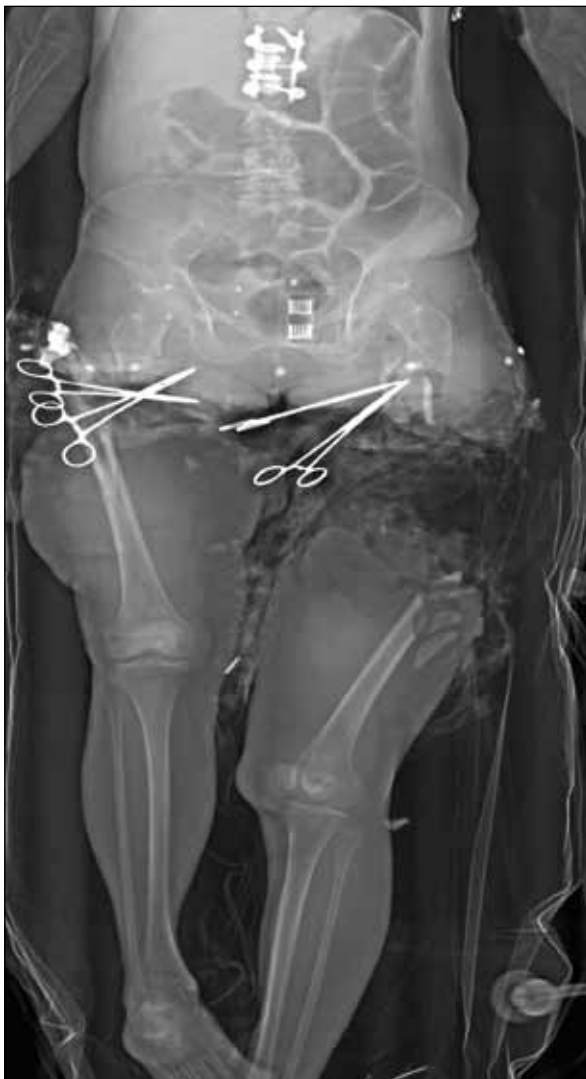In a case review study, Amirlak et al (2009) reported that Lodox Statscan was beneficial in expediting the radiological processes in the golden hour of trauma patients. They concluded that Lodox Statscan is not only faster, but potentially safer, more user-friendly, and has a greater ease of image transmissibility than conventional techniques (Figure 4).

Figure 3. A whole body, thoraco-abdominal lateral Lodox Statscan view.



Fu et al (2008) showed that Lodox Statscan can provide an alternative to conventional radiography in rapid survey of patients with multiple gunshot injuries. They concluded that haemodynamically unstable patients with multiple gunshot wounds could undergo a quick preoperational assessment of the path of the projectile using Lodox Statscan without interrupting resuscitation, making further surgical management more confident and efficient. Mulligan and Flye (2006) showed that Lodox Statscan is a useful tool for rapid screening of polytrauma patients. Although it failed to detect 25% of the injuries, only one of these (1.4%) was significant to the acute management of the patient (Mulligan and Flye, 2006). The miss rate for the Lodox Statscan is influenced by the presentation of a whole-body image, with no directional markers to indicate suspected sites of injury. During the initial trauma evaluation, the focus is on life- and limb-threatening injuries. It is not time-effective to

Figure 4. Antero-posterior Lodox Statscan view showing near amputation of the left lower extremity. In this case Lodox Statscan provided fast, safe imaging for diagnosing injury without interrupting life-saving measures.



magnify or zoom and window/level each individual bone and joint in an effort to detect distal extremity fractures, even though the Statscan system allows this. Subsequent imaging with other modalities may be needed if the trauma and orthopaedic teams require it for further assessment of the patient's suspected sites of additional injury.

Exadaktylos et al (2008) noted that Lodox Statscan is an excellent device in mass casualty incidents (terror, accidents, disaster injuries) where conventional screening devices are very time consuming. They showed that using Lodox Statscan allows a total body exam to be undertaken without a significant increase in the time taken for resuscitation. The total body scanning time using Lodox Statscan was 3.5 minutes (3–6 minutes) compared to 25.7 minutes (8–48 min) for conventional radiography. Their results are comparable to those of Beningfield et al (2003) who showed that digital images required overall patient times of 5–6 minutes, compared with 8–48 minutes for conventional radiography. In a retrospective study on trauma patients, Deyle et al (2009) showed that Lodox Statscan imaging detected chest, thoracolumbar spine and pelvic injuries, with overall sensitivity of 62% and specificity of 99.5% when compared to computed tomography scan. Sensitivity in detecting injuries was highest in lumbar spine injuries (74%), followed by pelvic injuries (72%), chest injuries (57%) and thoracic spine injuries (43%). The authors compared their numbers with previously published sensitivities of conventional radiography and found that Lodox Statscan was more accurate.

Paediatric trauma patients

Children's tissues, in particular the thyroid gland, bone marrow, breast and lung parenchyma, are susceptible to radiation, which can modify cellular ultrastructure and predispose to malignant change in later life. This risk of cancer induction increases with the radiation dose of each examination (Ron, 2002), so limiting ionizing radiation is the cornerstone of all paediatric radiographic imaging protocols (Willis and Slovis, 2004).

Boffard et al (2006) emphasized that the speed of imaging and the low dose of radiation make Lodox Statscan a particularly useful tool for paediatric assessment in trauma. Pitcher et al (2008) performed a 3-month pilot study on 23 polytrauma patients to evaluate the use of Lodox Statscan in paediatric trauma. They showed that Lodox Statscan was able to identify 96% of fractures on the anterior-posterior plane with only one missed fracture (4%) of the calvarium that was suspected clinically and identified on a dedicated conventional radiography skull series. They also compared imaging times between Lodox Statscan and conventional radiography in 21 patients and found that Lodox Statscan was faster in 14 patients (66.6%). In one case (4.7%), imaging times were the same, while in six cases (28%), conventional radiography imaging was faster than Lodox

Statscan. Their study duplicated the findings shown by similar investigations in adult trauma patients, showing that the diagnostic quality of Lodox Statscan is essentially similar to that of conventional radiography. The same authors published their 3-year clinical paediatric experience with Lodox Statscan. They felt that Lodox Statscan was an important addition to trauma paediatric radiology, since it offers quality images and low dose radiation (Pitcher et al, 2009).

Conclusions

Lodox Statscan offers high-speed, high-quality, low radiation, full body images in a single scan, combined with three-dimensional reconstructive and zooming functionality. Its accuracy, reliability and relatively high sensitivity and specificity make it a good substitute for conventional radiography, especially when applied to critically ill poly-trauma patients, who usually need life-saving measures with no time for interruption. In this setting, additional conventional radiography could be needed for focal trauma imaging. However, the responsible physician should always keep in mind that Lodox Statscan has its own limitations. Although capable of performing and digitally analysing full body scans, the device should not be compared to high resolution imaging systems, such as computed tomography scans and magnetic resonance imaging, which can be highly accurate. Further prospective randomized studies are needed to analyse the cost effectiveness and other applications of Lodox Statscan, and to see whether it might be integrated into an official trauma resuscitation algorithm. **BJHM**

Conflict of interest: none.

- American College of Surgeons Committee on Trauma (2004) *Advanced Trauma Life Support Program for Doctors*. 7th ed. American College of Surgeons, Chicago, IL
- Amirlak B, Zakhary B, Weichman K, Ahluwalia H, Forse AR, Gaines RD (2009) Novel use of Lodox Statscan in a level one trauma center. *Ulus Travma Acil Cerrahi Derg* **15**(6): 521–8
- Beningfield S, Potgieter H, Nicol A et al (2003) Report on a new type of trauma full body digital X-ray machine. *Emerg Radiol* **10**: 23–9
- Boffard KD, Goosen J, Plani F, Degiannis E, Potgieter H (2006) The use of low dosage X-ray (Lodox/Statscan) in major trauma: comparison between low dose X-ray and conventional X-ray techniques. *J Trauma* **60**: 1175–83

- Deyle S, Wagner A, Benneker LM et al (2009) Could full-body digital X-ray (LODOX-Statscan) screening in trauma challenge conventional radiography? *J Trauma* **66**(2): 418–22
- Dries DJ (2010) Initial Evaluation of the Trauma Patient. <http://emedicine.medscape.com/article/434707-overview> (accessed 10 January 2011)
- Exadaktylos AK, Benneker LM, Jeger V et al (2008) Total-body digital X-ray in trauma. An experience report on the first operational full body scanner in Europe and its possible role in ATLS. *Injury* **39**: 525–9
- Fu CY, Wu SC, Chen RJ (2008) Lodox/Statscan provides rapid identification of bullets in multiple gunshot wounds. A case report. *Am J Emerg Med* **26**: e5–7
- Gens DR (2003) Clinical perspective on trauma images. In: Mirvis SE, Shanmuganathan K, eds. *Imaging in Trauma and Critical Care*. Saunders, Philadelphia (Pa): 1–2
- Irving BJ, Maree GJ, Hering ER, Douglas TS (2008) Radiation dose from a linear slit scanning X-ray machine with full-body imaging capabilities. *Radiat Prot Dosimetry* **130**(4): 482–9
- Mervis SE, Matsumoto J, Shanmuganathan K et al (2005) Use of total body digital radiography (Statscan) for acute trauma imaging: preliminary experience in comparison with traditional computed radiography. Abstract. Annual Scientific Meeting of the American Society of Emergency Radiology, Tucson, Arizona, USA: 21–24 September
- Moore EE, Feliciano DV, Mattox KL (2004) *Trauma*. 5th edn. McGraw-Hill Publishers, New York
- Mulligan ME, Flye CW (2006) Initial experience with Lodox Statscan imaging system for detecting injuries of the pelvis and appendicular skeleton. *Emerg Radiol* **13**(3): 129–33
- Parry RA, Glaze SA, Archer BR (1999) The AAPM/RSNA physics tutorial for residents. Typical patient radiation doses in diagnostic radiology. *Radiographics* **19**: 1289–302
- Pitcher RD, van As AB, Sanders V et al (2008) A pilot study evaluating the "STATSCAN" digital X-ray machine in paediatric polytrauma. *Emerg Radiol* **15**(1): 35–42
- Pitcher RD, Wilde JC, Douglas TS, van As AB (2009) The use of the Statscan digital X-ray unit in pediatric polytrauma. *Pediatr Radiol* **39**(5): 433–7
- Ron E (2002) Ionizing radiation and cancer risk: evidence from epidemiology. *Pediatr Radiol* **32**(4): 232–7; discussion 242–4
- Willis CE, Slovis TL (2004) The ALARA concept in radiographic dose reduction. *Radiol Technol* **76**(2): 150–2

KEY POINTS

- Lodox Statscan provides high-speed, high-quality, low radiation, full body anterior and lateral images in two single scans.
- Lodox Statscan gives critical life-saving information by providing a complete picture of a patient's bone injuries in one go, without interfering with resuscitation.
- Lodox Statscan might play a crucial role in the triaging process of mass casualty incidents (e.g. accidents, terrorist attacks).
- Lodox Statscan reduces the overall radiation exposure of patients and staff.