

# Caecal perforation following a caesarean section

## Introduction

Emergency caesarean section can lead to complications related to the mother and the baby. The risk of complications is much greater for recurrent caesarean section. If a patient becomes septic after a caesarean section, it is often treated as infection related to the uterus. If the sepsis does not settle down, imaging studies are performed, but if the patient deteriorates and imaging does not indicate a diagnosis, the patient may require an emergency exploratory laparotomy. Bowel perforation and pseudo-obstruction may occur after a caesarean section (Busch et al, 2004; Biczysko et al, 2008). This article describes a patient who suffered from caecal perforation following a caesarean section which was not recognized for more than a week. The case is presented for its rarity and diagnostic dilemma.

## Discussion

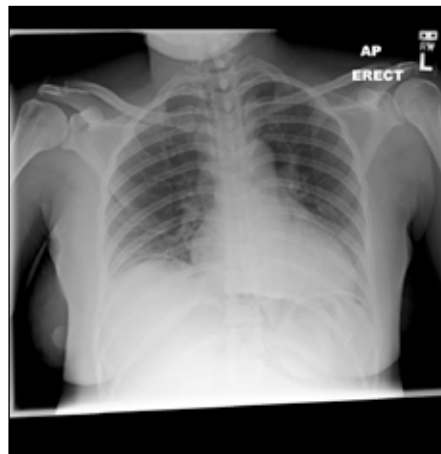Unplanned caesarean section may lead to complications. Around 15 cases of caecal perforation after caesarean section have been reported in the literature (Wesch et al, 1980; Karger and Scholtes, 1983). The exact cause of perforation is not known, but possibilities include dilation of the caecum (Sperling et al, 1990), iatrogenic injury during caesarean section and bowel diseases such as Crohn's disease (Biczysko et al, 2008).

Colonic pseudo-obstruction is well known after caesarean section. It is not clear whether it is caused by the effects of hormones. Pseudo-intestinal obstruction may occur in spite of epidural anaesthesia which is supposed to prevent it. Near term, the uterus is a pelvic organ which could potentially compress all adjacent organs. As per Laplace's law, the caecum is highly susceptible to dilation of the large bowel which may occur after caesar-

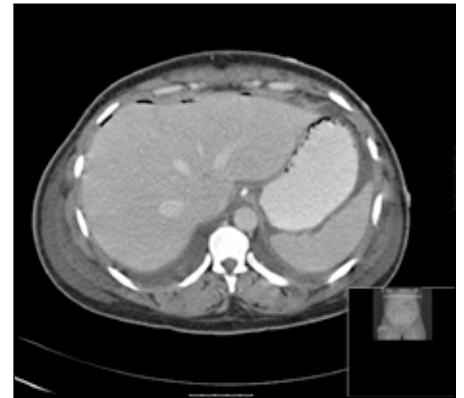ean section and when it is compressed at the same time, there is a risk of perforation. Iatrogenic injury to the caecum is rare because the incision of the uterus is usually made at the lower segment. Patients with Crohn's disease who are taking steroids may end up with perforated viscera.

In this patient, it appears that the perforation was spontaneous rather than iatrogenic. A C-reactive protein level >400 mg/litre should alert the clinician to look for other causes of sepsis. In this patient the omentum contained the perforation and prevented the patient from

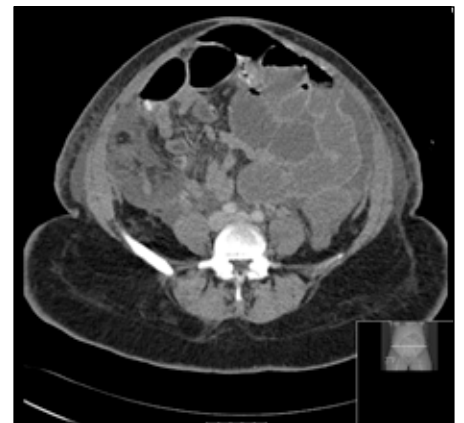
**Figure 1.** An erect chest X-ray taken on the fourth postoperative day demonstrating pneumoperitoneum.



**Figure 2.** A computed tomography scan performed on the seventh postoperative day revealed pneumoperitoneum and free fluid in the peritoneal cavity.



**Figure 3.** A transverse section of a computed tomography scan showing small bowel dilatation and intraperitoneal air between bowel loops.



## Case Report

A 36-year-old Afro-Caribbean woman was admitted to hospital in labour at 40 weeks' gestation. She developed a cord prolapse and was rushed to theatre for an emergency caesarean section. The delivered placenta was found to be complete after the section.

During the postoperative period she started vomiting. She also developed pyrexia, tachycardia and right-sided abdominal pain. A chest X-ray performed on day 4 after the operation demonstrated air under the diaphragm (Figure 1) which was thought to be insignificant because of the recent surgery. She experienced some pervaginal bleeding and her haemoglobin level dropped requiring blood transfusion. Her white cell count remained normal but her C-reactive protein level increased to 436 mg/litre (normal range <10 mg/litre). She was treated with a nasogastric tube for suspected ileus and meropenam and metronidazole for possible endometritis, but she failed to improve.

On day 7, she underwent a computed tomography scan (Figures 2 and 3) which demonstrated free intra-peritoneal air, free fluid and dilated small bowel. The patient was referred to the general surgeons and an emergency laparotomy was carried out, revealing a caecal perforation. There were no sign of any distal obstruction or large bowel dilatation. The peritoneal cavity was washed out and the perforation was closed primarily with a 3 '0' PDS (polydioxanone) suture. The abdomen was closed as a single layer mass closure. The patient's condition improved and she was discharged home a week later.

**Mr Rajaraman Durai** is Specialist Registrar and **Miss Jane Linsell** is Consultant Surgeon in the Department of Surgery, University Hospital Lewisham, London SE13 6LH

Correspondence to: Mr R Durai

developing multi-organ failure. The use of broad spectrum antibiotics may have made the perforation sterile and prolonged diagnostic delay.

## Conclusions

In the presence of persistent intra-abdominal sepsis and free intra-peritoneal air after a caesarean section, a visceral perforation should be excluded. **BJHM**

Biczysko M, Kościński T, Biczysko R (2008)  
[Unusual complication after caesarean section in a

pregnant women with undiagnosed Crohn's disease]. *Ginekol Pol* **79**(9): 635–7  
 Busch FW, Hamdorf JM, Carroll CS Sr, Magann EF, Morrison JC (2004) Acute colonic pseudo-obstruction following cesarean delivery. *J Miss State Med Assoc* **45**(11): 323–6  
 Karger N, Scholtes G (1983) [Spontaneous cecal perforation following cesarean section]. *Z Geburtshilfe Perinatol* **187**(4): 205–6  
 Sperling LS, Schantz AL, Toftager-Larsen K, Ovlisen B (1990) Non-obstructive cecal dilatation and perforation after cesarean section. *Acta Obstet Gynecol Scand* **69**(5): 437–9  
 Wesch G, Ehrlich G, Storz LW, Wiest W (1980) [Two cases of perforation of the cecum following caesarean section (author's transl)]. *Geburtshilfe Frauenheilkd* **40**(2): 116–20

## LEARNING POINTS

- Whenever there are signs of sepsis, the source should be sought and treated.
- An early computed tomography scan may be useful to assess abdominal complications related to caesarean section.
- Antibiotics alone cannot control sepsis resulting from visceral perforation.
- Pseudo-obstruction can occur during the post-caesarean period.