

Radiofrequency intravascular ultrasound and detection of the vulnerable plaque

Radiofrequency intravascular ultrasound uses radiofrequency backscatter data to determine the sub-plaque anatomy and composition of coronary atherosclerosis and hence permits plaque classification. The thin-capped fibroatheroma is associated with future major adverse cardiovascular events, emphasizing its biological importance.

Identification of the vulnerable atherosclerotic plaque is central to the prevention of future coronary events. Current practice quite appropriately involves treatment of the 'vulnerable' patient with systemic therapies such as statins, antiplatelet agents and angiotensin-converting enzyme inhibitors. Although these therapies provide substantial reduction in future major adverse cardiovascular event rates, they do not abolish them (Medical Research Council/British Heart Foundation, 2002; Cannon et al, 2004; LaRosa et al, 2005). Numerous advanced imaging techniques have been developed to attempt to identify the vulnerable plaque in vivo, giving the potential to act to prevent plaque rupture rather than react to thrombotic vessel occlusion with primary percutaneous coronary intervention. This review focuses on radiofrequency intravascular ultrasound and discusses recent data, as well as its technological limitations.

Background

The 'vulnerable plaque' is defined as an atherosclerotic plaque that is at increased risk of causing thrombotic vessel occlusion and hence myocardial infarction (Suh et al, 2011; Vancraeynest et al, 2011). Coronary artery plaque anatomy has been extensively studied and classified in post-mortem specimens (Stary et al, 1994, 1995). From these pathological studies it is known that approximately 70% of sudden cardiac deaths attributed to myocardial infarction are associated with plaque rupture, often in the absence of a significant luminal narrowing (Davies and Thomas, 1985; Davies, 1992; Burke et al, 1997). The remainder of the acute thrombotic vessel occlusions of coronary arteries are thought to be caused by endothelial erosions (20%) and calcific nodules (10%) (Ambrose, 2008). The plaque most likely to result in plaque rupture is the thin-capped fibroatheroma,

which is defined histologically as a fibroatheroma with 'lipid core separated from lumen by a cap <65 µm with macrophage infiltrate' (Burke et al, 1997).

Radiofrequency intravascular ultrasound

Innovations in intravascular ultrasound have led to a technique called radiofrequency intravascular ultrasound (Vince et al, 2000) which uses either a single rotating crystal (rotational catheter) or multiple crystals (phased array catheter) to emit and receive ultrasound waves. When the ultrasound is incident upon an interface between two materials of different acoustic densities, there is a change in the waves' amplitude (attenuation) and wavelength (refraction).

Although some of the waves continue (with a new wavelength), much of the energy is scattered (de Kroon et al, 1991). The sound energy that undergoes 'specular' scattering is reflected directly back to the intravascular ultrasound catheter and is responsible for the greyscale signal. However, much of the energy undergoes diffuse 'Rayleigh' scattering in all directions. It is this 'backscattering' that is responsible for the radiofrequency intravascular ultrasound information (Nair et al, 2002). However, turning this noisy signal into meaningful data requires complex mathematical modelling. Software developed by Volcano Corporation (Rancho Cordova, California, USA) has overcome these difficulties. A process of blind deconvolution is used to extract the raw data, which is then converted into multiple spectral parameters by auto-regression modelling (Nair et al, 2002).

The spectral parameters are fed into a classification tree and each pixel is encoded into one of four colours to denote composition. Fibrous tissue is encoded dark green, fibrofatty tissue light green, necrotic core red and calcium white (*Figure 1*) (Nasu et al, 2006). The first commercially available radiofrequency intravascular ultrasound system and that with the majority of the trial data was developed by Volcano Corporation and is called virtual histology intravascular ultrasound. Recently, Boston Scientific Corporation (Natick, MA) have developed iMAP, an imaging modality for atherosclerotic tissue characterization based on pattern recognition (Sathyanarayana et al, 2009) and a similar system has been developed called 'integrated backscatter' intravascular ultrasound where values are calculated as the average

Dr Patrick A Calvert is Clinical Lecturer in Cardiology in the Division of Cardiovascular Medicine, University of Cambridge, Addenbrooke's Hospital, Cambridge and the Department of Cardiology, Papworth Hospital NHS Foundation Trust, Cambridge CB23 3RE and **Professor Martin R Bennett** is British Heart Foundation Professor of Cardiovascular Medicine in the Division of Cardiovascular Medicine, University of Cambridge and the Department of Cardiology, Papworth Hospital NHS Foundation Trust, Cambridge

Correspondence to: Dr PA Calvert (paddy@doctors.org.uk)

power (measured in decibels) of the backscattered ultrasound signal (Kawasaki et al, 2006).

There is also a technique called elastography (also known as ‘palpography’) in which deformation (mechanical strain) data are derived from radiofrequency intravascular ultrasound. Although areas of high strain are found to be associated with lipid rich and inflamed plaques (Schaar et al, 2003, 2006), data on this technique are limited.

Validation with histology

Virtual histology intravascular ultrasound has been validated against the gold standard of histological identification of plaque composition both with atherectomy (Nasu et al, 2006) and with post-mortem specimens (Nair et al, 2002, 2007; Van Herck et al, 2009). The largest validation study compared 184 plaques from 51 explanted left anterior descending coronary arteries (Nair et al, 2007). After imaging, the specimens were sectioned for histology and virtual histology intravascular ultrasound-determined composition was compared against histology in 899 selected regions. The overall predictive accuracy was 93.5% for fibrous tissue, 94.1% for fibro-fatty tissue, 95.8% for necrotic core and 96.7% for dense calcium.

Another group demonstrated that virtual histology intravascular ultrasound can classify plaque subtypes including thin-capped fibroatheroma with high sensitivity and specificity compared to histology in rabbits (Van Herck et al, 2009), although one group reported a poor correlation between the sizes of necrotic core area as measured by virtual histology intravascular ultrasound and histology in a porcine model (Thim et al, 2010). However, there were a number of methodological issues with this study, not least the discrepancy between virtual histology intravascular ultrasound and histology sampling (an issue for all such validation studies), and these findings were questioned (Stone and Mintz, 2010). Both iMAP (Sathyanarayana et al, 2009) and integrated backscatter intravascular ultrasound (Kawasaki et al, 2006) have been validated against post-mortem specimens with high degrees of accuracy, indicating that radiofrequency intravascular ultrasound can identify both plaque composition and sub-plaque anatomy, both of which are required for plaque classification.

Virtual histology intravascular ultrasound and outcomes

The finding from histology that thin-capped fibroatheromas are the plaque type most frequently associated with rupture has focussed attention on trying to identify this type of plaque *in vivo*. The virtual histology intravascular ultrasound thin-capped fibroatheroma (Figure 2) was first defined by the Rotterdam group in 2005 in a publication that associated virtual histology intravascular ultrasound thin-capped fibroatheroma with acute coronary syndrome presentation (Rodriguez-Granillo et al, 2005). Although this finding was replicated in a

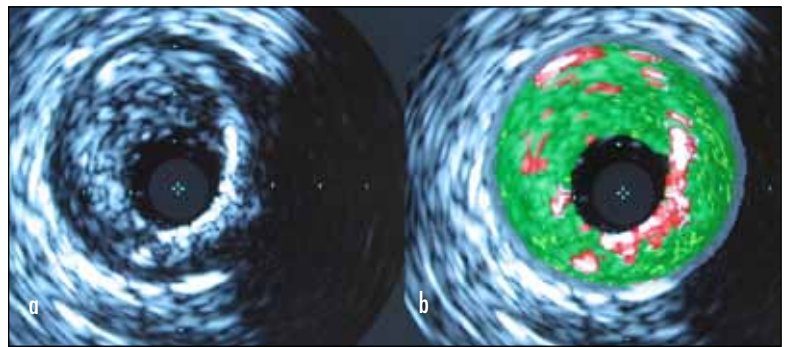
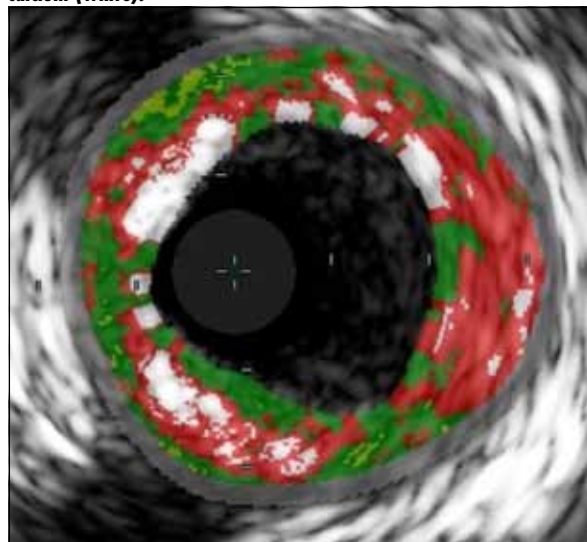


Figure 1. Corresponding (a) greyscale and (b) virtual histology intravascular ultrasound imaging of the same section of diseased coronary artery.

larger study with three-vessel virtual histology intravascular ultrasound analysis (Hong et al, 2008), other groups have found no difference in virtual histology intravascular ultrasound thin-capped fibroatheroma numbers between patients with acute coronary syndrome and those with stable angina (Surmely et al, 2006). In addition, the size of the necrotic core (the virtual histology intravascular ultrasound equivalent of the atherosclerotic lipid pool) has been associated with high-risk features in acute coronary syndrome (Missel et al, 2008a), dyslipidaemia and smoking (Missel et al, 2008b), and troponin rise after elective percutaneous coronary intervention (Hong et al, 2009).

Although these studies associate high-risk features (virtual histology intravascular ultrasound thin-capped fibroatheroma and necrotic core) with acute coronary syndrome presentation, two studies in 2011 provided evidence that radiofrequency intravascular ultrasound can prospectively identify plaques with an increased risk of future major adverse cardiovascular events. The Providing Regional Observations to Study Predictors of Events in the Coronary Tree (PROSPECT) study (Stone

Figure 2. Thin-capped fibroatheroma showing fibrous tissue (dark green), fibrofatty tissue (light green), necrotic core (red) and dense calcium (white).



et al, 2011) was a large prospective trial examining non-culprit lesions in 697 acute coronary syndrome patients. In this study virtual histology intravascular ultrasound thin-capped fibroatheroma was associated with increased future major adverse cardiovascular event rates (hazard ratio = 3.35, $P < 0.001$) compared to other plaque subtypes. Plaque burden $>70\%$ (hazard ratio = 5.01, $P < 0.001$) and minimal luminal area $<4 \text{ mm}^2$ (hazard ratio = 3.21, $P = 0.001$) were also associated with future major adverse cardiovascular events.

The authors' group replicated the findings of PROSPECT in the Virtual Histology in Vulnerable Atherosclerosis (VIVA) study, which examined a mixed cohort of 170 acute coronary syndrome and stable angina patients with a median follow up of 1.7 years (Calvert et al, 2011a). Similar to PROSPECT, they found that the virtual histology intravascular ultrasound thin-capped fibroatheroma was associated with future major adverse cardiovascular event (hazard ratio = 7.53, $P = 0.038$), and plaque burden $>70\%$ (hazard ratio = 8.13 $P = 0.011$) was also associated with major adverse cardiovascular events. Although, to date, PROSPECT has not reported biomarker data, the authors also found that virtual histology intravascular ultrasound thin-capped fibroatheroma are associated with shorter leukocyte telomere length, a DNA-based predictor of cardiovascular risk (Calvert et al, 2011b).

Although there are technical limitations of radiofrequency intravascular ultrasound (see below), these studies highlight the biological importance of the virtual histology intravascular ultrasound thin-capped fibroatheroma, whatever its exact relationship to histology-defined thin-capped fibroatheroma. However, there are some important considerations before deciding whether this technology is ready for clinical application. First, although PROSPECT and VIVA suggest that virtual histology intravascular ultrasound thin-capped fibroatheromas are associated with major adverse cardiovascular events, this does not mean that stenting these lesions will necessarily reduce future major adverse cardiovascular events. An appropriately powered study, randomizing virtual histology intravascular ultrasound thin-capped fibroatheromas to stenting or medical therapy, would be required to determine this.

The fact that virtual histology intravascular ultrasound thin-capped fibroatheromas are common (46.7% prevalence) and not especially vulnerable in the absence of other factors (4.9% major adverse cardiovascular event rate at median follow up of 3.4 years) suggests that a strategy of stenting these lesions with no other considerations is unlikely to be realistic (Stone et al, 2011). Additional plaque features of plaque burden $>70\%$ and minimum luminal area $<4 \text{ mm}^2$ considerably increased the likelihood of major adverse cardiovascular events in PROSPECT and any stenting strategy might incorporate these additional features (Stone et al, 2011). Nonetheless a pilot study of treating virtual histology intravascular ultrasound

thin-capped fibroatheroma with a self-expanding stent to shield the lesion has been reported although no substantial results are available as yet (Ramcharitar et al, 2009).

Given the tight association between post-mortem thin-capped fibroatheroma and events, the relatively low event rate per individual virtual histology intravascular ultrasound thin-capped fibroatheroma might seem surprising. However, although post-mortem studies indicate that 70% of thrombotic vessel occlusion in sudden cardiac death is related to plaque rupture, before the PROSPECT and VIVA studies, there was no indication of the natural history of either the virtual histology intravascular ultrasound thin-capped fibroatheroma or indeed of the histology-defined thin-capped fibroatheroma. Furthermore it is likely that sub-clinical plaque rupture is a relatively frequent event. Post-mortem (Mann and Davies, 1999) and angiographic data (Ueda et al, 2004) indicate that sub-clinical rupture is common; indeed, advanced plaques show multiple healed ruptures and sub-clinical rupture and repair is viewed as a common mechanism of plaque growth (Mann and Davies, 1999).

Technological limitations

Radiofrequency intravascular ultrasound does have some important technological limitations. First, the axial resolution of virtual histology intravascular ultrasound is $150 \mu\text{m}$ (Konig and Klaus, 2007), while the histological definition of a thin-capped fibroatheroma demands a cap of $<65 \mu\text{m}$ (Burke et al, 1997). Thus, virtual histology intravascular ultrasound will tend to over-estimate the number of thin-capped fibroatheromas. While this problem has been partly addressed by changing the definition of a thin-capped fibroatheroma (see below), such limitation in resolution could also be overcome by combining radiofrequency intravascular ultrasound with an imaging modality with good near field resolution, such as optical coherence tomography. Optical coherence tomography is now a routine imaging device, as the frequency-domain technology allows pull-back rates of 20 mm/s , obviating the need for proximal vessel occlusion which was necessary with the previous time-domain system.

While optical coherence tomography is an attractive modality for thin-capped fibroatheroma identification, it also has drawbacks, including poor depth penetration. In addition, while optical coherence tomography has been validated against plaque composition ex vivo (Yabushita et al, 2002; Kawasaki et al, 2006; Kume et al, 2009), prospective prognostic natural history studies demonstrating that optical coherence tomography-defined thin-capped fibroatheroma (*Figure 3*) are associated with future major adverse cardiovascular events are lacking.

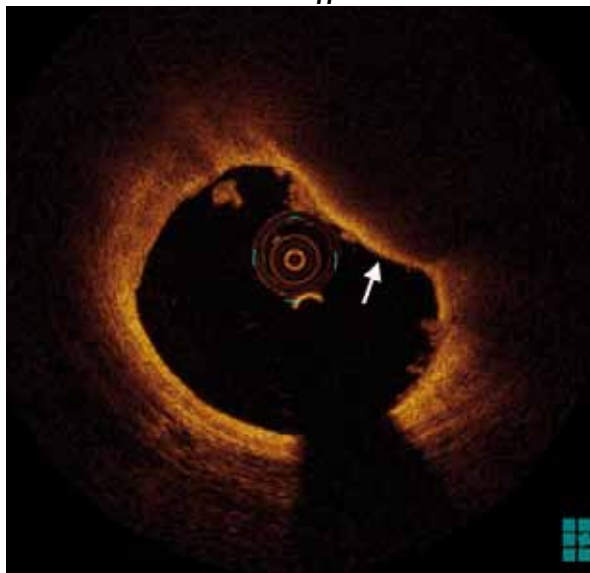
Second, virtual histology intravascular ultrasound-identified thin-capped fibroatheromas have been defined differently in different studies. The most commonly accepted definition comes from the Rotterdam group (Rodriguez-Granillo et al, 2005) who defined a virtual histology intravascular ultrasound thin-capped fibroatheroma as a

'focal, necrotic core-rich (>10% of the cross-sectional area) plaque being in contact with the lumen with a percent atheroma volume (PAV) >40%.' However, this definition is open to interpretation and subsequent refinements have been proposed by expert groups (Konig et al, 2008; Garcia-Garcia et al, 2009). The PROSPECT trial defined virtual histology intravascular ultrasound thin-capped fibroatheroma as follows: 'Fibroatheromas were defined by the presence of >10% confluent necrotic core (NC). If more than 30 degrees of the NC abutted the lumen in 3 or more consecutive frames, the fibroatheroma was classified as a thin-cap fibroatheroma' (Stone et al, 2011).

Given the results of PROSPECT, the stricter definition of virtual histology intravascular ultrasound thin-capped fibroatheroma used in this trial is likely to be used in future studies, although similar results were found in VIVA which used the original 'Rotterdam' definition. The effects of different definitions of virtual histology intravascular ultrasound thin-capped fibroatheroma have been examined in subsequent studies, which showed that adopting the stricter PROSPECT definition rather than the Rotterdam definition resulted in 41% of virtual histology intravascular ultrasound thin-capped fibroatheromas being re-classified as non-virtual histology intravascular ultrasound thin-capped fibroatheroma (Obaid et al, 2012).

Third, radiofrequency intravascular ultrasound-based plaque classification is a relatively labour-intensive process that requires manually checking the luminal and adventitial borders in each axial frame, although the latest automated software is a considerable improvement on older iterations. This means that the large prospective trials have used core labs to ensure reproducibility

Figure 3. Optical coherence tomography image of a thin-capped fibroatheroma (arrow). The optical coherence tomography thin-capped fibroatheroma can be defined as a lipid pool (rapid signal drop-out behind a diffuse intima-to-lipid border) with a cap thickness of less than 65 µm. Note that there is thrombus adherent to the luminal surface of the thin-capped fibroatheroma.



between observers and studies. Indeed, while inter-observer variability for radiofrequency intravascular ultrasound-determined plaque composition is excellent, variability for radiofrequency intravascular ultrasound plaque classification is less robust (Obaid et al, 2012).

Finally, it must be remembered that radiofrequency intravascular ultrasound only assesses plaque anatomy and composition. As such, it identifies plaques whose constituents have a similar content and distribution to those found responsible for major adverse cardiovascular events based on post-mortem studies (Nair et al, 2002, 2007; Van Herck et al, 2009) or associated with major adverse cardiovascular events in prospective trials (Calvert et al, 2011a; Stone et al, 2011). Unlike pressure wires, radiofrequency intravascular ultrasound does not tell us whether stenting an individual lesion will improve flow dynamics across it. Although this is a limitation of the current technology, coronary plaques that are haemodynamically flow-limiting are not necessarily vulnerable to causing thrombotic vessel occlusion as evidenced by post-mortem studies (Kolodgie et al, 2004).

Conclusions

Radiofrequency intravascular ultrasound is an important step in the identification of the vulnerable plaque in vivo. Radiofrequency intravascular ultrasound (in particular virtual histology intravascular ultrasound) is also the only invasive imaging modality with prospective prognostic data and the virtual histology intravascular ultrasound thin-capped fibroatheroma undoubtedly represents a biologically important entity. Thus radiofrequency intravascular ultrasound, even with its limitations, remains the best validated and studied technique at identifying the vulnerable plaque in vivo. **BJHM**

Dr PA Calvert and Professor MR Bennett are supported by the British Heart Foundation Grant CH/2000003 and the NIHR Cambridge Biomedical Research Centre.

Figure 3 is reproduced by kind permission of St Judes Medical.

Conflict of interest: none.

KEY POINTS

- The 'vulnerable plaque' is at increased risk of causing thrombotic vessel occlusion and hence myocardial infarction.
- Post-mortem studies have shown that 70% of deaths resulting from thrombotic coronary artery occlusion are caused by rupture of a thin-capped fibroatheroma – the vulnerable plaque.
- Radiofrequency intravascular ultrasound is an adaptation of conventional intravascular ultrasound that permits identification of atherosclerotic plaque constituents and hence identification of the vulnerable plaque in vivo.
- Virtual histology intravascular ultrasound is the best-validated form of radiofrequency intravascular ultrasound technology although other iterations exist.
- Prospective studies have shown that the virtual histology intravascular ultrasound thin-capped fibroatheroma is associated with future major adverse cardiovascular events.

- Ambrose JA (2008) In search of the "vulnerable plaque": can it be localized and will focal regional therapy ever be an option for cardiac prevention? *J Am Coll Cardiol* **51**(16): 1539–42
- Burke AP, Farb A, Malcom GT, Liang YH, Smialek J, Virmani R (1997) Coronary risk factors and plaque morphology in men with coronary disease who died suddenly. *N Engl J Med* **336**(18): 1276–82
- Calvert PA, Obaid DR, O'Sullivan M et al (2011a) Association between IVUS findings and adverse outcomes in patients with coronary artery disease: the VIVA (VH-IVUS in Vulnerable Atherosclerosis) Study. *JACC Cardiovasc Imaging* **4**(8): 894–901
- Calvert PA, Liew TV, Gorenne I et al (2011b) Leukocyte telomere length is associated with high-risk plaques on virtual histology intravascular ultrasound and increased proinflammatory activity. *Arterioscler Thromb Vasc Biol* **31**(9): 2157–64
- Cannon CP, Braunwald E, McCabe CH et al (2004) Intensive versus moderate lipid lowering with statins after acute coronary syndromes. *N Engl J Med* **350**(15): 1495–504
- Davies MJ (1992) Anatomic features in victims of sudden coronary death. Coronary artery pathology. *Circulation* **85**(1 Suppl): I19–24
- Davies MJ, Thomas AC (1985) Plaque fissuring—the cause of acute myocardial infarction, sudden ischaemic death, and crescendo angina. *Br Heart J* **53**(4): 363–73
- de Kroon MG, van der Wal LF, Gussenhoven WJ, Rijsterborgh H, Bom N (1991) Backscatter directivity and integrated backscatter power of arterial tissue. *Int J Card Imaging* **6**(3–4): 265–75
- Garcia-Garcia HM, Mintz GS, Lerman A et al (2009) Tissue characterisation using intravascular radiofrequency data analysis: recommendation for acquisition, analysis, interpretation and reporting. *EuroIntervention* **5**(2): 177–89
- Hong MK, Mintz GS, Lee CW et al (2008) A three-vessel virtual histology intravascular ultrasound analysis of frequency and distribution of thin-cap fibroatheromas in patients with acute coronary syndrome or stable angina pectoris. *Am J Cardiol* **101**(5): 568–72
- Hong YJ, Mintz GS, Kim SW et al (2009) Impact of plaque composition on cardiac troponin elevation after percutaneous coronary intervention: an ultrasound analysis. *JACC Cardiovasc Imaging* **2**(4): 458–68
- Kawasaki M, Bouma BE, Bressner J et al (2006) Diagnostic accuracy of optical coherence tomography and integrated backscatter intravascular ultrasound images for tissue characterization of human coronary plaques. *J Am Coll Cardiol* **48**(1): 81–8
- Kolodgie FD, Virmani R, Burke AP et al (2004) Pathologic assessment of the vulnerable human coronary plaque. *Heart* **90**(12): 1385–91
- Konig A, Klaus V (2007) Virtual histology. *Heart* **93**(8): 977–82
- Konig A, Margolis MP, Virmani R, Holmes D, Klaus V (2008) Technology insight: in vivo coronary plaque classification by intravascular ultrasonography radiofrequency analysis. *Nat Clin Pract Cardiovasc Med* **5**(4): 219–29
- Kume T, Okura H, Yamada R et al (2009) Frequency and spatial distribution of thin-cap fibroatheroma assessed by 3-vessel intravascular ultrasound and optical coherence tomography: an ex vivo validation and an initial in vivo feasibility study. *Circ J* **73**(6): 1086–91
- LaRosa JC, Grundy SM, Waters DD et al (2005) Intensive lipid lowering with atorvastatin in patients with stable coronary disease. *N Engl J Med* **352**(14): 1425–35
- Mann J, Davies MJ (1999) Mechanisms of progression in native coronary artery disease: role of healed plaque disruption. *Heart* **82**(3): 265–8
- Missel E, Mintz GS, Carlier SG et al (2008a) Necrotic core and its ratio to dense calcium are predictors of high-risk non-ST-elevation acute coronary syndrome. *Am J Cardiol* **101**(5): 573–8
- Missel E, Mintz GS, Carlier SG et al (2008b) In vivo virtual histology intravascular ultrasound correlates of risk factors for sudden coronary death in men: results from the prospective, multi-centre virtual histology intravascular ultrasound registry. *Eur Heart J* **29**(17): 2141–7
- Medical Research Council/British Heart Foundation (2002) MRC/BHF Heart Protection Study of cholesterol lowering with simvastatin in 20,536 high-risk individuals: a randomised placebo-controlled trial. *Lancet* **360**(9326): 7–22
- Nair A, Kuban BD, Tuzcu EM, Schoenhagen P, Nissen SE, Vince DG (2002) Coronary plaque classification with intravascular ultrasound radiofrequency data analysis. *Circulation* **106**(17): 2200–6
- Nair A, Margolis M, Kuban B, Vince D (2007) Automated coronary plaque characterisation with intravascular ultrasound backscatter: ex vivo validation. *EuroIntervention* **3**: 113–20
- Nasu K, Tsuchikane E, Katoh O et al (2006) Accuracy of in vivo coronary plaque morphology assessment: a validation study of in vivo virtual histology compared with in vitro histopathology. *J Am Coll Cardiol* **47**(12): 2405–12
- Obaid DR, Calvert PA, McNab D, West NE, Bennett MR (2012) Identification of coronary plaque sub-types using virtual histology intravascular ultrasound is affected by inter-observer variability and differences in plaque definitions. *Circ Cardiovasc Imaging* **5**(1): 86–93
- Ramcharitar S, Gonzalo N, van Geuns RJ et al (2009) First case of stenting of a vulnerable plaque in the SECRITT I trial—the dawn of a new era? *Nat Rev Cardiol* **6**(5): 374–8
- Rodriguez-Granillo GA, Garcia-Garcia HM, McFadden EP et al (2005) In vivo intravascular ultrasound-derived thin-cap fibroatheroma detection using ultrasound radiofrequency data analysis. *J Am Coll Cardiol* **46**(11): 2038–42
- Sathyanarayana S, Carlier S, Li W, Thomas L (2009) Characterisation of atherosclerotic plaque by spectral similarity of radiofrequency intravascular ultrasound signals. *EuroIntervention* **5**(1): 133–9
- Schaar JA, De Korte CL, Mastik F et al (2003) Characterizing vulnerable plaque features with intravascular elastography. *Circulation* **108**(21): 2636–41
- Schaar JA, van der Steen AF, Mastik F, Baldewijs RA, Serruys PW (2006) Intravascular palpography for vulnerable plaque assessment. *J Am Coll Cardiol* **47**(8 Suppl): C86–91
- Sary HC, Chandler AB, Glagov S et al (1994) A definition of initial, fatty streak, and intermediate lesions of atherosclerosis. A report from the Committee on Vascular Lesions of the Council on Arteriosclerosis, American Heart Association. *Arterioscler Thromb* **14**(5): 840–56
- Sary HC, Chandler AB, Dinsmore RE et al (1995) A definition of advanced types of atherosclerotic lesions and a histological classification of atherosclerosis. A report from the Committee on Vascular Lesions of the Council on Arteriosclerosis, American Heart Association. *Arterioscler Thromb Vasc Biol* **15**(9): 1512–31
- Stone GW, Mintz GS (2010) Letter by Stone and Mintz regarding article, "unreliable assessment of necrotic core by virtual histology intravascular ultrasound in porcine coronary artery disease". *Circ Cardiovasc Imaging* **3**(5): e4; author reply e5
- Stone GW, Maehara A, Lansky AJ et al (2011) A prospective natural-history study of coronary atherosclerosis. *N Engl J Med* **364**(3): 226–35
- Suh WM, Seto AH, Margey RJ, Cruz-Gonzalez I, Jang IK (2011) Intravascular detection of the vulnerable plaque. *Circ Cardiovasc Imaging* **4**(2): 169–78
- Surmely JF, Nasu K, Fujita H et al (2006) Coronary plaque composition of culprit/target lesions according to the clinical presentation: a virtual histology intravascular ultrasound analysis. *Eur Heart J* **27**(24): 2939–44
- Thim T, Hagensen MK, Wallace-Bradley D et al (2010) Unreliable Assessment of Necrotic Core by VHTM IVUS in Porcine Coronary Artery Disease. *Circ Cardiovasc Imaging* **3**(4): 384–91
- Ueda Y, Ohtani T, Shimizu M, Hirayama A, Kodama K (2004) Assessment of plaque vulnerability by angioscopic classification of plaque color. *Am Heart J* **148**(2): 333–5
- Vancraeynest D, Pasquet A, Roelants V, Gerber BL, Vanoverschelde JL (2011) Imaging the vulnerable plaque. *J Am Coll Cardiol* **57**(20): 1961–79
- Van Herck J, De Meyer G, Ennekens G, Van Herck P, Herman A, Vrints C (2009) Validation of in vivo plaque characterisation by virtual histology in a rabbit model of atherosclerosis. *EuroIntervention* **5**(1): 149–56
- Vince DG, DK, Cothren RM, Cornhill JF (2000) Comparison of texture analysis methods for the characterization of coronary plaques in intravascular ultrasound images. *Comput Med Imaging Graph* **24**(4): 221–9
- Yabushita H, Bouma BE, Houser SL et al (2002) Characterization of human atherosclerosis by optical coherence tomography. *Circulation* **106**(13): 1640–5