

**CORE
TRAINING
FOR DOCTORS**

WHAT YOU NEED TO KNOW ABOUT

Testicular torsion C34

Anthony M Cox, Hiten Patel, James Gelister

TIPS FROM THE SHOP FLOOR

Acute limb ischaemia C38

Sathiji Nageshwaran, Saiji Nageshwaran, Perbinder Grewal

**WHAT THEY DON'T TEACH YOU
AT MEDICAL SCHOOL**

**Tackling the single best
answer question in
the final FRCA examination C44**

Chinmay Patvardhan, Nina Plant, Steve Benington

**CLINICAL SKILLS FOR
POSTGRADUATE EXAMINATIONS**

Acute appendicitis C46

Harold Ellis

COMING NEXT MONTH

WHAT YOU NEED TO KNOW ABOUT

Dengue fever

**CLINICAL SKILLS FOR
POSTGRADUATE EXAMINATIONS**

Erythema nodosum

TIPS FROM THE SHOP FLOOR

Blood cultures

Edited by **Dr Daniel JB Marks**, Academic Clinical Fellow in Translational Medicine, and **Dr Philip J Smith**, Academic Clinical Fellow and Specialist Registrar in Gastroenterology, University College London

Testicular torsion

Introduction

Testicular torsion is a urological emergency, whereby twisting of the spermatic cord compromises blood flow to the testis. The diagnosis is suspected from a history of sudden onset, severe, incapacitating testicular pain. All patients presenting in this manner must be explored surgically. Delay in exploration beyond 6 hours results in irreversible ischaemia necessitating orchidectomy.

The incidence has a bimodal distribution with the main peak around puberty and another smaller peak in the first year of life. In men under the age of 25 years, the annual incidence of torsion is around 1 in 4000 (Chan et al, 2009).

Mr Anthony M Cox is Core Surgical Trainee in the Department of Ear Nose and Throat Surgery, St Mary's Hospital, London W2 1NY, **Mr Hiten Patel** is Consultant in Urology and Clinical Senior Lecturer, Bart's and The London, Queen Mary University of London, London and **Mr James Gelister** is Consultant in Urology, Barnet and Chase Farm Hospitals NHS Trust, Barnet and Chase Farm Hospitals NHS Trust, London

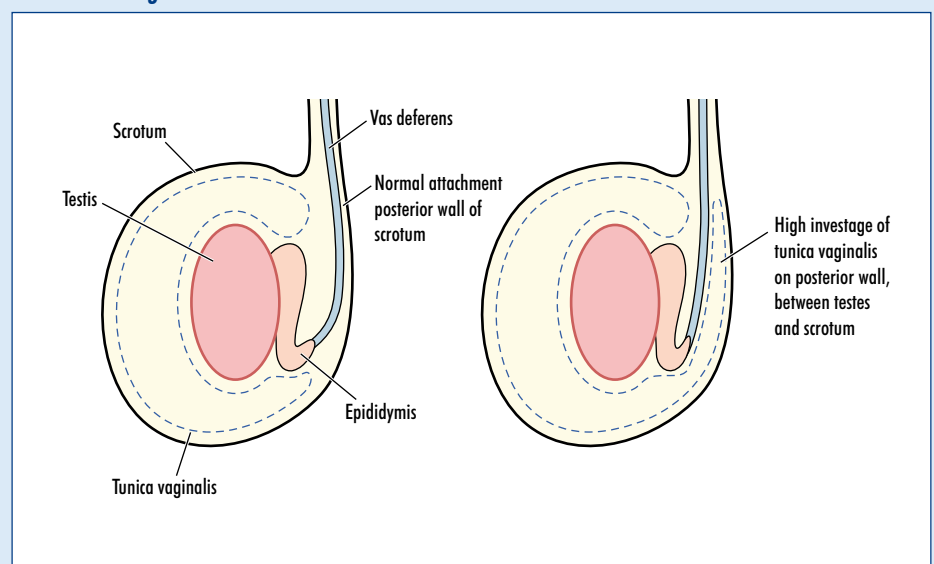
Correspondence to: Mr AM Cox
(dranthonycox@hotmail.co.uk)

Clinical anatomy

Anatomical variants predisposing to testicular torsion can be subdivided into intravaginal and extravaginal subtypes, depending on whether torsion occurs within or external to the tunica vaginalis (the extension of the peritoneum into the scrotum that covers the anterior two-thirds of the testicle).

The intravaginal congenital anomaly that renders the testicle prone to torsion remains the more common of the two variants, and is known as the 'bell clapper deformity' (Figure 1). This occurs when the tunica vaginalis invests abnormally high on the posterior wall of the scrotum, obliterating the normal site of posterior testicular attachment. This means that its only pedicle is the spermatic cord, which can readily tort. It is described as bell clapper because the orientation of the testicular long axis of the testicle is now transverse as opposed to the normal cephalocaudal. Torsion results as the testicle rotates between 90° and 180°, compromising its vascular supply. Complete torsion usually results when the testicle twists 360° or more, and incomplete or partial torsion occurs when twisting is less than this. The bell clapper deformity occurs in up to 12% of males, and is bilateral in the majority of cases, with a

Figure 1. The abnormal horizontal testicular lie in so-called 'bell clapper' deformity. This is caused by a loss of normal fixation of the testicle on the posterior scrotal wall because of intervening, high invagination of the tunica vaginalis.



significant risk of contralateral torsion (Lewis et al, 1995; Kapoor, 2008; Kyriazis et al, 2008).

Extravaginal torsion occurs in neonates. The tunica vaginalis becomes abnormally adherent to the testis. As with intravaginal torsion, since there is no attachment to the posterior wall of the scrotum, the testicle is free to move but this time it is free within the scrotum rather than the tunica. The presentation in the perinatal period is with a small hard testis and acute scrotal pain (Brandt et al, 1992).

Torsion results in occlusion of the testicular artery, with venous stasis in the pampiniform plexus and reduced organ perfusion pressure. The end result is ischaemia and infarction.

History

The history is critical for diagnosis, since it is very typical – unnecessary delay with investigations to augment a poor history could be disastrous for patient, clinician and trust. Common features include an acute, exquisitely painful unilateral testicle, often waking the patient from sleep (in up to 50% of cases) (Barada et al, 1989; Sun et al, 2006). Fever, scrotal swelling, abdominal pain, nausea and vomiting may be accompanying features. The patient or his parents may offer a history of previously investigated unilateral testicular pain of lesser severity, perhaps alluding to torsion–detorsion episodes in the past.

Examination

Presence of the cremasteric reflex or a non-tender testicle usually excludes testicular torsion. This refers to the reflex contraction of the hemiscrotal cremasteric muscle in response to light stroking of the inner thigh, resulting in elevation of the testicle. Scrotal swelling may be present. It may be difficult to establish an abnormal testicular lie as a result of pain, swelling or retraction of the testis proximally (Lewis et al, 1995). The testis is tender and high riding. If caught early, detorsion can be attempted manually with external rotation of the testis until pain subsides (Cornel and Karthaus, 1999), but since exploration will follow should never be regarded as a substitute and may be too painful even to attempt (Barada et al, 1989).

Differential diagnosis Epididymo-orchitis

Usually presents with malaise and fever, and subacute onset of tenderness. Take a sexual history, and perform a urethral swab. Prehn's sign (elevation of the testis to relieve weight ameliorates the aching pain) may be present (Kadish and Bolte, 1998). Orchitis may be a complication of mumps.

Inguinal hernia

If incarcerated, an acute indirect inguinal hernia with bowel in the hemi-scrotum may become indurated and mimic testicular torsion. Attempt to get above or reduce the lump, auscultate for bowel sounds, and examine to discern whether two separate testes are discernible.

Torsion of the hydatid of Morgagni

This is torsion of a remnant of the Mullerian duct. Also known as paramesonephric ducts, they are paired ducts of mesoderm origin that run lateral to the urogenital ridge and terminate in the primitive urogenital sinus. In the female, they will develop to form the Fallopian tubes, uterus, cervix and the upper third of the vagina; in the male, they regress. There will be exquisite pain in a unilateral testis, but confined on palpation to the superior pole (the site of the remnant). There may be a 'blue dot', a sign of underlying ischaemia or necrosis. Surgical exploration and excision of the remnant is usually required.

Scrotal trauma

This will usually be easily differentiated from torsion by the history.

The role of ultrasound

Ultrasound colour Doppler is the imaging modality of choice, with sensitivity of 86–100%, specificity of 98.8–100%, positive predictive value of 73%, negative predictive value of 100%, and false positive rate of 1% (Weber et al, 2000). If ultrasound is readily available and can be performed quickly, then in atypical presentations of testicular torsion it can be extremely valuable.

Ultrasound is always operator dependent and pre-pubertal low testicular volumes may impede image acquisition. On a practical level, when the junior on-call surgeon

considers testicular torsion to be extremely unlikely, then ultrasound is indicated. At this point, you are essentially asking the ultrasonographer to 'prove you wrong'.

Treatment

Surgical exploration of the scrotum through a midline incision is the gold standard. The two most important salvage determinants are duration of torsion and severity (number of twists). Detorsion at a mean time of 13 hours preserves fertility. If present, a dusky, blue or necrotic (depending on the delay to surgery) testicle will be found, along with the causative twisted pedicle of spermatic cord. Most testicles tort from lateral to medial, twisting inwards towards the midline, but the direction required to untort the twisted spermatic cord should be obvious at exploration. Untwist until perfusion is seen.

If the testicle remains dusky, then wrapping in warm saline-soaked gauze and asking the anaesthetist to administer 100% oxygen is appropriate to try to salvage the testis and avoid orchidectomy. If vascular flow returns, three-point orchidopexy is performed at the upper, middle and lower poles with fine non-absorbable sutures. The fixation is three-point as it is thought that two-point fixation still allows the testis to rotate around the axis of the sutures. Recurrence of torsion after orchidopexy is rare (4.5%) (Tryfonas et al, 1994).

Reduction in ischaemia-perfusion injury has been effectively demonstrated using various agents (darbepoetin alfa, trimetizidine) in experimental models, as has the effect of external cooling, although they are not widely used in clinical practice (Haj et al, 2007). There is no literature to suggest superior fixation of one material or indeed type, but some urologists would not recommend breaching the tunica albuginea because of the increased risk of malignancy and infertility (Frank and O'Brien, 2002), and would perform a dartos pouch fixation procedure instead. Not performing contralateral orchidopexy at the time of first exploration is medicolegally indefensible.

Even if the patient presents with significant delay (>24 hours), semi-elective exploration is still recommended. Controversy over orchidectomy *vs* fixation of the affected testicle, in view of future fertility, still exists (Barada et al, 1989; Kapoor, 2008).

Prognosis

Sub-fertility can be found in up to 40% of patients post-torsion (Visser and Heyns, 2003), thought to be secondary to breaching of the blood–testis barrier and a subsequent autoimmune response. Some literature suggests that pre-pubertal unilateral testicular torsion induces decreased spermatogenesis post-pubertally (Sun et al, 2006). One study found anti-sperm antibodies in the serum of post-torsion patients, which correlated with infertility (Tryfonas et al, 1994), while others have failed to replicate this (Arap et al, 2007). Other scrotal exploration operative risks affecting the prognosis include palpable non-absorbable suture when orchidopexy is performed, scrotal haematoma possibly requiring evacuation (>1%), risk of infection of wound or more rarely infective orchitis.

Conclusions

Testicular torsion is a urological emergency that commonly presents to emergency departments and general surgical teams. A high index of suspicion from the clinical history is paramount to minimizing delay to surgical exploration, crucial for avoiding orchidectomy and its subsequent complications. **BJHM**

Conflict of interest: none.

- Arap MA, Vicentini FC, Cocuzza M et al (2007) Late hormonal levels, semen parameters, and presence of antisperm antibodies in patients treated for testicular torsion. *J Androl* **28**(4): 528–32
- Barada JH, Weingarten JL, Cromie WJ (1989) Testicular salvage and age-related delay in the presentation of testicular torsion. *J Urol* **142**(3): 746–8
- Brandt MT, Sheldon CA, Wacksman J, Matthews P

- (1992) Prenatal testicular torsion: principles of management. *J Urol* **147**(3): 670–2
- Chan JL, Knoll JM, Depowski PL, Williams RA, Schober JM (2009) Mesorchial testicular torsion: case report and a review of the literature. *Urology* **73**(1): 83–6
- Cornel EB, Karthaus HF (1999) Manual derotation of the twisted spermatic cord. *BJU Int* **83**(6): 672–4
- Frank JD, O'Brien M (2002) Fixation of the testis. *BJU Int* **8**(94): 331–3
- Haj M, Shasha SM, Loberant N, Farhadian H (2007) Effect of external scrotal cooling on the viability of the testis with torsion in rats. *Eur Surg Res* **39**(3): 160–9
- Kadish HA, Bolte RG (1998) A retrospective review of pediatric patients with epididymitis, testicular torsion, and torsion of testicular appendages. *Pediatrics* **102**: 73–6
- Kapoor S (2008) Testicular torsion: a race against time. *Int J Clin Pract* **62**(5): 821–7
- Kyriazis ID, Dimopoulos J, Sakellaris G, Waldschmidt J, Charissis G (2008) Extravaginal testicular torsion: a clinical entity with unspecified surgical anatomy. *Int Braz J Urol* **34**(5): 617–23; discussion 623–6
- Lewis AG, Bukowski TP, Jarvis PD et al (1995) Evaluation of acute scrotum in the emergency department. *J Pediatr Surg* **30**(2): 277–81; discussion 281–2
- Sun J, Liu GH, Zhao HT, Shi CR (2006) Long-term influence of prepubertal testicular torsion on spermatogenesis. *Urol Int* **77**(3): 275–8
- Tryfonas G, Violaki A, Tsikopoulos G et al (1994) Late postoperative results in males treated for testicular torsion during childhood. *J Pediatr Surg* **29**(4): 553–6
- Visser AJ, Heyns CF (2003) Testicular function after torsion of the spermatic cord. *BJU Int* **92**(3): 200–3
- Weber DM, Rosslein R, Fliegel C (2000) Color Doppler sonography in the diagnosis of acute scrotum in boys. *Eur J Pediatr Surg* **10**(4): 235–41

KEY POINTS

- Torsion is an acute surgical emergency requiring scrotal exploration and de-torsion within 6 hours to prevent irreversible ischaemia.
- The most important determinants are duration (<6 hours viable, >24 hours non-viable) and degree (180°, 360°) of torsion.
- Extravaginal torsion occurs in the perinatal period. Intravaginal torsion occurs in puberty and is more common.
- Ultrasound should not delay definite exploration, but is useful in unlikely cases as a rule out measure.
- Once torsion is relieved, three-point suture orchidopexy bilaterally is performed.