

Traumatic injuries to the biliary tree

Traumatic biliary injuries are uncommon and frequently associated with damage to other viscera. Some injuries are immediately recognized, but others are occult and present with a postoperative bile leak or more insidiously. Biliary trauma requires a multidisciplinary approach: radiological, endoscopic and operative interventions all play a role.

Abdominal trauma that results in injury to the biliary tree is both uncommon and usually accompanied by other abdominal injuries. Since isolated biliary trauma is rare, biliary injuries are frequently overlooked in an unstable patient. Even if they are identified during a trauma laparotomy, definitive operative repair is difficult; it depends on concurrent injuries, the severity of biliary damage and the experience of the surgeon. Damage control surgery before referral for definitive operative management is usually prudent in these patients.

Traumatic biliary injuries that present sometime after the initial causative event should be assessed by both radiological and endoscopic means to delineate the exact nature and location of the injury before definitive intervention. To optimize management, these injuries should be discussed at a specialist hepatopancreatobiliary multidisciplinary team. Patients with biliary strictures developing weeks to years after missed trauma have a lifelong risk of cholestasis and potentially liver failure. These patients may require a combination of radiological and endoscopic interventions before definitive surgical repair.

A Medline literature review was performed for pertinent articles over the last four decades and assimilated to provide a guide to current management strategies for biliary trauma. This review highlights how traumatic biliary injuries can be managed in the immediate, intermediate and delayed stages of presentation. Although they are relatively rare, some knowledge of management principles may be useful. Bile duct injuries are best managed by a multidisciplinary team at a specialist centre, yet initial lifesaving treatments may prevent this.

Incidence

Injuries to the biliary tree are relatively rare, arising in only 1–2% of all cases of abdominal trauma (Sawaya et al, 2001). The commonest site of injury is the gall bladder; only 15% of cases involve the bile ducts, in part, because of their deeper location within or beneath the liver (Burgess and Fulton, 1992). Intrahepatic duct damage is the least common injury, being virtually confined to patients with severe liver lacerations (Gupta et al, 2004). Gall bladder injury is frequently associated with additional injuries to the liver (91% of cases), spleen and duodenum (54% each) (Chen et al, 2001).

Mr JML Williamson is General Surgical Speciality Training Registrar in the Department of Hepato-Pancreato-Biliary Surgery, Bristol Royal Infirmary, Bristol BS2 8HW (jmlw@doctors.org.uk)

Causes

Biliary injury may follow torsion, shearing or compression forces to the right upper quadrant (Erb et al, 1994). To a certain extent, the gall bladder is protected by the liver; however, distension (i.e. in a preprandial state) increases biliary pressure, making the gall bladder more vulnerable to compression injury. Gall bladder trauma may be associated with cystic artery transection, leading to major blood loss. Traumatic biliary fistulas can be simple biliary leaks into the liver, peritoneum or pleura, or can result in various biliary-vascular fistulas.

Injuries to the extrahepatic ductal tree tend to occur at sites of anatomical fixation, such as the intrapancreatic portion of the common bile duct. They reflect direct impact or acute deceleration, potentially with compression against the spine (Feliciano, 1994). The retroduodenal region of the bile duct above the upper border of the pancreas is the commonest site of transection following blunt trauma. Generally injuries to the intrahepatic bile ducts are confined to patients with deep liver lacerations (Gupta et al, 2004).

Presentation

Biliary injuries can escape detection until bile accumulates in the abdomen or appears in an abdominal drain or until the development of a biliary stricture. Thus traumatic injuries can be grouped into three time periods following the initial insult:

Immediate (less than 72 hours)

As biliary injury is frequently associated with concurrent organ damage, a diagnosis may only be reached during a trauma laparotomy (with or without the use of computed tomography). The presence of free bile denotes an injury to either biliary apparatus, liver or duodenum, but this may be overlooked if the patient is bleeding heavily. The presence of bile in intra-abdominal drains may then be the first indication of biliary injury.

Intermediate (72 hours–6 weeks)

Isolated biliary lacerations, with extravasation of bile, may present some hours to days following initial injury. Sterile bile within the peritoneal cavity undergoes continuous peritoneal reabsorption and may lead to surprisingly few symptoms at first. Sometimes progressive abdominal distension (either caused by a large biloma (subhepatic bile collection) or biliary ascites) is the first clinical symptom, potentially after weeks or even months.

Patients eventually develop vague abdominal pain, nausea, vomiting and occasionally jaundice (Feliciano, 1994). Up to 50% of patients with bile in the peritoneum at operation have no localizing symptoms (Jeffrey et al, 1986). Infected bile is very different, quickly leading to peritonitis and associated toxicity.

Delayed (more than 6 weeks)

These patients develop abnormal liver function tests or eventual frank jaundice secondary to bile duct stricture. The possibility of a post-traumatic bile duct injury should be considered in the differential diagnosis of obscure jaundice where no obvious cause can be ascertained.

Traumatic complications

Biliary leakage: biloma and biliary ascites

A biloma is a loculated collection of bile, generally in the subhepatic space, which may or may not be infected. Infected bilomas should be considered as a type of abscess and treated as such. Asymptomatic sterile bilomas should be allowed to reabsorb, assuming the bile leak resolves either spontaneously or via intervention. Symptomatic or persistent bilomas can be drained percutaneously under radiological guidance to facilitate resolution. Biliary ascites is caused by the disruption of a major bile duct.

Fistula

Biliary fistula occur in approximately 3% of patients with major hepatic injuries (Donovan et al, 1973). They can communicate with intrathoracic structures (broncho-biliary or a pleurobiliary fistula) or vascular structures (either arterial or venous). Most communications with intrathoracic structures settle spontaneously as a result of the pressure differences between the biliary tract and chest cavity; endoscopic retrograde cholangiopancreatography and sphincterotomy can be used to decrease the pressure in the biliary system further and facilitate closure of the fistula tract (Burch and Moore, 2006).

The manifestation of biliary-vascular fistula depends on the vessel involved and thus the pressure gradient between the vessel and biliary system. Arterial fistula result in haemobilia, which is characterized by upper gastrointestinal haemorrhage and sometimes by right upper quadrant pain and jaundice (Burch and Moore, 2006). Hepatic arteriography and embolization is useful in the diagnosis and management of this complication. Venous fistula (whether portal or hepatic) results in bilhaemia, with a rapid increase of bilirubin without much liver enzyme increase (Glaser et al, 1994).

Biliary stricture

Traumatic injuries to the biliary tree may disrupt the axial blood supply of the common bile duct. As a result, an ischaemic stricture may result some weeks to months later and manifest as painless jaundice; if left untreated, patients will develop liver failure. The size and location of

the stricture influences management, which can either be via endoscopic or radiological dilatation, with or without a stent, or by hepaticojejunostomy.

Investigations

Investigation of biliary trauma depends on the likely mechanism of injury and the haemodynamic stability of the patient. Unstable trauma patients may need to undergo immediate laparotomy, and the biliary injury can be overlooked in those with multiorgan damage (Gupta et al, 2004). Computed tomography provides the mainstay of preoperative diagnosis, but other radiological and endoscopic techniques can be used for assessment in stable patients where there is diagnostic uncertainty or in the management of delayed traumatic stricture (Becker et al, 1998).

Haematological

Immediately following trauma many routine blood tests will either be normal or non-diagnostic of biliary injury. Delayed investigation may show signs of elevated inflammatory markers in patients with abdominal sepsis. Those with biliary stricture will have impaired liver function and may also develop hypoalbuminaemia and clotting defects (prolonged prothrombin time). An excessively high serum level of direct bilirubin in the presence of only moderately elevated liver enzymes may indicate bilhaemia if no other cause can be identified (Glaser et al, 1994).

Radiological

Ultrasonography

Ultrasonography is of limited value in the immediate management of trauma patients and, as such, has largely been superseded by computed tomography. It does provide assessment of both the abdominal cavity (to detect concurrent injuries or fluid collections) and the biliary tree to provide a measurement of the common bile duct, which is not dilated following ductal laceration. Serial scans can be beneficial in following contained intra- or perihepatic bilomas that are treated conservatively (Gupta et al, 2004). Delayed traumatic biliary strictures, with associated dilatation of the biliary tree, can be detected via ultrasonography.

Computed tomography

Bile duct injuries can be detected on computed tomography in the form of extrahepatic bile collections or dilated ducts, although active extravasation of bile cannot be seen (Becker et al, 1998). Computed tomography is the imaging modality of choice in trauma patients as it can show associated liver lacerations, ascites and focal perihepatic collections, all of which raise the possibility of bile duct injury (Erb et al, 1994). The presence of a collapsed gall bladder with pericholecystic fluid in a fasting patient suggests gall bladder perforation (Gupta et al, 2004).

Magnetic resonance cholangiopancreatography

Magnetic resonance cholangiopancreatography is used extensively for iatrogenic injuries, but its use in the trauma patient is not well reported and, as such, is often confined to follow up of biliary injuries (Fulcher et al, 2000). Magnetic resonance cholangiopancreatography has a number of advantages over endoscopic retrograde cholangiopancreatography: it is non-invasive and has greater availability, while retaining a high sensitivity in detecting injuries (85–90%) (Gupta et al, 2004). Magnetic resonance cholangiopancreatography also allows evaluation of the liver parenchyma and can demonstrate associated fluid collections.

Biliary scintigraphy

Radionuclide studies with technetium-99m (^{99m}Tc) iminodiacetic acid is a useful investigation for revealing the presence and location of active bile extravasation (Fulcher et al, 2000). It is highly sensitive in detecting bile leakage, but delayed scans at 4 hours are essential to demonstrate a slow leak (Gupta et al, 2004).

Percutaneous transhepatic cholangiography

This invasive technique can be useful in assessing the biliary tract proximal to the site of injury, especially in cases of complete occlusion or transection of the main duct. Although its diagnostic role has been largely superseded by the availability of magnetic resonance cholan-

giopancreatography, percutaneous transhepatic cholangiography does allow extended decompression of the biliary tree in a patient with cholangitis or deep jaundice.

Endoscopic

Endoscopic retrograde cholangiopancreatography

Endoscopic retrograde cholangiopancreatography has both a diagnostic and therapeutic role in the management of biliary injury, and can be used intraoperatively. It will demonstrate both bile duct disruption (*Figure 1*) and biliary-vascular fistula, and it allows therapeutic stent placement (Glaser et al, 1994). Endoscopic retrograde cholangiopancreatography demonstrates the biliary system more easily than percutaneous transhepatic techniques, particularly if the bile ducts are non-dilated and difficult to cannulate from above, although it may have difficulty displaying the proximal biliary tree if there is major ductal disruption with extravasation of bile (Gupta et al, 2004).

Operative

Often biliary tract injuries are diagnosed incidentally at laparotomy for penetrating or blunt abdominal trauma (Bade et al, 1989). The indications for operation have usually been peritonitis or shock as a result of an associated injury, and patients may require four-quadrant packing and damage control surgery (Burch and Moore, 2006; Williamson and Williamson, 2012). Biliary injury is diagnosed by noting the accumulation of bile in the upper quadrant during any laparotomy for trauma. Potentially bile can be seen actively leaking from the porta hepatis or the gall bladder.

If there is a concern about biliary injury the duodenum should be reflected medially to explore the retroperitoneal biliary tree. The bile duct, portal vein and hepatic artery should also be dissected to identify injuries to each structure. Intraoperative cholangiography (via cannulation of the bile duct, cystic duct or even gall bladder) can be helpful in this context along with endoscopic retrograde cholangiopancreatography and intraoperative ultrasonography (Fabian et al, 2002).

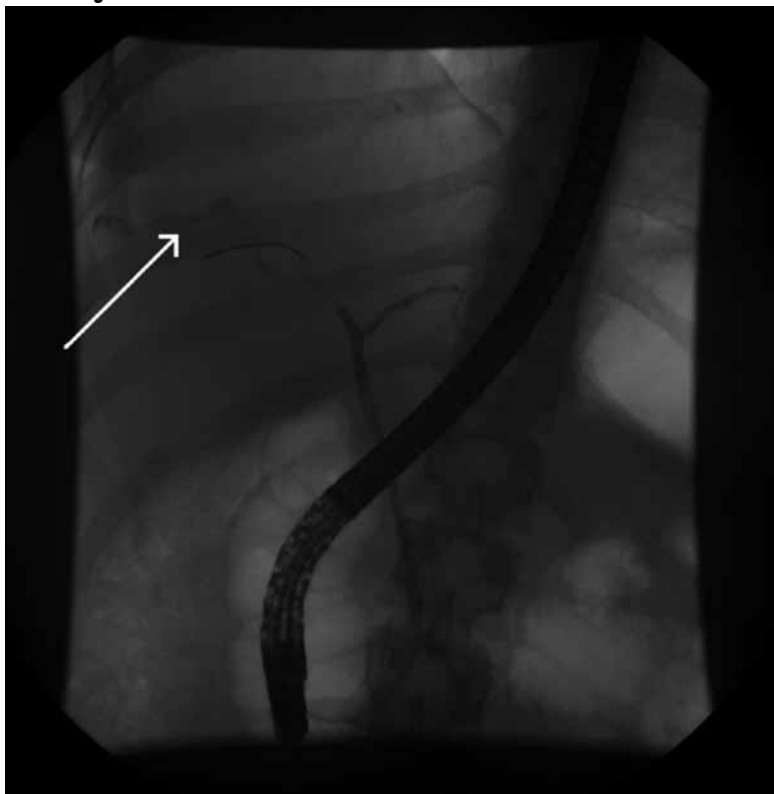
Classification of injury

The American Association for the Surgery of Trauma organ injury scale (*Table 1*) is a valuable guide to management (Moore et al, 1995; Burch and Moore, 2006).

Management

Treatment depends upon the mechanism of injury, the stability of the patient, the location and grade of injury, and the delay in reaching a diagnosis. Unstable trauma patients may have their biliary injuries first detected during a resuscitative laparotomy, in which case subsequent operative management should be undertaken. The operating surgeon's experience can be supplemented with advice from a specialist hepatopancreatobiliary surgeon regarding immediate management.

Figure 1. Endoscopic retrograde cholangiopancreatography showing extravasation of contrast from an intrahepatic ductal injury (arrow) in a 25-year-old woman who fell down a flight of stairs.



Damage control surgery

In unstable patients with multiple trauma to abdominal organs, treatment of the bile duct injury is of lower priority. Damage control surgery is the main objective in this situation (Williamson and Williamson, 2012); drainage of the biliary system and perihepatic area is sufficient to provide temporary relief (Feliciano, 1994). Alternatively, an end tube choledochostomy secured to the proximal bile duct will create a controlled external fistula and allow rapid identification at reoperation. However, these simple manoeuvres are associated with high biliary stricture and morbidity rates.

Gall bladder trauma

Injuries to the gall bladder are probably best managed by cholecystectomy. Although suture repair of lacerations has also been advocated (Burch and Moore, 2006), it runs the risk that any mural contusions will become necrotic and perforate. In addition, the preserved traumatized gall bladder may undergo the cycle of infection, non-function and stone formation. Clot retention leading to gall bladder stone has been described in the aftermath of blunt abdominal trauma (Luzuy et al, 1987).

Common bile duct trauma

Treatment of common bile duct injuries after external trauma is complicated by the small size and thin wall of the normal duct, which render primary repair almost impossible unless the laceration is small and there is no tissue loss (Burch and Moore, 2006). The main factors dictating treatment are the nature of the transection, whether partial or complete, and the location of the injury (Bade et al, 1989). Partial transections (typically less than 25% of circumference) should be amenable to suture repair and rarely give biliary complications; using a T-tube may facilitate small duct repair (Sawaya et al, 2001). With complete transection or lacerations above 25–50% of ductal circumference, a simple end-to-end repair is associated with a high incidence of stricture formation. As a result, a Roux-en-Y hepaticojejunostomy or choledochojejunostomy is preferable (Burch and Moore, 2006). Cholecystjejunostomy has fallen out of favour as the gall bladder is considered an inferior conduit to the bile duct (Bade et al, 1989; Feliciano, 1994).

Injuries to the intrapancreatic portion of the common bile duct are treated by dividing the duct at the superior border of the pancreas, ligating the distal portion and performing a Roux-en-Y choledochojejunostomy (Burch and Moore, 2006).

Intrahepatic ductal trauma

Treatment of injuries to the left or right hepatic duct is even more difficult in an emergency context, so it is questionable whether repair should even be attempted. If only one hepatic duct is injured, a reasonable approach is to ligate it and deal with any infection or atrophy of the hemi-liver rather than to attempt repair (Howdieshell et

al, 1990; Burch and Moore, 2006). If both ducts are injured, each should be intubated with a small catheter brought through the abdominal wall. Once the patient has recovered sufficiently, delayed repair is performed under elective conditions.

Endoscopic management

Endoscopy has a number of advantages over open operation in the management of small traumatic biliary leaks as it does not require a general anaesthetic and provides effective biliary drainage. Endoscopic decompression of the biliary tree alone can decrease ductal pressure and allow healing of ductal lacerations or biliovenous fistulas (Glaser et al, 1994; Singh et al, 2007).

The optimal endoscopic technique is currently under debate. Some authors recommend use of a nasobiliary drain, which permits a follow-up cholangiogram for checking closure of leak, is easy to remove and does not require a repeat endoscopy, but the tube is uncomfortable for the patient (Singh et al, 2007). Others believe that transpapillary stenting, with or without sphincterotomy, is superior because it decreases the pressure gradient across the sphincter of Oddi (Foutch et al, 1993; Singh et al, 2007). Large bile leaks will usually require stent placement, whereas small leaks can be managed by sphincterotomy alone (Bajaj et al, 2006). To avoid the potential complications of endoscopic sphincterotomy, some authors advocate temporary biliary stenting alone as the best endoscopic intervention for biliary leakage (Kaffe et al, 2005).

Delayed management of biliary trauma and biliary strictures

Definitive management of biliary injuries and associated complications should be considered following stabiliza-

Table 1. American Association for the Surgery of Trauma (AAST) organ injury scale for biliary tract (advance one grade for multiple injuries, up to grade III)

AAST grade	Definition
I	Gall bladder contusion or haematoma
	Portal triad contusion
II	Partial gall bladder avulsion from liver bed; cystic duct intact
	Laceration or perforation of gall bladder
III	Complete gall bladder avulsion from liver bed
	Cystic duct laceration
IV	Partial or complete right or left hepatic duct transection
	Partial common hepatic duct or common bile duct lacerations (<50%)
V	>50% transection of common hepatic duct or common bile duct
	Combined right and left hepatic duct injuries
	Intraduodenal or intrapancreatic bile duct injuries

from Moore et al (1995)

tion of the patient and possible damage control surgery. Some apparently minor injuries may only present some weeks to months after the episode of trauma, and those should be managed as any biliary stricture. Regardless of the causative mechanism, patients with biliary injuries should be discussed at a specialist hepatopancreatobiliary multidisciplinary team meeting. The entirety of the biliary tree should be evaluated to improve the success rate of any intervention.

Operative management: definitive bile duct repair

The preferred operation for repair of a bile duct injury is almost always a Roux-en-Y hepaticojejunostomy, using a defunctioned loop of upper small bowel to create a tension-free mucosa-to-mucosa anastomosis (with or without the use of a trans-anastomotic stent) (Sawaya et al, 2001). This is a demanding operation because the bile ducts are often of normal diameter, and a satisfactory anastomosis usually necessitates dissection high up in the hepatic hilum. Theoretically a high anastomosis is preferable because of the critical blood supply to the supra-duodenal bile duct (Terblanche et al, 1990), but most surgeons prefer to avoid more dissection within the hilum than is necessary to allow a healthy and accessible stump of duct to suture. A marked access loop, whereby the end of the jejunal loop is sutured to the abdominal wall and marked with surgical clips, can be constructed in a difficult anastomosis; it facilitates percutaneous puncture of the jejunum for radiological dilatation of a late anastomotic stenosis from below.

Non-operative management of traumatic biliary strictures

Both endoscopy and interventional radiology play an important role in the management of traumatic biliary strictures. Dilatation and insertion of a biliary prosthesis at endoscopic retrograde cholangiopancreatography is the most frequently used non-surgical method. The success rates of endoscopic and surgical management for bile duct injury are comparable (72 vs 83%), and likewise the rate

of complications (35 vs 26%) (Jaik et al, 2008). Common complications of biliary prostheses include cholangitis, pancreatitis, perforation of the bile duct and either occlusion, migration or dislodgement of the prosthesis.

Interventional radiology can be invaluable in the management of traumatic biliary stenosis. Two main techniques are used: transhepatic stenting and percutaneous dilatation. Transhepatic stenting is effective in 40–85% of patients (Jabłońska and Lampe, 2009). Common complications include haemorrhage (haemobilia, bleeding from hepatic parenchyma or adjacent vessels), bile leakage and cholangitis. Other complications include pneumothorax (resulting from pleural transgression) and, less commonly, perforation of adjacent structures (gall bladder and large bowel). Percutaneous dilatation alone is less effective than surgical treatment, with success rates of 52% compared to 89% for operative intervention (Jabłońska and Lampe, 2009). The radiological approach is associated with a higher number of complications than operative management (35% vs 25%) (McMahon et al, 1995). As a result, it is mostly indicated for difficult cases of hilar stricture or very small bile ducts.

Conclusions

Traumatic injuries to the biliary tree should be considered in two particular contexts: unstable patients with trauma to other organs in the upper abdomen and those who present with vague abdominal symptoms or abnormal liver function tests at some distance in time from the trauma. An unstable trauma patient is usually best served with damage control surgery before attempting definitive repair. For those with a delay in diagnosis, multimodal management is best, each patient being discussed by a specialist multidisciplinary team. **BJHM**

The author would like to thank Professor RCN Williamson for editorial assistance.

Conflict of interest: none.

KEY POINTS

- Traumatic biliary injuries are rare and tend to be associated with damage to other abdominal organs.
- Immediate management depends on the condition of the patient and the complexity of injury.
- Unstable patients should receive damage control surgery, with definitive management deferred until the patient is more stable.
- Missed injuries present with external leakage, progressive biliary ascites or sometimes indolent liver failure. All such injuries should be discussed at a multidisciplinary hepatopancreatobiliary meeting, where radiological, endoscopic and operative interventions are considered
- A one-off formal repair (hepaticojejunostomy Roux-en-Y) in experienced hands offers the best chance of long-term success.

- Bade PG, Thomson SR, Hurshberg A, Robbs JV (1989) Surgical options in traumatic injury to the extrahepatic biliary tract. *Br J Surg* **76**: 526–8
- Bajaj JS, Spinelli KS, Dua KS (2006) Postoperative management of noniatrogenic traumatic bile duct injuries: role of endoscopic retrograde cholangiopancreatography. *Surg Endosc* **20**: 974–7
- Becker CD, Mentha G, Schmidlin F, Terrier F (1998) Blunt abdominal trauma in adults: the role of CT in the diagnosis and management of visceral injuries. *Eur Radiol* **8**: 772–80
- Burch JM, Moore EE (2006) Injuries to the liver, biliary tract, spleen, and diaphragm. In: Souba WW, Fink MP, Jurkovich GJ et al, eds. *ACS Surgery: principles and practice*. WebMD Professional Publishing, New York, NY
- Burgess P, Fulton RL (1992) Gallbladder and extrahepatic biliary duct injury following abdominal trauma. *Injury* **23**: 413–14
- Chen X, Talner LB, Jurkovich GJ (2001) Gallbladder avulsion due to blunt trauma. *Am J Roentgenol* **177**: 822
- Donovan AJ, Michaelian MJ, Yellin AE (1973) Anatomical hepatic lobectomy in trauma to the liver. *Surgery* **73**: 833–47
- Erb RE, Mirvis SE, Shanmuganathan K (1994) Gallbladder injury secondary to blunt trauma: CT findings. *J Comput Assist Tomogr* **18**: 778–84
- Fabian TC, Croce MA, Minard G et al (2002) Current issues in trauma. *Curr Prob Surg* **39**: 1160–244

- Feliciano DV (1994) Biliary injuries as a result of blunt and penetrating trauma. *Surg Clin North Am* **74**: 897–907
- Fouch PG, Harian JR, Hofer M (1993) Endoscopic therapy for patients with a postoperative biliary leak. *Gastrointest Endosc* **39**: 416–21
- Fulcher AS, Turner MA, Yelon JA, McClain LC, Broderick T, Ivatury RR, Sugerman HJ (2000) Magnetic resonance cholangiopancreatography (MRCP) in the assessment of pancreatic duct trauma and its sequelae: preliminary findings. *J Trauma* **48**: 1001–7
- Howdieshell TR, Hawkins ML, Osler TM, Demarest GB (1990) Management of blunt hepatic duct transection by ligation. *South Med J* **83**: 579
- Glaser L, Wetscher G, Pointner R, Schwab G, Tschmelitsch J, Gadenstätter M, Bodner E (1994) Traumatic bilhemia. *Surgery* **116**: 24–7
- Gupta A, Stuhlfaut JW, Fleming KW, Lucey BC, Soto JA (2004) Blunt trauma of the pancreas and biliary tract: a multimodality imaging approach to diagnosis. *Radiographics* **24**: 1381–95
- Jablońska B, Lampe P (2009) Iatrogenic bile duct injuries: etiology, diagnosis and management. *World J Gastroenterol* **15**: 4097–104
- Jaik NP, Hoey BA, Stawicki SP (2008) Evolving role of endoscopic retrograde cholangiopancreatography in management of extrahepatic ductal injuries due to blunt trauma: diagnostic and treatment algorithms. *HPB Surg* 259141
- Jeffrey RB Jr, Fedderle MP, Laing FC, Wing VW (1986) Computed tomography of blunt trauma to the gallbladder. *J Comput Assist Tomogr* **10**: 756–8
- Kaffe AJ, Hourigan L, Luca ND, Byth K, Williams SJ, Bourke MJ (2005) Impact of endoscopic intervention in 100 patients with suspected postcholecystectomy bile leak. *Gastrointest Endosc* **61**: 269–75
- Luzuy F, Reinberg O, Kauszlaric D, Anderegg A, Droguett M, Donati D, Sandblom P (1987) Biliary calculi caused by haemobilia. *Surgery* **102**: 886–9
- McMahon AJ, Fullarton G, Baxter JN, O'Dwyer PJ (1995) Bile duct injury and bile leakage in laparoscopic cholecystectomy. *Br J Surg* **82**: 307–13
- Moore EE, Cogbill TH, Jurkovich GJ, Shackford SR, Malangoni MA, Champion HR (1995) Organ injury scaling spleen and liver (1994 revision). *J Trauma* **38**: 323–4
- Sawaya DE, Johnson LW, Sittig K, McDonald JC, Zibari GB (2001) Iatrogenic and noniatrogenic extrahepatic biliary tract injuries: a multi-institutional review. *Am Surg* **67**: 473–7
- Singh V, Narasimhan KL, Verma GR, Singh G (2007) Endoscopic management of traumatic biliary injuries. *J Gastroenterol Hepatol* **22**: 1205–9
- Terblanche J, Worthley CS, Spence RA, Krige JE (1990) High or low hepaticojejunostomy for bile duct strictures? *Surgery* **108**: 828–34
- Williamson JML, Williamson RCN (2012) Managing pancreatoduodenal trauma. *Br J Hosp Med* **73**: 335–40

Organised by

BRITISH JOURNAL OF
**HOSPITAL
MEDICINE**

6th national conference

Addiction and the Liver 2013

Hallam Conference Centre, London
12th & 13th June 2013

Benefits of attending:

- Review the current status and future picture of substance-related liver disease in the UK
- Update your knowledge on treatments for hepatitis in drug users
- Assess current treatment options for alcohol-related liver disease and alcohol dependence
- Take part in interactive case studies

To book your place:



Call Jackie on +44(0)20 7501 6762



www.mahealthcarevents.co.uk/addliver2013

DISCOUNTED
RATE AVAILABLE UNTIL
29TH MARCH 2013

