

Ultrasound of the gall bladder and biliary tree: part 1

Ultrasound is the modality of choice for the initial assessment of the gall bladder and the biliary tree. This article is the first of two, and details normal ultrasound appearances of the gall bladder, as well as appearances of cholecystitis, sludge, adenomyomatosis, polyps, carcinoma and parasites.

Ultrasound is the modality of choice in the initial investigation of suspected gall bladder and biliary tree pathology. Ultrasound is accurate, highly sensitive, non-invasive, readily available and inexpensive. Some common indications for sonography of the liver and biliary tree include the investigation of jaundice, upper abdominal pain and abnormal liver function tests (Bennett and Balthazar, 2003; Hayes, 2004; Smith, 2011). This article is the first of two looking at the role of ultrasound in the investigation of gall bladder and biliary pathology. This article covers normal ultrasound appearances of the gall bladder, as well as appearances of cholecystitis, sludge, adenomyomatosis, polyps, carcinoma and parasites. The second article (p. 318) covers normal ultrasound appearances of the biliary tree, as well as appearances of biliary obstruction, biliary cirrhosis, biliary gall-stones, developmental disorders, choledochal cysts, cholangiopathies, cholangiocarcinoma and ultrasound-guided interventional procedures.

Technique

Patients should fast for a minimum of 4 hours before ultrasound examination. This is to reduce bowel gas and allow maximal distension of the gall bladder and therefore diagnostic interrogation of the gall bladder lumen and wall. Patients are scanned supine, with a 2–3 MHz curvilinear probe. The gall bladder can be visualized by scanning at the right costal margin or intercostally. Turning the patient halfway to his/her left (left posterior oblique position) and scanning subcostally in full inspiration is a good way to visualize the gall bladder. If not visible, check that the patient has not had a cholecystectomy as this will often save time and fruitless efforts. The whole gall bladder should be assessed in longitudinal and

transverse planes to avoid missing pathology. If any abnormality is detected within the lumen, the patient should be moved to see if the lesion is mobile or attached to the wall. Doppler ultrasound allows assessment of the wall vascularity, which should be minimal and normally should not extend more than halfway along the wall. Gall bladder thickening and increased vascularity is indicative of active inflammation.

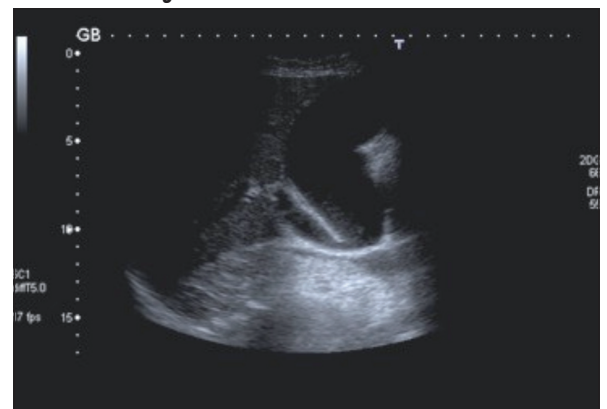Normal appearances

The gall bladder can vary significantly in size and is particularly affected by the postprandial state when it is contracted. The gall bladder content should be entirely anechoic (*Figure 1*). The normally distended gall bladder wall should measure no more than 2 mm in thickness. A variety of pathologies is associated with gall bladder wall thickening (*Table 1*) (*Figure 2*).

Apart from cholecystectomy and biliary atresia, failure to visualize the gall bladder may be caused by lack of fasting, congenital absence, anomalous position, cystic fibrosis (microgall bladder), perforation and replacement of the gall bladder by carcinoma.

There are a number of normal variants of the gall bladder. It may have a folded appearance called a Phrygian cap (*Figure 3*). This may be unfolded by turning the patient decubitus. The gall bladder has a mesentery which can vary in length such that the gall bladder may be intrahepatic (invested by liver on all sides) or may hang down so that the fundus lies in the pelvis while the

Figure 1. Normal gall bladder. The bile in the gall bladder is anechoic and the gall bladder wall measures <2 mm in thickness.



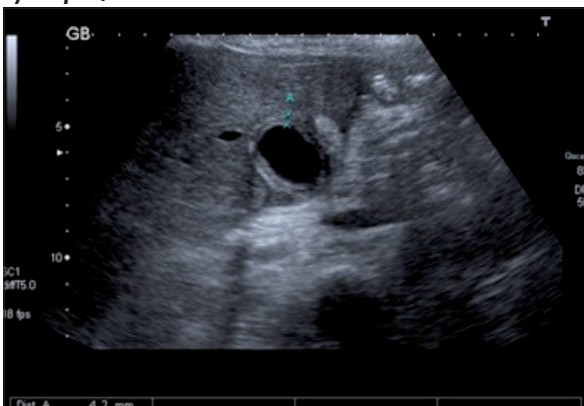Dr Mark Wills is Radiology Registrar and **Dr Chris J Harvey** is Consultant Radiologist in the Department of Imaging, Hammersmith Hospital, Imperial College NHS Trust, London W12 0HS, **Dr Sjarhei Kuzmich** is Consultant Radiologist in the Department of Radiology, Whipps Cross Hospital, London, **Dr Asim Afaq** is Senior Clinical Research Associate and Honorary Radiology Consultant in the University College London Hospitals Biomedical Research Centre, London and **Professor David Cosgrove** is Emeritus Professor of Clinical Ultrasound, Hammersmith Hospital, London

Correspondence to: Dr CJ Harvey (chris.harvey@imperial.nhs.uk)

Table 1. Pathological causes of gall bladder wall thickening

Inflammatory	Cholecystitis (acute or chronic)
	Sclerosing cholangitis
	AIDS (acquired immunodeficiency syndrome)
Non-inflammatory	Gall bladder carcinoma
	Adenomyomatosis (the mural thickening may be focal)
	Focal thickening caused by polyps or metastases
Peri-inflammatory	Hepatitis
	Pancreatitis
Oedema	Ascites (any cause)
	Hypoalbuminaemia
	Congestive cardiac failure
	Renal failure
	Cirrhosis
	Portal hypertension

Figure 2. Thickened gall bladder wall. In transverse section the gall bladder wall is pathologically thickened, measuring 4 mm (indicated by callipers).



neck is normally sited. Also, rarely, the gall bladder may be septated or even more rarely, truly duplicated.

Gall-stones

Gall-stones are the commonest gall bladder pathology encountered in clinical practice – but most patients are asymptomatic and calculi are an incidental finding in 10% of the UK population. The majority of stones are predominantly cholesterol-rich and therefore occur in conditions where there is increased excretion of cholesterol in the bile such as obesity, pregnancy, diabetes and oestrogen therapy. Pigment stones occur when there is increased secretion of bilirubin such as in cirrhosis and haemolytic anaemias, e.g. sickle cell disease.

Classically, gall-stones are seen as echogenic luminal structures regardless of their composition. Since sound cannot penetrate stones, they are seen as curvilinear structures, which cast an acoustic shadow (*Figure 4*). Stones will only cast a shadow if the stone fills the full width of the ultrasound beam, which easily occurs with large stones. However, small stones may not fulfill this criterion unless they are sited in the centre or at the focal zone (narrowest point) of the beam.

Gall-stones can vary considerably in size and the neck of the gall bladder should be carefully assessed for small

Figure 3. Phrygian cap (arrow) (normal variant) of a folded gall bladder.

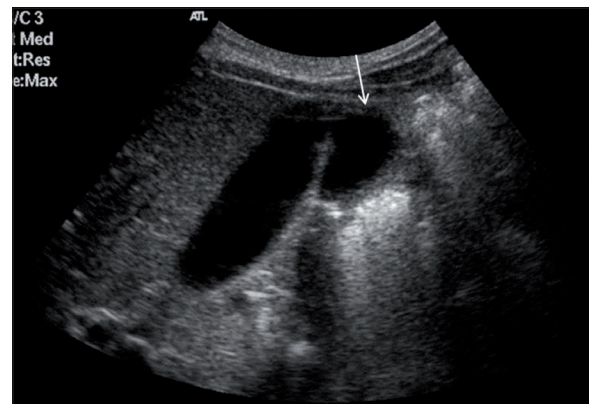
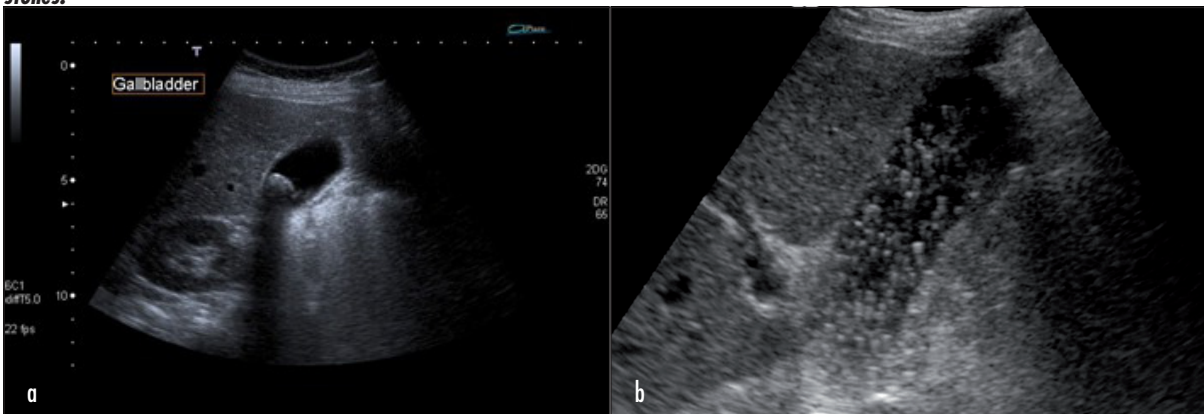


Figure 4. Gall-stones in the gall bladder. a. Seen in transverse section, there is a 1.2 cm calculus in the gall bladder, casting an acoustic shadow. The gall bladder wall is of normal thickness. b. In a different patient the gall-stone is filled with numerous smaller 'floating' gall-stones.



stones. It is essential to ensure that an apparent stone in the gall bladder is not a polyp. A stone can be confirmed by moving the patient while scanning to show mobility, whereas a polyp is stationary.

Echogenic bile

Inspissation of bile may result in echogenic sludge in the gall bladder (Figure 5), which occurs in biliary stasis. In this case, there are no discrete stones, but a dependent echogenic layering within the gall bladder which moves slowly with patient repositioning. Occasionally sludge can clump together and mimic polyps or masses, known as tumefactive sludge or lumpy bile (Figure 6). Sludge does not exhibit posterior acoustic shadowing (in contrast to stones) and can be distinguished from true masses by turning the patient (which breaks up the sludge ball as it moves) or by rescanning after the patient has resumed a normal diet. Sludge is a common finding in postoperative patients, those on intensive care and those receiving parenteral nutrition. Sludge usually resolves once the patient returns to a normal diet but biliary stasis predisposes to stone formation. The empty-

Figure 5. Gall bladder sludge. Gall bladder sludge appears as echogenic material that layers in a dependent manner within the gall bladder lumen; the fluid–fluid level moves slowly with patient repositioning.

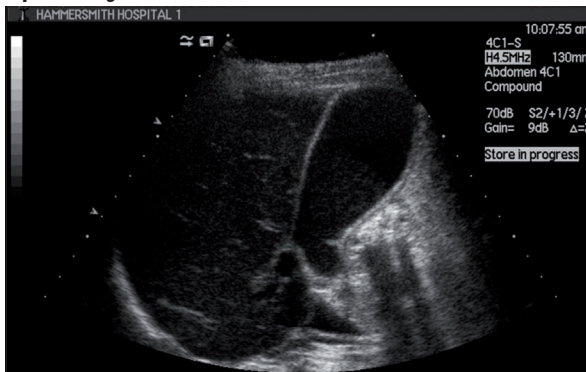
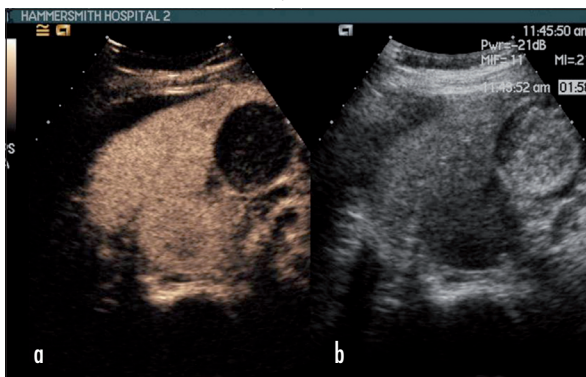


Figure 6. Tumefactive gall bladder sludge. a. The sludge within the lumen of this gall bladder has clumped together to form an echogenic ball that mimics a gall bladder mass. b. A contrast-enhanced ultrasound study was performed which demonstrates no perfusion of the tumefactive sludge (compared with a gall bladder carcinoma which would enhance).



ing of sludge into the biliary tree can cause biliary colic, acute pancreatitis and cholecystitis.

Cholecystitis

Acute cholecystitis is caused by gall bladder neck or cystic duct obstruction, usually by a calculus (90% of cases). The patient classically presents with right upper quadrant pain, fever and leukocytosis. Ultrasound is the initial modality of choice to confirm the diagnosis (sensitivity 85–94%). The ultrasound signs may be divided into major and minor signs. The major signs are gall bladder stones, ‘splitting’ of the gall bladder wall with an echopoor, oedematous middle layer, gas in the gall bladder wall, a positive sonographic Murphy’s sign and increased colour Doppler signals in the gall bladder wall. Minor signs include gall bladder wall thickening (greater than 3mm), echogenic debris in the bile (caused by pus, blood or sludge), and pericholecystic fluid (Figure 7). Complications of acute cholecystitis include gangrene, perforation (5–10%), emphysematous cholecystitis and empyema of the gall bladder.

Gangrenous cholecystitis is seen as an irregular, shaggy, asymmetrically thickened gall bladder wall with mural microabscesses (Figure 8). Perforation may lead to peritonitis or a pericholecystic abscess, necessitating emergency cholecystectomy.

Figure 7. Acute cholecystitis. Power Doppler demonstrating gall bladder wall thickening and hypervascularity, with a rim of pericholecystic fluid.

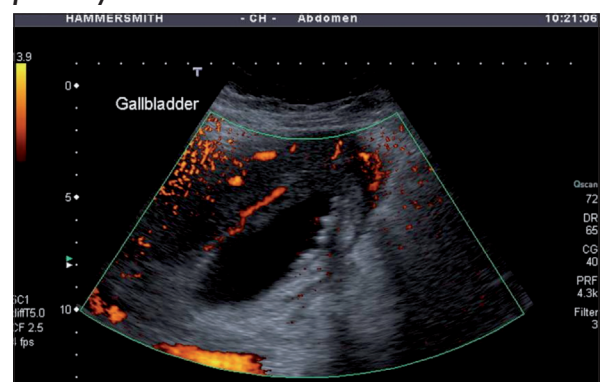
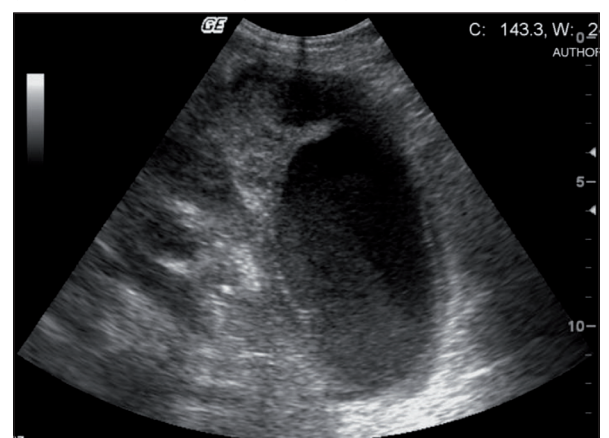


Figure 8. Gangrenous cholecystitis seen as asymmetrical, irregular gall bladder wall thickening with echogenic bile.



Emphysematous cholecystitis (Figure 9) is a form of gangrenous cholecystitis when the gall bladder becomes infected with gas-forming organisms, especially in diabetics. Gas may be seen in the lumen or within the gall bladder wall. This has a higher mortality than other types of cholecystitis. In empyema of the gall bladder (Figure 10) the lumen becomes full of pus and is characterized clinically by high fever and severe pain. Ultrasound can be used to guide insertion of a cholecystostomy tube in patients who are unfit for surgery. Following acute or chronic recurrent cholecystitis, a fistula with the colon or duodenum may develop with passage of stones into the bowel where they may travel distally down the bowel and impact at the ileocaecal junction causing obstruction (gall-stone ileus).

Chronic cholecystitis manifests on ultrasound as a thick-walled, shrunken and contracted gall bladder around stones. Clinically there may be a history of low-grade recurrent right upper quadrant pain and/or recurrent bouts of acute cholecystitis.

Acalculous cholecystitis

This condition is uncommon and occurs in hospitalized patients, particularly those who are postoperative, on intensive care, post burns or trauma, and in diabetics. The

Figure 9. Emphysematous cholecystitis. The gall bladder demonstrates echogenic locules of gas in the gall bladder lumen, along with marked gall bladder wall thickening and linear mural gas (arrows).

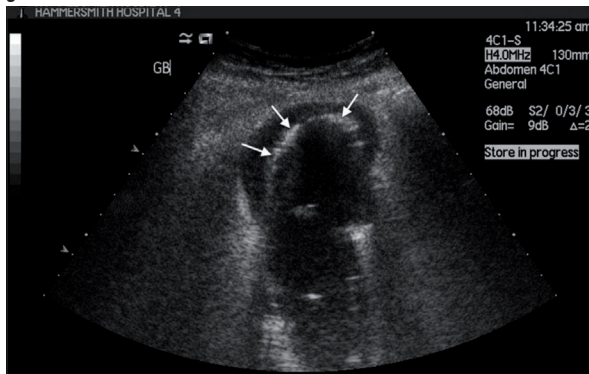
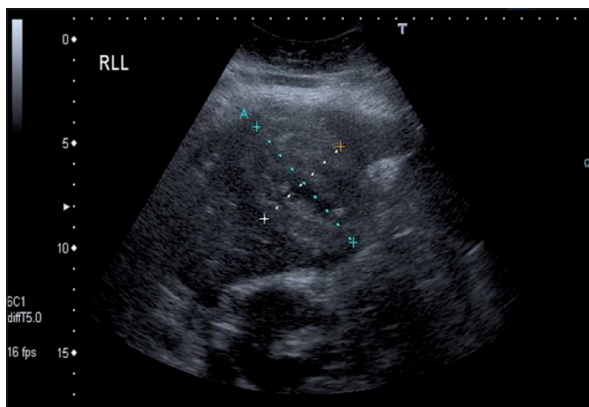


Figure 10. Gall bladder empyema. B-mode image of the gall bladder (indicated with callipers) full of echogenic pus. The patient presented with a high fever and severe right upper quadrant pain.



mechanism is thought to be biliary stasis causing gall bladder distension and ischaemia of the gall bladder wall (Figure 11). This can predispose to infection as the patient is debilitated. The diagnosis is usually delayed (because of the absence of gall-stones), increasing the likelihood of complications such as perforation (Figure 12).

Cholesterosis (strawberry gall bladder)

Cholesterol and triglyceride deposition occurs within the mucosa of the gall bladder wall and is associated with an

Figure 11. Acalculous cholecystitis. a. Longitudinal view of the gall bladder demonstrates distension and wall thickening with 'splitting' (echopoor middle layer of the wall) in the absence of gall-stones. There is some echogenic sludge within the lumen. b. Colour Doppler demonstrates a hypervascular gall bladder wall.

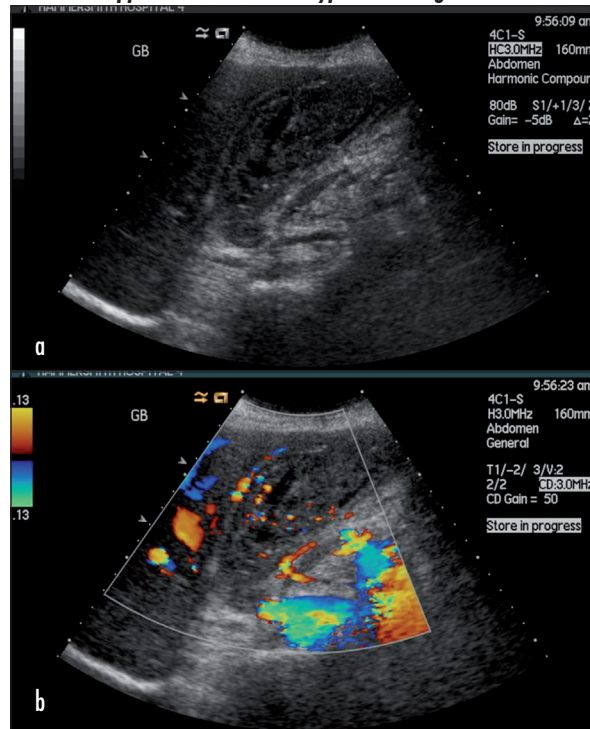
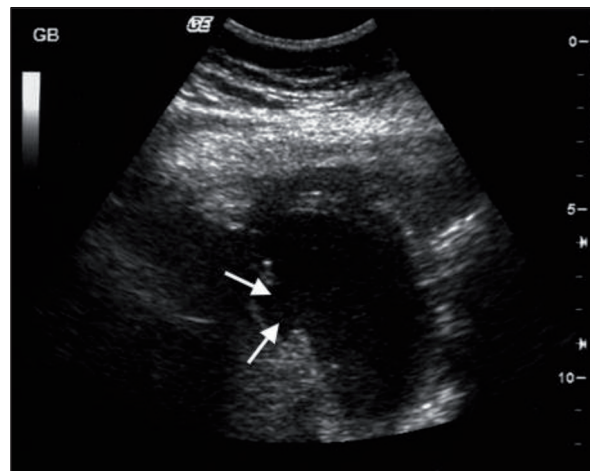


Figure 12. Gall bladder perforation. Longitudinal view of the gall bladder demonstrating a defect (arrows) of the gall bladder wall indicating perforation.



increased incidence of cholesterol gall-stones. Multiple or single polyp-like nodules are seen projecting into the lumen. The condition may be asymptomatic or may be accompanied by stones that cause symptoms.

Adenomyomatosis

This benign non-inflammatory hyperplastic condition is often an incidental finding requiring no specific treatment. There is wall thickening (involving the mucosa and muscularis propria) with diverticulae extending into the muscular layers of the wall. The wall thickening may be focal or diffuse. Ultrasound findings are highly specific with cholesterol crystals trapped in the Rokitsansky-Aschoff sinuses or diverticulae. These echogenic intramural foci give ‘comet tail’ reverberation artefacts seen as a twinkling sign on colour Doppler (Figure 13). The condition is usually asymptomatic but occasionally can present with biliary colic, which may be caused by coexistent stones. Cholecystectomy is performed in symptomatic patients (usually those with stones).

Gall bladder polyps

Polyps are usually asymptomatic and appear as focal immobile avascular echogenic lesions adherent to the wall. It is not possible to distinguish between a polyp and a focus of cholesterosis sonographically, as both will appear avascular and without any secondary signs of gall bladder pathology (Figure 14). Polyps greater than 1 cm in size require cholecystectomy because of an increased risk of carcinoma (especially in those over 50 years of age). Polyps less than 1 cm in size may be monitored with ultrasound. There is no agreed protocol on follow up but it is thought that polyps less than 6 mm have an extremely low risk of malignant change and do not require follow up (Corwin et al, 2011). Data are inconclusive for polyps of 7 mm or larger and therefore the follow-up protocol varies.

Gall bladder carcinoma

Carrying a poor prognosis, often presenting late, carcinoma of the gall bladder usually appears as a heterogeneously echogenic vascular mass which partially or

completely replaces the gall bladder, or as asymmetric lesions with marked gall bladder wall thickening (Wills et al, 2014). Invasion into the adjacent liver and biliary tree is likely. The polypoidal gall bladder carcinoma presents as an intraluminal mass which is fixed despite patient movement on scanning (Figure 15). This tumour is frequently asymptomatic in the early stages or may declare itself with symptoms related to stones. It has a poor prognosis and is usually inoperable. The tumour metastasizes to the liver and hilar lymph nodes.

There are a number of conditions associated with gall bladder carcinoma, including cholelithiasis, chronic cholecystitis, inflammatory bowel disease, primary sclerosing cholangitis and porcelain gall bladder (diffuse calcification of the gall bladder wall) (Figure 16).

Parasites

Biliary infestation with parasites such as *Ascaris lumbricoides* (Figure 17), *Clonorchiasis sinensis* (liver fluke) and *Fasciola hepatica* (cattle fluke) are common in tropical countries and may cause biliary obstruction, biliary colic, cholangitis and cholangiocarcinoma.

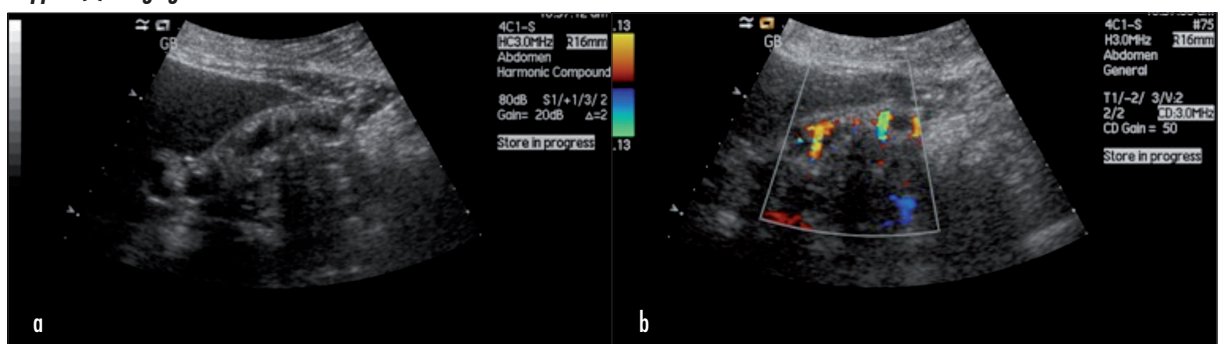
Conclusions

Ultrasound is the initial modality of choice to image the gall bladder and biliary tree. A range of benign and

Figure 14. Gall bladder polyp. A transverse section of the gall bladder demonstrates two small gall bladder polyps.

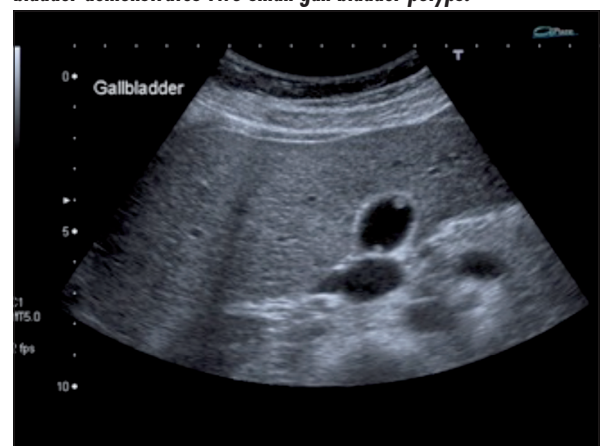

Figure 13. Adenomyomatosis, demonstrating (a) a comet tail reverberation artefact on B-mode and (b) the twinkling sign on colour Doppler (b) imaging.



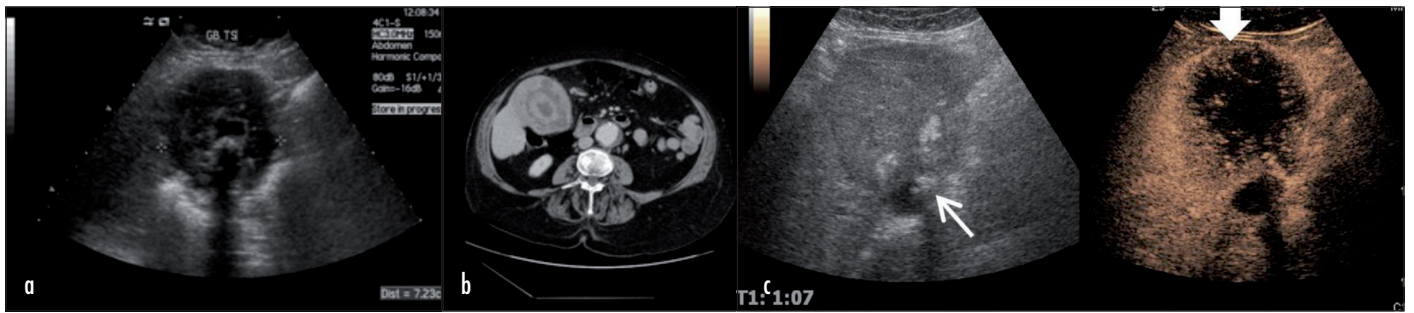


Figure 15. Gall bladder carcinoma. a. Ultrasound shows extensive circumferential thickening of the gall bladder wall with a central stone and **(b)** the corresponding axial contrast-enhanced computed tomography image. In a different patient **(c)** dual display contrast-enhanced ultrasound shows rim enhancement around a large tumour (thick arrow) with a non-enhancing necrotic centre arising from the gall bladder which contains echogenic stones (thin arrow).

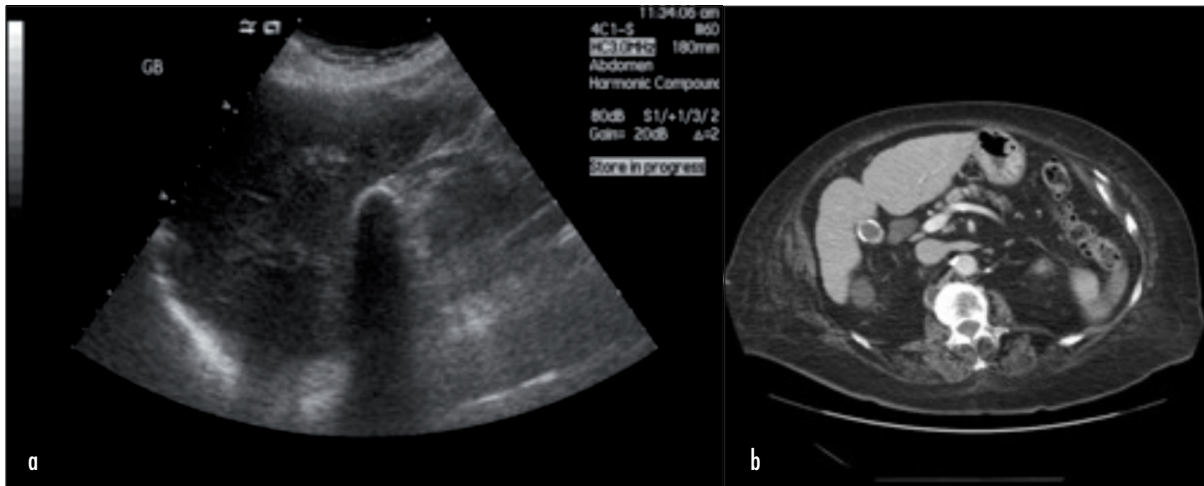
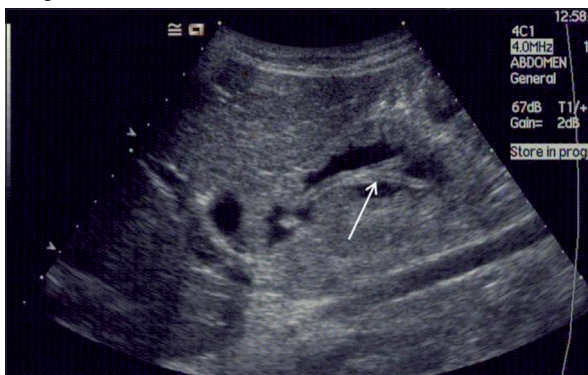

Figure 16. Porcelain gall bladder. a. Linear gall bladder wall calcification seen as echogenic change with posterior acoustic shadowing on ultrasound. **b.** Corresponding contrast-enhanced axial computed tomography image.

malignant pathologies affecting the gall bladder is described. Particularly for the more aggressive pathologies, the study should be extended to evaluate the entire upper abdomen, and should be supplemented by magnetic resonance cholangiopancreatography or computed tomography. [BJHM](#)

Figure 15 is reproduced from Wills et al (2014), and Figure 17 is reproduced courtesy of Dr Mukund Joshi, Mumbai, India.
Conflict of interest: none.

Figure 17. Roundworms in gall bladder seen as parallel linear echogenic structures (arrow).



Bennett G, Balthazar E (2003) Ultrasound and CT evaluation of emergent gallbladder pathology. *Radiol Clin North Am* 41: 1203–16

Corwin M, Siewert B, Sheiman R, Kane R (2011) Incidentally detected gallbladder polyps: is follow-up necessary? Long-term clinical and US analysis of 346 patients. *Radiology* 258: 277–82

Hayes R (2004) Abdominal pain: general imaging strategies. *Eur Radiol* 14 (Suppl 4): L123–37

Smith J (2011) Gallbladder and biliary tree. In: Allan P, Baxter G, Weston M, eds. *Clinical Ultrasound*. 3rd edn. Churchill-Livingstone, Edinburgh: 227–72

Wills M, Harvey C, Kuzmich S, Afaq A, Lim A, Cosgrove D (2014) Characterizing malignant liver lesions with contrast-enhanced ultrasound. *Br J Hosp Med (Lond)* 75(3): 151–4

KEY POINTS

- Ultrasound is widely used as the first-line imaging modality in the assessment of the gall bladder and biliary tree.
- Ultrasound has the advantages of low cost, real-time bedside imaging, accessibility, portability, lack of ionizing radiation, non-invasiveness, and multiplanar imaging.
- Ultrasound is very sensitive (more than computed tomography) in the detection of gall-stones.
- Ultrasound can also be used to guide interventions such as biliary intervention (percutaneous transhepatic cholangiography, drainage and stenting) and gall bladder drainage (cholecystostomy) in empyema.