

CORE TRAINING FOR DOCTORS

WHAT YOU NEED TO KNOW ABOUT

**Management of traumatic
digital amputations** C50

S Nicholson, A Platt

CLINICAL SKILLS FOR POSTGRADUATE EXAMINATIONS

Guide to the slit lamp C55

*Bashar R Mohammed, Showrob Patwary,
Georgios Vakrosc*

WHAT YOU NEED TO KNOW ABOUT

**Calcium pyrophosphate
deposition** C61

A Abhishek

COMING NEXT MONTH

WHAT YOU NEED TO KNOW ABOUT

Osteoarthritis

TIPS FROM THE SHOP FLOOR

**Intraoperative management of
coagulation**

WHAT THEY DON'T TEACH YOU IN MEDICAL SCHOOL

**Preoperative assessment of
anticoagulation**

Edited by **Dr Daniel JB Marks**, Academic Clinical Fellow in Translational Medicine, **Dr Philip J Smith**, Academic Clinical Fellow and Specialist Registrar in Gastroenterology, University College London and **Dr Jacob de Wolff**, Consultant Acute Physician, North West London Hospitals NHS Trust, Middlesex

Management of traumatic digital amputations

Introduction

Traumatic amputations of digits or parts thereof are not uncommon. Unfortunately for many, reattaching a severed body part is sometimes not possible, or not advisable because the eventual functional outcome would be poor. This article summarizes the key points in assessing a patient with an amputated part, with particular focus on the digits, and provides a guide to the decision-making process for whether an amputated part should be replanted or not. The practical elements of dealing with digital amputations in the emergency room are also covered.

Injury type

Replantation refers to the restoration of a completely amputated body part, usually with the aim of achieving as close to normal function as possible.

Revascularization is the restoration of circulation to an incompletely severed part. This encompasses a wide range of injury types, from simple division of digital arteries to a mangled hand in which peripheries are still attached by only a narrow skin bridge.

Mechanism

The mechanism of injury has implications for both the likelihood of success of restoring perfusion to an amputated digit, and the functional outcome. Broadly speaking, the mechanism of an amputation can be classified as clean-cut, crush-cut, or crush-avulsion.

Mr S Nicholson is ST5 in Plastic Surgery in the Department of Plastic Surgery, Pinderfields General Hospital, Wakefield WF1 4DG, and Mr A Platt is Consultant Plastic, Reconstructive and Aesthetic Surgeon in the Department of Plastic Surgery, Castle Hill Hospital, Hull and East Yorkshire NHS Trust, Cottingham, East Yorkshire

*Correspondence to: Mr S Nicholson
(si.nicholson@doctors.org.uk)*

Clean-cut or guillotine-type injuries are usually easier to replant because of the minimal collateral tissue trauma. Outcomes tend to be better, although these injuries are rare.

Far more frequent are the crush-cut or crush-avulsion type injuries sustained, for example, from power tools or industrial machines (Dec, 2006). In these injuries, there may be comminuted fractures, multi-level involvement and extensive vascular endothelial damage.

The latter is a key determinant in success of revascularization. It may be possible to anastomose divided digital blood vessels that are smaller than 1 mm in diameter, but a damaged endothelium can cause a high rate of thrombosis either at, proximal to, or distal to the anastomosis.

Often crush-cut or crush-avulsion injuries have associated contamination with particulate matter, such as that from machine blades. This may result in infection or an exaggerated inflammatory response if inadequately debrided, either of which can contribute to thrombosis of a re-anastomosed blood vessel. Anatomy of the digit is demonstrated in *Figure 1*.

Associated factors relevant to the mechanism of injury include the presence of thermal or chemical injury, both of which again impact on the success of revascularization and functional outcome.

Assessment

Assessment of patients with amputated parts should follow the principles of Advanced Trauma Life Support (ATLS). It is easy to be distracted by the presence of a separated finger or hand, and patients may have other associated injuries that could indeed take clinical priority (*Figure 2*).

A thorough history of the mechanism of injury, as described above, is warranted. The precise time of the injury should be documented, as should the type of first aid given.

Relevant factors in a patient's history that influence the decision to replant include comorbidities, particularly cardiovascular disease, diabetes, peripheral neu-

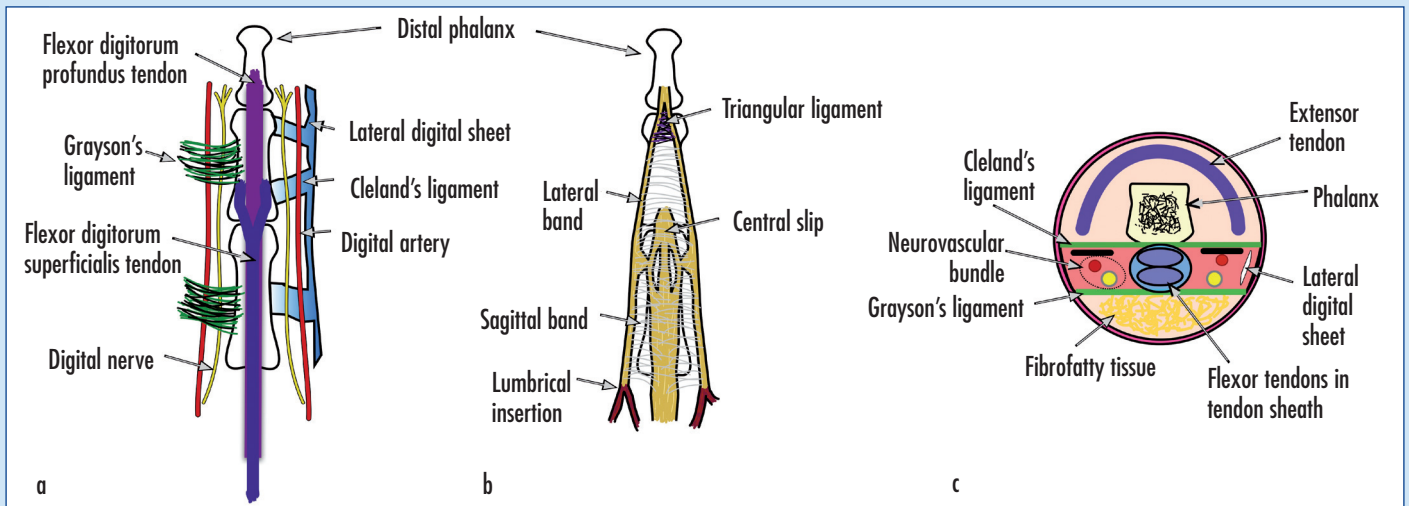


Figure 1. Anatomy of the finger. a. Volar aspect. b. Dorsal aspect. c. Cross section.

ropathy and microangiopathy, medications, smoking status, occupation, hand dominance, and hobbies.

The fasting time is of relevance if an immediate general anaesthetic is planned.

Prophylactic antibiotics and, if necessary, tetanus prophylaxis should be administered.

The level(s) of injury and number of digits involved should be recorded, and photographs of the wound and the amputated part should be taken for the patient's notes.

Radiographs of the wound and the amputated part should be obtained.

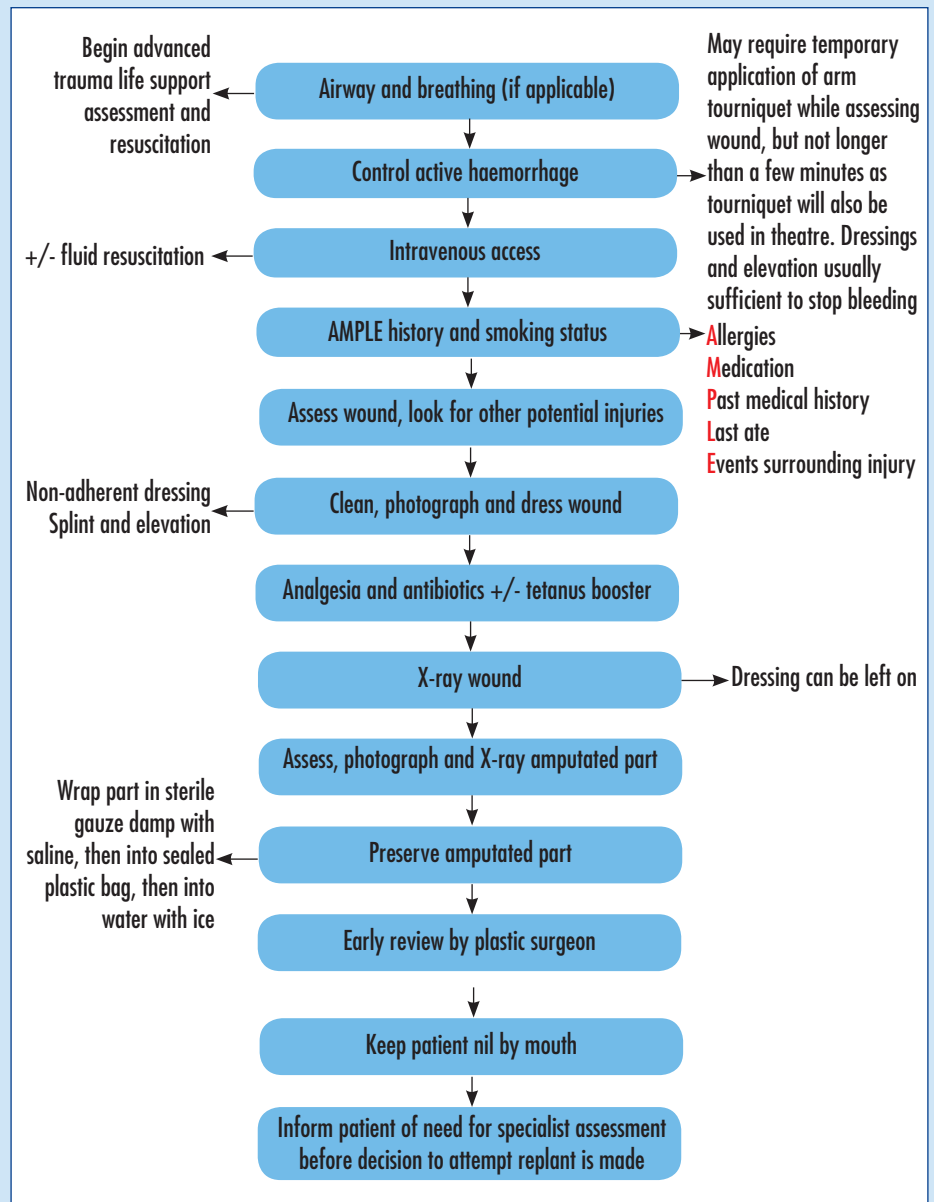
Ischaemia time

A digital replantation should be commenced within 6 hours of warm ischaemia time. Select cases have reported successful replantation after over 20 hours warm ischaemia, but beyond 12 hours replantation is not recommended (Goldner and Urbaniak, 2011).

The sooner an amputated part is replanted, the better the outcomes. However, a digit can, in practice, be stored at 4°C for up to 24 hours and still survive once replanted. A finger does not contain muscle, which is highly sensitive to ischaemia and subsequent reperfusion injury.

More proximal amputations involving the hand, wrist or arm, are different situations because of the presence of muscle. Proximal amputations with warm ischaemia times of greater than 6 hours are not usually recommended for replantation (Goldner and Urbaniak, 2011). The reperfusion injury following a replanted arm can

Figure 2. Flow chart demonstrating a step-by-step approach for managing digital amputations.



result in systemic complications such as renal failure. In addition, the swelling of such muscle following reperfusion can result in compartment syndrome and require fasciotomies to prevent or reduce myonecrosis.

How to store or transport an amputated part

Several methods for storing an amputated part have been described, although all apply common principles of cooling the part without allowing it to freeze or come into direct contact with ice. The authors' preferred method is to loosely wrap the part in sterile gauze soaked in saline, and then place the gauze and part into a sealable plastic bag. The bag is then placed in ice water. If there is a delay to replantation, this container can be left in a refrigerator at 4°C.

An amputated part that comes into direct contact with ice or freezing temperatures can itself freeze, rendering it non-replantable.

The Human Tissue Act 2004 regulates the processing of human tissue in England, Wales and Northern Ireland. It states that it is an offence to remove, store or use human tissue for scheduled purposes without appropriate consent, and to store or use human tissue donated for a scheduled purpose for another purpose. As such, any amputated part that is not salvageable must be disposed of via usual clinical waste disposal methods, i.e. incineration, unless the patient has given specific consent for use under 'scheduled purposes'.

Indications for replantation

The often-quoted indications for digital replantation are summarized in *Table 1*

Table 1. Indications for digital replantation
Thumb
Multiple digits
Partial hand (amputation through the palm)
Any part in a child
Wrist or forearm
Elbow and above elbow
Individual digit distal to the flexor digitorum superficialis tendon

(Goldner and Urbaniak, 2011). However, the decision is usually made on a case-by-case basis taking all of the parameters discussed above into consideration. In particular, the patient must be able to understand the likely functional outcome and possibility of failure, and that he/she will have a long postoperative rehabilitation phase requiring many visits to the hand therapist. Ultimately, the possibility of replantation may not be determined until the state of available blood vessels and nerves has been inspected under magnification.

The importance of stopping smoking cannot be overemphasized – smoking has been shown to occlude the re-anastomosed digital blood vessels and cause the replant to fail (Harris et al, 1980). Electronic cigarettes are not exempt from this guidance as they also contain significant amounts of nicotine that causes vasoconstriction.

Replantation is usually attempted in children because of their excellent healing potential. Technically the procedure may be more challenging because of the size of the anatomy, but outcomes are usually better than in adults. Children have better neuroplasticity so nerve recovery is usually good.

Replantations of distal digital amputations, i.e. those at or distal to the distal interphalangeal joint, are not commonly performed. This is, in part, the result of technical difficulty; usable vessels for anastomosis cannot readily be identified or prepared because of their size or the extent of soft tissue trauma. Digital nerves trifur-

cate into smaller branches around the distal interphalangeal joint, making nerve repair more difficult.

The return of sensation to a repaired digital nerve is usually incomplete, and the degree of recovery varies according to several factors including patient age. In very distal repairs, protective sensation has been reported to return irrespective of whether or not the nerves are repaired (Sebastin and Chung, 2011).

Conversely, the loss of function following terminalisation at the distal interphalangeal joint is relatively low (Sebastin and Chung, 2011). The thumb may be considered an exception to this generalization.

Contraindications to digital replantation are summarized in *Table 2* (Goldner and Urbaniak, 2011).

Composite grafts

A composite graft, i.e. one that constitutes several different tissue types, may be attempted if replantation by microvascular anastomosis is not an option. This usually refers to very distal amputations. As for a skin graft, the composite graft must be able to sustain itself through diffusion of nutrients from the wound bed (serum imbibition) until ingrowth of new blood vessels has occurred. For this reason, a smaller composite graft has a greater chance of survival than a larger one.

As for replantations, speed is of the essence when reattaching amputated parts as composite grafts. The severed part is subject to ischaemia-related injury in the same way (see above).

Good candidates for composite grafting are those without microvascular or systemic disease. Typically, composite grafting is performed in children, in whom a greater healing potential increases the chances of success and justifies the attempt. Parts larger than the distal phalanx are not usually considered for composite grafting, and frequently the parts grafted are much smaller than this.

Ring avulsion injuries

A ring avulsion is a particular type of injury to a finger wearing a ring, with a variable presentation. The ring is forcefully pulled, which can cause a spectrum of injury ranging from bruising through degloving of various amounts of soft tissue to amputation.

Table 2. Contraindications to digital replantation

Severely crushed or mangled parts
Amputations at multiple levels
Amputations distal to the distal interphalangeal joint
Amputations in patients with other serious injuries or diseases
Amputations in patients with severely arteriosclerotic vessels
Amputations with prolonged warm ischaemia time
Amputations in mentally unstable patients
Individual finger amputations in an adult at a level proximal to the flexor digitorum superficialis insertion (particularly in the index or small fingers)

Urbaniak et al (1981) classified ring avulsion injuries as follows:

- Class I – circulation adequate
- Class II – circulation inadequate: vessel repair preserves viability
- Class III – complete degloving or amputation.

If revascularization or replantation is required, complications include failure of replantation, non-union or mal-union of fractures, stiffness and flexion contracture. Affected digits often experience long-term cold intolerance and poor sensibility. Owing to these poor functional results, Urbaniak et al (1981) advocate completion amputation in patients with class III injuries. A more recent study, including digits treated with microsurgical repair, demonstrated a majority of digits with ring avulsion injuries survived regardless of injury class, and average total active motion was ‘adequate’ regardless of class. Pain and sensory recovery was not commented upon (Brooks et al, 2007).

Which digit?

The thumb is often described as providing 50% of hand function, with the interphalangeal joint representing 50% of thumb function. The thumb, therefore, is always considered for replantation (*Table 1*).

The index finger is primarily used for pincer grip and precision prehension. When the index finger is injured, the middle finger can become the sole finger of precision with very good effect (Tamai, 1980). This is often observed in patients with minor injuries to the index finger who immediately ‘bypass’ the index by holding it in extension (White, 1980).

The middle finger is also involved in grip strength, as are the ring and little fingers (and thumb). Loss of the middle or

ring fingers at metacarpophalangeal joint level results in a hand with a gap in the middle, through which small objects may fall such as when receiving change. In these instances a ray amputation – removal of the metacarpal and direct approximation of the adjacent remaining digits – may be a useful solution and gives surprisingly good cosmesis.

Outcomes

Outcomes of replantation are related to the level of amputation, number of digits involved, mechanism of injury, wound contamination, age, warm ischaemia time, comorbidities, associated injuries, patient psychological wellbeing, mental health, and compliance with physiotherapy regimen.

A systematic review of outcomes of distal digital replantations demonstrated 1935 of 2273 digits (85%) were fully viable, with a mean two-point discrimination of 7 mm across 220 digits. There was no significant difference in survival between zone I and zone II (Tamai classification) replantations (Sebastin and Chung, 2011). Nail deformity was identified in 23% of cases, and finger pulp atrophy noted in 14%. More proximal amputations have variously been reported to have an 80–90% viability success rate (Sebastin and Chung, 2011).

Dressings

Usually the patient with the devitalized or amputated part will be taken to the operating theatre swiftly. A temporary dressing that keeps the wound covered and reduces pain is advised. Non-adherent wound contact layers such as soft silicone (e.g. Mepitel, Mölnlycke Health Care, Bedfordshire), covered by absorbent gauze, reduce further trauma to the affected area when they are later removed. A resting splint may be

applied if movement of an incompletely severed part causes pain.

Postoperative care and expectations

In the immediate postoperative period the amputated part is observed very closely for signs of perfusion problems. A warm, well-hydrated and pain-free patient is the ideal postoperative state. Tight dressings are avoided. There should be a low threshold for returning to theatre to explore or revise the anastomosis. If there is venous congestion, leech therapy may be considered, particularly if there was difficulty identifying adequate veins for repair intraoperatively.

Amputations with or without replantation can result in the formation of a painful neuroma at the divided end of a sensory nerve. Some patients develop chronic pain that may or may not be caused by neuroma, and may be very difficult to treat.

A repaired sensory nerve will usually leave a degree of reduced sensation or numbness in the affected distribution.

There may be cold intolerance following nerve injury, which some patients say improves over a period of around 2 years.

Usually there is some degree of residual stiffness of a replanted part. If this is severe, adhesions between the tendons and surrounding tissues or joint contractures secondary to immobility could be the cause, and further surgery may be indicated. **BJHM**

Conflict of interest: none.

- Brooks D, Buntic RF, Kind GM, Schott K, Buncke GM, Buncke HJ (2007) Ring Avulsion: Injury Pattern, Treatment, and Outcome. *Clin Plastic Surg* **34**: 187–95
- Dec W (2006) A meta-analysis of success rates for digital replantation. *Tech Hand Up Extrem Surg* **10**: 124–9
- Goldner RD, Urbaniak JR (2011) Replantation. In: Wolfe SW, Hotchkiss RN, Pederson WC, Kozin SH, eds. *Green's Operative Hand Surgery*. 6th edn. Churchill Livingstone, Philadelphia, PA: 1585–601
- Harris GD, Finseth F, Buncke HJ (1980) The Hazard of Cigarette Smoking following digital replantation. *J Microsurgery* **1**: 403–4
- Sebastin SJ, Chung KC (2011) A systematic review of the outcomes of replantation of distal digital amputation. *Plast Reconstr Surg* **128**(3): 723–37
- Tamai S (1980) Treatment of amputated hand and fingers. *Orthopaedic Surgery MOOK* **15**: 159–71
- Urbaniak JR, Evans JP, Bright DS (1981) Microvascular management of ring avulsion injuries. *J Hand Surg (Am)* **6**: 25–30
- White WL (1980) Why I Hate the Index Finger. *Orthopaedic Review* **9**(6): 23–9

KEY POINTS

- A full patient assessment and primary survey is needed – other associated injuries or illnesses that may be equally important can easily be overlooked.
- Manage patient expectations early – explain that the possibility of replantation may only be determined once the part and the wound have been inspected in the operating theatre. A replanted digit is never as good as an uninjured digit.
- Proper storage of the amputated part can mean the difference between a replantation being possible or not.