

CORE TRAINING FOR DOCTORS

CLINICAL SKILLS FOR POSTGRADUATE EXAMINATIONS

Pallor **C146**

Oliver Cohen, Duncan Brian, Pauline Leonard

WHAT YOU NEED TO KNOW ABOUT

Management of acute pulmonary embolism **C150**

*Rehan Quadery, Charlie A Elliot, Judith
Hurdman, David G Kiely, Rhona M Maclean,
Ian Sabroe, Joost J van Veen, Robin Condliffe*

TIPS FROM THE SHOP FLOOR

Duration of anticoagulation: the decision-making process **C156**

Rachael Thompson, Jecko Thachil

COMING NEXT MONTH

WHAT YOU NEED TO KNOW ABOUT

Cutaneous lupus erythematosus

CLINICAL SKILLS FOR POSTGRADUATE EXAMINATIONS

The Koebner phenomenon

WHAT YOU NEED TO KNOW ABOUT

Cutaneous drug rashes

CLINICAL SKILLS FOR POSTGRADUATE EXAMINATIONS

Pyoderma gangrenosum

Edited by **Dr Daniel JB Marks**, Clinical
Pharmacologist, University College London
and **Dr Jacob de Wolff**, Consultant Acute Physician,
London North West Healthcare NHS Trust, Middlesex

Pallor

Introduction

Pallor is a common examination finding in clinical practice and often features in post-graduate examinations associated with pathology originating from a variety of body systems. It is routinely assessed in the cardiovascular, respiratory and abdominal examinations as a means to detect anaemia clinically.

Pathophysiology

Pallor can be detected at a number of body sites including the palmar creases and nail bed but is most commonly examined for by observation of the palpebral conjunctiva. Ethnicity may impact the site of assessment as only pallor of the nail beds, palms and conjunctivae can be used to assess patients of any race (Sheth et al, 1997). This article will focus predominantly on conjunctival pallor as it is the most common method used to detect pallor in the MRCP PACES examinations and in clinical practice in the UK.

At the palpebral conjunctiva, the stratum corneum or outermost layer of the epidermis is thinnest thus maximizing the visualization of the red colour of arterial blood (Figure 1). If the haemoglobin concentration is reduced, the red colour may also diminish leading to pallor (Figure 2) (Epstein et al, 2008).

How to examine

In order to examine for conjunctival pallor, ensure that the environment is well lit and the patient is comfortable. Gently evert the lower lid of one eye to reveal the palpebral conjunctiva and ask the patient to look upwards. Some clinicians ask the patient to perform this manoeuvre him-/herself to

Dr Oliver Cohen is Haematology
Specialist Registrar and **Dr Duncan Brian**
is Haematology Specialist Registrar in the
Department of Haematology, University
College Hospital, London NW1 2BU, and
Dr Pauline Leonard is Consultant Medical
Oncologist in the Department of Oncology,
Whittington Hospital NHS Trust, London

Correspondence to: *Dr O Cohen*
(olivercohen@hotmail.co.uk)

minimize discomfort. Inspection should reveal an obviously red palpebral conjunctiva. In an anaemic patient, the palpebral conjunctiva will be pale pink in colour. Colour scales exist to aid the clinician in their diagnosis of conjunctival pallor (Chowdhury et al, 2002), although these are not widely used in the UK.

Reliability

Several studies have evaluated the reliability of pallor in the diagnosis of anaemia (e.g. Wallace et al, 2000; Chowdhury et al, 2002). Wallace et al (2000) focused exclusively on the detection of anaemia by examination of the palpebral conjunctiva, revealing overall accuracy of 61–69% with sensitivities varying between 52 and 65% and specificities between 62 and 83%. Chowdhury et al (2002) demonstrated that the use of colour scales and allowing the clinician to take a medical history both independently improved the sensitivity and specificity for the detection of anaemia when compared to clinical assessment alone. This study required participants to examine for pallor at nine anatomical sites including the palpebral conjunctiva as part of their clinical assessment.

In the assessment of conjunctival pallor, diagnostic accuracy increases with lower haemoglobin concentrations (Wallace et al, 2000). In practice, substantial inter-observer variability exists (Gjørup et al, 1986), which makes formulation of accurate predictive values difficult. A number of studies showed the palpebral conjunctiva to be a more sensitive method to detect pallor than examination of other sites (e.g. Nardone et al, 1990; Spinelli et al, 2003). In contrast, Kalantri et al (2010) posit that tongue pallor has a higher likelihood ratio than other pallor sites for detecting anaemia clinically.

There is mixed evidence on the influence of specialization and experience on the detection of pallor. Wallace et al (2000) investigated whether ophthalmologists who saw conjunctivae on a continual basis would be better than general surgeons in their assessment of conjunctival pallor. The study found no difference between ophthalmologists and general

surgeons nor between registrars and consultants in these specialties in their ability to detect anaemia clinically. In contrast, Yurdakok et al (2008) found that trained paediatricians were better at detecting palmar pallor in children than more junior paediatric residents.

Cause

In the setting of postgraduate examinations, it is likely that conjunctival pallor will be reflective of anaemia. *Table 1* sets out common causes of anaemia. It should be noted that there is some overlap between categories such as in the case of anaemia of chronic disease, which is usually normocytic but may become microcytic, with or

without coexisting iron deficiency. Additionally, haemolytic anaemia may be normocytic or macrocytic as a consequence of reticulocytosis. In women of childbearing age, menstrual bleeding is the commonest cause of iron deficiency.

Completing the examination

In order to complete the examination, consider the differential diagnosis of anaemia in the setting of the clinical examination being conducted. Although pallor may result non-specifically from vasoconstriction from any cause such as hypothermia or active bleeding with shock, in the exam setting these are highly unlikely. The presence or absence of pallor is a key finding or

relevant negative and should thus be mentioned when presenting your findings in the PACES examination.

Conjunctival pallor may be detected through routine examination during the cardiovascular, respiratory and abdominal stations and should be assessed in limited scenarios within the neurological examination. In the context of peripheral neuropathy, anaemia may occur as a result of vitamin B₁₂ deficiency, alcohol excess and paraneoplastic syndromes. It may also be of direct relevance to the presenting complaint in station 5. Autoimmune disorders and the drugs used to treat them can both result in anaemia.

Furthermore, it is important to examine for other clinical signs associated with anaemia. These may include koilonychia (spoon-shaped nails), glossitis (inflammation of the dorsal surface of the tongue) and cheilitis (inflammation of the lips) in the context of iron deficiency. Cachexia may imply underlying malignancy or chronic disease while the presence of jaundice may suggest chronic liver disease or haemolysis. Surgical scars on the abdomen may indicate previous gastrointestinal surgery, such as for Crohn's disease, which may lead to anaemia as a result of a combi-

Figure 1. Normal conjunctiva.

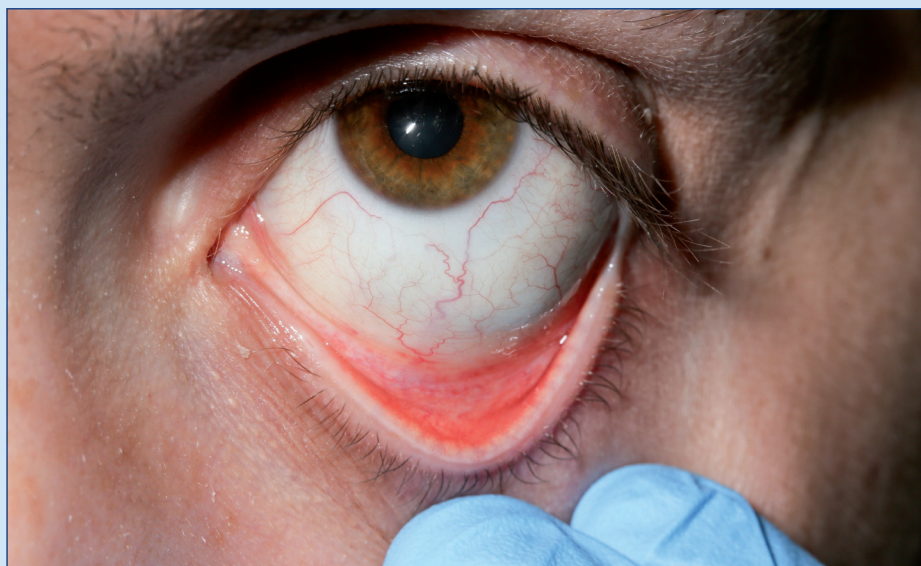

Figure 2. Conjunctival pallor.

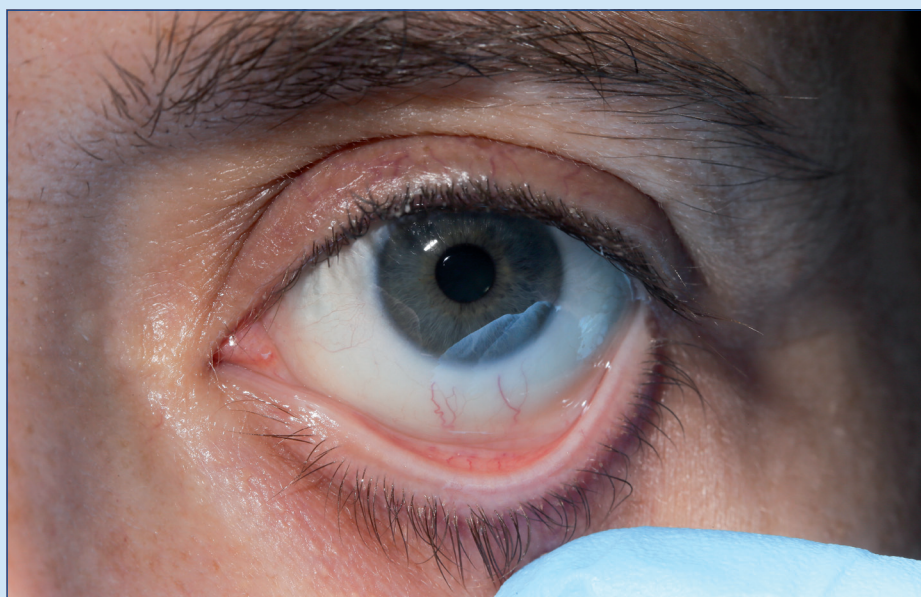


Table 1. Common causes of anaemia by mean cell volume

	Causes
Microcytic anaemia	Iron deficiency Haemoglobinopathy (e.g. thalassaemia)
Normocytic anaemia	Anaemia of chronic disease Acute blood loss Bone marrow failure or infiltration Haemolytic anaemia Chronic kidney disease
Macrocytic anaemia	Vitamin B ₁₂ deficiency Folate deficiency Alcohol excess Liver disease Myelodysplasia Reticulocytosis Pregnancy Hypothyroidism

nation of iron, folate and sometimes vitamin B₁₂ deficiency, as well as as a result of chronic inflammation and bleeding. A detailed list is presented in *Table 2*.

Investigation and management

When presenting in the PACES examination, one can divide investigations into blood tests, imaging and specialist investigations. Investigations will be dictated by clinical assessment including past medical history, drug and social history including diet and recent travel. In the history, be sure to ask the patient about symptoms of anaemia.

Blood tests

It is difficult to predict the degree of anaemia accurately from clinical examination

alone, thus the finding of conjunctival pallor should always prompt a full blood count to confirm suspicions. This provides information including the mean cell volume, which can guide the differential and thus the investigations performed. Additionally, the full blood count will confirm whether the anaemia is an isolated abnormality or part of a bicytopenia or pancytopenia such as in myelodysplasia.

Given the many differential causes of anaemia, further tests will depend on clinical suspicion. In a patient with macrocytic anaemia and symptoms suggestive of malabsorption, vitamin B₁₂ and folate levels would be imperative. In contrast, these investigations may not be relevant in a patient with microcytic anaemia and a history consistent with a possible malignancy.

Biochemical tests might include creatinine in addition to haematinics if renal failure is considered, while liver function tests and/or unconjugated bilirubin, lactate dehydrogenase and haptoglobin may be indicated with investigating suspected haemolytic anaemia. A blood film may be useful if the cause of haemolysis is unclear, when making a diagnosis of haemoglobinopathy and to confirm extreme results. Full details of the tests required in the investigation of anaemia go beyond the scope of this article but for further information on the subject, readers are referred to 'Investigating anaemia' (Tilyard and Harris, 2013).

Imaging and specialist tests

Imaging depends on the history and associated clinical findings, e.g. echocardiogra-

Table 2. Potential cases in the PACES examination, their association with anaemia and how to complete the examination if you suspect them

Cardiovascular	Diagnosis	Association with anaemia	How to elicit
	Aortic stenosis	Heyde's syndrome whereby severe aortic stenosis is associated with colonic angiodysplasia leading to gastrointestinal blood loss	As part of the cardiovascular examination and elicited in the history. Ask about blood loss if part of station 5
	Prosthetic heart valves	Regurgitation of blood is associated with mechanical trauma to red blood cells leading to haemolysis (Maraj et al, 1998). Use of antiplatelet and anticoagulant medications are associated with bleeding	Examine for scleral icterus suggestive of haemolysis. Examine for ecchymoses if the patient is taking antiplatelet or anticoagulant therapy
Respiratory	Interstitial lung disease, bronchiectasis, COPD, lung malignancy	Many inflammatory lung conditions are associated with anaemia of chronic disease	As part of the respiratory examination
	Pneumonia	Autoimmune haemolytic anaemia may complicate mycoplasma infection	As part of the respiratory examination. Inspect for scleral icterus suggestive of haemolysis
	Hereditary haemorrhagic telangiectasia	Autosomal dominant condition leading to abnormal blood vessel formation and predisposition to mucosal bleeding and vascular malformations in the lungs, liver and brain	Elicited in the history including past bleeding and family history. On examination, inspect for oral telangiectasia
Abdominal	Chronic liver disease	Portal hypertension resulting in bleeding varices and/or splenomegaly, chronic inflammation and/or nutritional deficiency leading to ineffective erythropoiesis and low platelets leading to bleeding	As part of the abdominal examination. In the history, ask specifically about alcohol intake and other causes of chronic liver disease. Examine specifically for petechiae suggestive of thrombocytopenia
	Chronic kidney disease	Inadequate production of or replacement of erythropoietin, iron deficiency and/or ineffective erythropoiesis, increased bleeding tendency	Elicited in the history. Ask specifically about treatments such as exogenous erythropoietin
	Splenomegaly	May be caused by extramedullary haematopoiesis, e.g. thalassaemia, or sequestration of red cells, e.g. in haemolytic anaemia. May be caused by infiltration by a myeloproliferative neoplasm, e.g. myelofibrosis, or a lymphoid malignancy	As part of the abdominal examination. In the history ask about abdominal pain and early satiety, and blood transfusions. Thalassaemia is elicited in the family history. Be sure to examine for cervical, axillary and groin lymph nodes, which may be enlarged in lymphoid malignancy or infection
	Inflammatory bowel disease	Coeliac disease and Crohn's disease can result in mixed haematinic deficiencies. Ulcerative colitis may cause iron deficiency anaemia and/or an anaemia of chronic inflammation	Elicited in the history including any previous surgery potentially leading to short gut syndrome or other nutrient or other nutrient deficiency

COPD = chronic obstructive pulmonary disease

phy in the context of suspected valvular dysfunction or abdominal ultrasound in the setting of associated splenomegaly. Both upper and lower gastrointestinal investigation should be conducted in male and post-menopausal female patients with confirmed iron deficiency anaemia unless a history of significant overt non-gastrointestinal blood loss exists. Only the finding of malignancy or coeliac disease on oesophagogastroduodenoscopy should deter lower gastrointestinal investigation (Goddard et al, 2011).

Coeliac disease can be excluded before oesophagogastroduodenoscopy using serology for anti-tissue transglutaminase (tTG) antibodies, or by D2 biopsies performed during oesophagogastroduodenoscopy if clinical suspicion remains high despite a negative tTG assay. Bone marrow biopsy may be considered in cases where bone marrow failure or infiltration is suspected.

Specific management of underlying anaemia is cause dependent. Red cell transfusion is according to locally agreed transfusion triggers, given on a restrictive basis.

Conclusions

Pallor is a frequently identified sign in clinical examination, which should be interpreted in the context of the history and clinical examination being conducted. Following detection, the presence or absence of associated features and clinical evidence of an underlying aetiology of anaemia should be ascertained. The

absence of pallor may be a relevant negative to highlight to the examiner. Investigation and management will be guided by likely cause. **BJHM**

Conflict of interest: none.

- Chowdhury MK, Chongsuvivatwong V, Geater AF, Akhter HH, Winn T (2002) Taking a medical history and using a colour scale during clinical examination of pallor improves detection of anaemia. *Trop Med Int Health* 7(2): 133–9 (doi: 10.1046/j.1365-3156.2002.00837.x)
- Epstein O, Perkin GD, Cookson J et al (2008) *Clinical Examination*. 4th edn. Elsevier, London
- Goddard AF, James MW, McIntyre AS, Scott BB (on behalf of the British Society of Gastroenterology) (2011) Guidelines for the management of iron deficiency anaemia. *Gut* 60: 1309–16 (doi: 10.1136/gut.2010.228874)
- Gjørup T, Bugge PM, Hendriksen C, Jensen AM (1986) A critical evaluation of the clinical diagnosis of anaemia. *Am J Epidemiol* 124(4): 657–65
- Kalantri A, Karambelkar M, Joshi R, Kalantri S, Jajoo U (2010) Accuracy and reliability of pallor for detecting anaemia: a hospital-based diagnostic accuracy study. *PLoS ONE* 5(1): e8545 (doi: 10.1371/journal.pone.0008545)

- Maraj R, Jacobs LE, Ioli A, Kotler MN (1998) Evaluation of haemolysis in patients with prosthetic heart valves. *Clin Cardiol* 21(6): 387–92 (doi: 10.1002/clc.4960210604)
- Nardone DA, Roth KM, Mazur DJ, McAfee JH (1990) Usefulness of physical examination in detecting the presence or absence of anaemia. *Arch Intern Med* 150(1): 201–4 (doi: 10.1002/clc.4960210604)
- Sheth TN, Choudhry NK, Bowes M, Detsky AS (1997) The relation of conjunctival pallor to the presence of anaemia. *J Gen Intern Med* 12: 102–6 (doi: 10.1046/j.1525-1497.1997.00014.x)
- Spinelli MG, Souza JM, Souza SB, Sesoko EH (2003) Reliability and validity of palmar and conjunctival pallor for anaemia detection purposes. *Rev Saude Publica* 37(4): 404–8 (doi: 10.1590/S0034-89102003000400003)
- Tilyard M, Harris R, eds (2013) *Investigating Anaemia*. Best Tests, Tilyard Auckland, New Zealand
- Wallace DE, McGreal GT, O'Toole G et al (2000) The influence of experience and specialisation on the reliability of a common clinical sign. *Ann R Coll Surg Engl* 82: 336–8
- Yurdakok K, Guner SN, Songul Yalcin S (2008) Validity of using pallor to detect children with mild anaemia. *Pediatr Int* 50: 232–4 (doi: 10.1111/j.1442-200X.2008.02565.x)

KEY POINTS

- Pallor is a common examination finding in both clinical practice and postgraduate examinations.
- Pallor is suggestive of underlying anaemia and should be evaluated in the context of the patient history and associated examination findings.
- Pallor is most commonly identified by inspection of the palpebral conjunctiva as opposed to examination of other anatomical sites.
- Conjunctival pallor is easiest to detect at lower haemoglobin concentrations.
- Pallor may be a relevant finding in any of the clinical examinations assessed in PACES.
- There is a wide differential diagnosis of anaemia, which requires a detailed history and examination in order to guide investigation.

Organised by

BRITISH JOURNAL OF
**HOSPITAL
MEDICINE**

Journal of
**PARAMEDIC
PRACTICE**

8th National Conference

Updates in Emergency Medicine

Kensington Close Hotel, London 10th & 11th March 2016

For further information about this or any of our other events please visit our website

For more information:  Call us on +44(0)20 7501 6762
 www.mahealthcarevents.co.uk/emergencymedicine2016

CPD
CERTIFIED
The CPD Certification Service

DISCOUNTED RATE
AVAILABLE UNTIL 3RD
DECEMBER 2015