

Retrobulbar haemorrhage: improved visual acuity after delayed surgical decompression

Introduction

Acute retrobulbar haemorrhage is a rare and sight-threatening emergency. Current best practice involves immediate surgical decompression complemented by medical management within 2 hours of injury. This article presents the case of a woman suffering from complete loss of vision to the left eye as a result of left-sided retrobulbar haemorrhage secondary to blunt orbital trauma. Late presentation meant that the patient only underwent emergency treatment 14 hours after injury. Despite this, visual acuity of the affected eye improved, and therefore the use of emergency treatments is advocated in these cases even at a late stage.

Discussion

Retrobulbar haemorrhage is a sight-threatening emergency requiring urgent treatment. Although it can occur spontaneously, it is most commonly caused by surgery to the orbital walls, needles inserted into the retrobulbar space or blunt orbital trauma (Winterton et al, 2007). The mechanism of injury is increasing pressure in the region; the expanding haematoma either compresses the optic nerve and its surrounding vasculature, or the central retinal artery that runs within it.

It is vital that the key features of reduced visual acuity, pain, proptosis, ophthalmop-

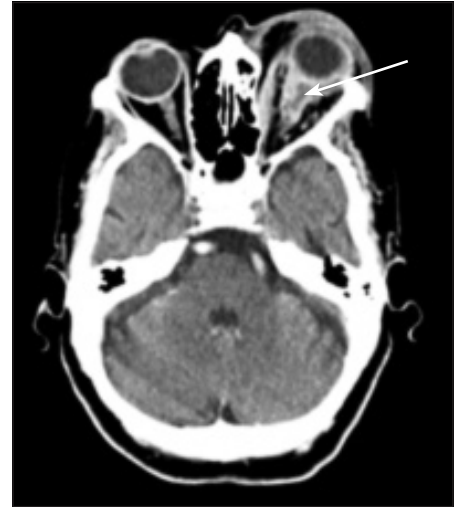plegia, relative afferent pupillary defect and a pale optic disc (Perry, 2008) are detected early, as the optic nerve can sustain only 90–120 minutes of ischaemia before irreversible visual loss is detectable. Alongside a compatible clinical history, this combination of symptoms and signs is pathognomic of retrobulbar haemorrhage, helping to quickly differentiate it from other causes of acute ophthalmoplegia, such as cranial nerve palsies. If treatment is commenced within 2 hours, full return of visual acuity may be seen (Hislop et al, 1996; Winterton et al, 2007). However, the condition is sufficiently uncommon that many emergency department staff lack confidence in this respect; Hislop et al (1996) found that over 80% of senior house officers in their emergency department were not confident about diagnosing and treating this condition.

Retrobulbar haemorrhage is considered a clinical diagnosis, and treatment should not be delayed by investigations. Computed tomography demonstrates anatomical disruption, but functional impairment, indicated by decreased visual acuity and relative afferent pupillary defect, is the most important prognostic factor (Chen et al, 2012). Such impairment supports the initiation of treatment before further investigations and correlates with damage

to the optic nerve or macula. However, a question mark has been raised over the objectivity of clinical examination alone, suggesting a need for quantitative methods of functional assessment and tissue perfusion such as visual evoked potentials and portable tonometry (Perry, 2008). The practicality of any such investigations must be considered against time spent in the emergency department.

At present, best management is immediate surgical decompression with lateral canthotomy and inferior cantholysis (out-

Figure 1. Retrobulbar haemorrhage extending into the optic nerve sheath of the left orbit (arrow).



Mr VS Sarma is Dental Student in the School of Dental Sciences, Newcastle University, Newcastle upon Tyne NE2 4BW, **Dr M Howlader** is GP Specialty Trainee in the Postgraduate School of Primary Care, Northern Deanery, Newcastle upon Tyne, **Mr MA Nusrath** is Consultant in the Department of Oral and Maxillofacial Surgery, Nottingham University Hospitals NHS Trust, Nottingham and **Mr DJ Keith** is Consultant in the Department of Oral and Maxillofacial Surgery, Sunderland Royal Hospital, Sunderland

Correspondence to: Mr VS Sarma
(v.s.sarma1@ncl.ac.uk)

Case Report

An 80-year-old woman presented to accident and emergency with swelling and complete loss of vision to her left eye for 6 hours, after having fallen downstairs. Her medical history included mild dementia, but she was otherwise fit and well. On examination, the globe was tense, painful and markedly proptosed with a dilated, unreactive pupil, and extraocular movements were almost completely restricted in all directions.

Computed tomography confirmed prominent haematomas both within the left optic nerve sheath and inferomedial to it (Figure 1), but because of the delayed presentation both the ophthalmic and maxillofacial teams felt that the prognosis was poor, and that the risk of surgical complications outweighed the potential benefits. As such, emergency medical treatment alone was commenced with mannitol, acetazolamide, intravenous corticosteroids and a proton-pump inhibitor to protect against gastrointestinal ulceration. When it was seen that medical management had failed by the morning, the trauma team reassessed the patient and decided that, although the likelihood of visual improvement was very low, surgery now represented the only option for treatment. As a result, lateral canthotomy and inferior cantholysis were performed at this time, 14 hours post-injury. Visual acuity improved, and was recorded as 6/18 within 3 months. Extraocular muscle movements and afferent pupillary defect returned to normal.

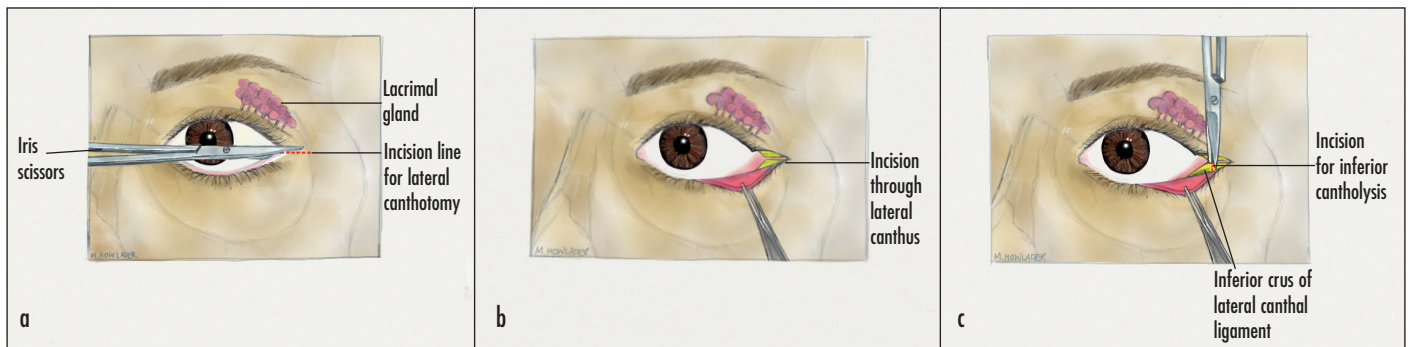


Figure 2. Steps involved in lateral canthotomy and inferior cantholysis following local anaesthetic infiltration. **a.** Incision line (compress with artery forceps before incision to reduce swelling and bleeding). **b.** Lateral canthotomy. **c.** Inferior cantholysis. Complications are rare, although superior cantholysis should be avoided if possible, as this may result in damage to the lacrimal apparatus.

lined in Figure 2), followed by medical management with a hyperosmotic agent (e.g. mannitol), a carbonic-anhydrase inhibitor (e.g. acetazolamide), high-dose intravenous corticosteroids (e.g. hydrocortisone or dexamethasone) and eye drops to decrease the production of aqueous humour (e.g. timolol maleate) within 2 hours of injury (Winterton et al, 2007; Chen et al, 2012; Colletti et al, 2012).

Conclusions

Although it is widely accepted that best management of retrobulbar haemorrhage involves treatment within 2 hours of injury, this patient demonstrated an improvement in visual acuity despite treatment being delayed until 14 hours post-injury because complete loss of vision for 6 hours in the context of retrobulbar haemorrhage was thought to render the eye unsalvageable.

The authors would therefore support the use of emergency treatments for retrobulbar haemorrhage even at a late stage. **BJHM**

Chen Y, Singhal D, Chen Y, Chen C (2012) Management of acute traumatic retrobulbar haematomas: A 10-year retrospective review. *J Plast Reconstr Aesthet Surg* **65**: 1325–30 (doi: 10.1016/j.bjps.2012.04.037)

Colletti G, Valassina D, Rabbiosi D et al (2012) Traumatic and iatrogenic retrobulbar hemorrhage: an 8-patient series. *J Oral Maxillofac Surg* **70**: e464–8 (doi: 10.1016/j.joms.2012.05.007)

Hislop WS, Dutton GN, Douglas PS (1996) Treatment of retrobulbar haemorrhage in accident

and emergency departments. *Br J Oral Maxillofac Surg* **34**(4): 289–92 (doi: 10.1016/S0266-4356(96)90004-2)

Perry M (2008) Acute proptosis in trauma: retrobulbar haemorrhage or orbital compartment syndrome – does it really matter? *J Oral Maxillofac Surg* **66**(9): 1913–20 (doi: 10.1016/j.joms.2008.04.012)

Vassallo S, Hartstein M, Howard D, Stetz J (2002) Traumatic retrobulbar haemorrhage: emergent decompression by lateral canthotomy and cantholysis. *J Emerg Med* **22**(3): 251–6 (doi: 10.1016/S0736-4679(01)00477-2)

Winterton JV, Patel K, Mizen K (2007) Review of management options for a retrobulbar haemorrhage. *J Oral Maxillofac Surg* **65**(2): 296–9 (doi: 10.1016/j.joms.2005.11.089)

LEARNING POINTS

- Retrobulbar haemorrhage is a sight-threatening emergency that requires urgent diagnosis and treatment.
- Optimal management is immediate surgical decompression followed by medical management.
- Management should ideally be instituted within 2 hours of symptoms.
- Delayed presentation should not preclude treatment as improved visual function may still be seen.

Optrafair is the UK's leading exhibition and educational conference dedicated to the needs of the optical profession since 1978.

Valued by a community of practitioners, suppliers and educators to help expand knowledge, grow awareness of products and services, gain CET points and build business.

Register and book your education now at OPTRAFAIR.CO.UK