

by either upper gastrointestinal imaging endoscopy or contrast-enhanced upper gastrointestinal imaging should be performed to confirm the diagnosis and rule out alternative causes of duodenal obstruction (Bajardi et al, 2009).

Interestingly this patient did not complain of typical symptoms of small bowel obstruction and was investigated for upper gastrointestinal bleeding. This case demonstrates an unusual cause of a relatively common condition – doctors should be aware of this rare presentation of abdominal aortic aneurysm. **BJHM**

Bajardi G, Pecoraro F, Mirabella D, Bellisi MG

(2009) Inflammatory abdominal aortic aneurysm (IAAA). *Ann Ital Chir* **80**: 171–6  
 Cahill K, Roche-Nagle G, MacEaney P, McGreal GI (2009) Upper gastrointestinal obstruction secondary to aortoduodenal syndrome owing to a noninflammatory abdominal aortic aneurysm. *Vascular* **17**: 168–71  
 Crawford JL, Stowe CL, Safi HJ, Hallman CH, Crawford ES (1985) Inflammatory aneurysms of the aorta. *J Vasc Surg* **2**: 113–24

Gans RO, Hoorntje SJ, Rauwerda JA, Luth WJ, van Hattum LA, Donker AJ (1993) The inflammatory abdominal aortic aneurysm. Prevalence, clinical features and diagnostic evaluation. *Neth J Med* **43**: 105–15  
 Osler W (1905) Aneurysm of the abdominal aorta. *Lancet* **ii**: 1089–905  
 Walker DI, Bloor K, Williams G, Gillie I (1972) Inflammatory aneurysms of the abdominal aorta. *Br J Surg* **59**: 609–14

## LEARNING POINTS

- Inflammatory aortic aneurysms are uncommon.
- This case highlights an unusual presentation with small bowel obstruction that was initially misdiagnosed as an upper gastrointestinal bleed.
- Early diagnosis with contrast imaging is key to treatment.

## IMAGES IN MEDICINE

# A 'chunky' pulmonary angiogram

**A** 42-year-old man presented to the emergency department with shortness of breath and mild chest pain following a syncopal episode earlier that morning.

On examination a loud systolic murmur throughout the precordium but no radiation to carotids was noted. Bloods showed a troponin level of <20 ng/ml (normal) and a D dimer level of 1.32 ng/ml (elevated). A provisional diagnosis of cardiac syncope as a result of symptomatic aortic stenosis was made with a need to exclude pulmonary embolus. A 12-lead electrocardiogram showed inferolateral T-wave inversion, a biphasic T wave in V1, with no left ventricular hypertrophy by voltage criteria. A

computed tomography pulmonary angiogram (Figures 1a and b) showed no pulmonary embolism but interventricular septum thickness of 27 mm with posterolateral wall up to 19 mm. The left ventricular wall was thickened but not dilated, consistent with hypertrophic cardiomyopathy.

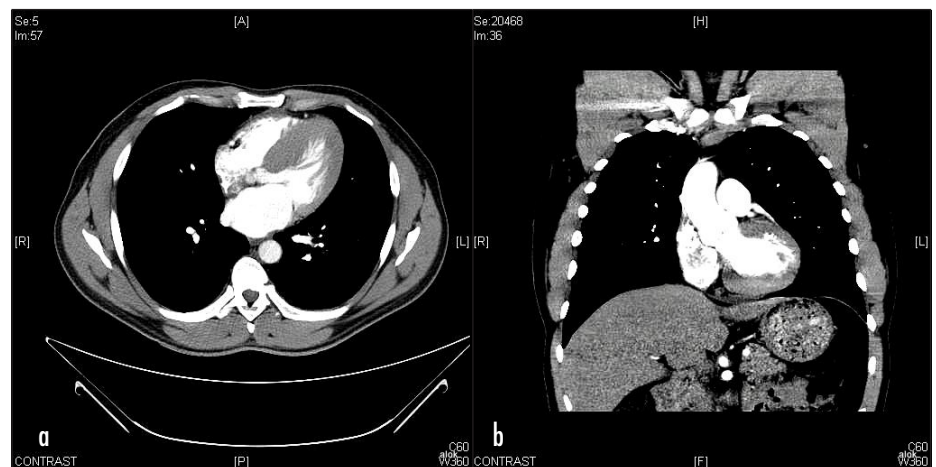
Transthoracic echocardiogram showed interventricular septum hypertrophy of 2.3 cm with dynamic left ventricular systolic function and impaired left ventricular diastolic function. Left ventricular outflow tract gradient was 41 mmHg at rest increasing to 71 mmHg with valsalva indicating

dynamic outflow tract gradient confirming hypertrophic obstructive cardiomyopathy.

The computed tomography pulmonary angiogram is increasingly used to detect pulmonary embolism in patients with unexplained breathlessness or chest pain. Clinically useful data about the heart are often produced which can give important clues to the cause of presenting symptoms and signs (McKie et al, 2005). **BJHM**

McKie SJ, Hardwick DJ, Reid JH, Murchison JT (2005) Features of cardiac disease demonstrated on CT pulmonary angiography. *Clin Radiol* **60**: 31–8

**Figure 1. a. Computed tomography pulmonary angiogram showing thickened cardiac interventricular septum and posterolateral wall suggestive of hypertrophic cardiomyopathy. b. Left ventricle is thickened but not dilated, suggesting hypertrophic cardiomyopathy.**



**Dr Alok Arora** is Registrar in Acute Medicine in the Department of Acute Medicine, Bristol Royal Infirmary, Bristol, **Dr Shiva Sreenivasan** is Consultant in the Department of Medicine, South West Acute Hospital, Western HSC Trust, Enniskillen, Northern Ireland, and **Dr Surojit Bose** is Cardiology Registrar in the Department of Cardiology, Bristol Royal Infirmary, North Bristol Hospitals NHS Trust, Bristol

Correspondence to: Dr A Arora, Resident, Department of Internal Medicine, Weiss Memorial Hospital, Chicago, 60640 Illinois, USA (alokjarora@hotmail.com)