

# CORE TRAINING FOR DOCTORS

## WHAT THEY DON'T TEACH YOU AT MEDICAL SCHOOL

**What is histopathology  
and how to get the most out of  
your histopathologist** **C66**

*Ian E Proctor*

**WHAT YOU NEED TO KNOW ABOUT  
Histopathology: improving  
outcomes in bowel cancer** **C69**

*Timothy G Palmer, Nicholas P West*

**The molecular approach  
to diagnosis in lung cancer** **C74**

*David A Moore, John PC Le Quesne*

## CLINICAL SKILLS FOR POSTGRADUATE EXAMINATIONS

**The hospital postmortem:  
time for a revival** **C77**

*Laura Casey, Alison Winstanley*

## COMING NEXT MONTH

### TIPS FROM THE SHOP FLOOR

**Paraproteinaemia**

### WHAT YOU NEED TO KNOW ABOUT

**Screening for lung cancer**

### WHAT THEY DON'T TEACH YOU AT MEDICAL SCHOOL

**Dealing with encounters being  
recorded by patients**

### CLINICAL SKILLS FOR POSTGRADUATE EXAMINATIONS

**Pyoderma gangrenosum**

Edited by **Dr Daniel JB Marks**, Academic Clinical Fellow in Translational Medicine, University College London and **Dr Jacob de Wolff**, Consultant Acute Physician, North West London Hospitals NHS Trust, Middlesex

# What is histopathology and how to get the most out of your histopathologist

**A**s a medical student you get the opportunity to experience life on the wards, hold a retractor in theatre, stitch people up in accident and emergency and learn how to prescribe drugs in general practice. However, very few medical students and junior doctors are able to experience the fascinating world of histopathology. The closest they usually come is attending an occasional postmortem in the hospital basement or listening to a shadowy figure at the back of a multidisciplinary team meeting talking about 'tumour stage and resection margins'.

This article explains what histopathology is, decodes some of the terminology and discusses how you can get the most out of your local histopathologist.

## 'Histo... what'

Histopathology is the branch of pathology (the study of 'suffering') that deals with tissues ('histo'). This means that histopathologists receive everything from whole bodies, organ resections, biopsies and body fluids – the later separately termed 'cytopathology'. The role of the histopathologist or cytopathologist is to study these tissues and cells and determine whether they contain any pathological features. So while a patient may present with a lump that a clinician can palpate, a radiologist can measure and a surgeon can excise, it is the histopathologist who ultimately provides the definitive diagnosis.

## 'When will my biopsy be ready, the patient is in clinic...'

Histopathologists make diagnoses by looking at tissues. In the mortuary it is often possible to reach a diagnosis quickly with the naked eye. For example it is possible to confidently diagnose a myocardial infarct

by identifying a fresh thrombus in a coronary artery, or pneumonia when there is pus in the lungs. This is so-called 'macroscopic' diagnosis.

However, the majority of diagnoses are made microscopically. This involves studying tissues and cells using a light microscope. Unlike other investigations such as blood tests and computed tomography scans, histological examination is a relatively slow process. Producing a diagnostic specimen is a predominantly manual process that can take several days.

First the tissue must be 'fixed' in formalin to prevent degradation and maintain its morphological integrity. Depending on the size and type of the specimen this can take between 24 and 48 hours. The requesting clinician/surgeon can make a significant contribution at this stage by ensuring that specimens are immediately placed in a large volume of formalin. Some surgeons try to help by incising certain specimens – this certainly aids fixation but can seriously hinder the assessment of resection margins so it is better to avoid doing this.

Once the specimen is fixed a histopathologist must dissect, photograph and sample it adequately. This produces 'tissue blocks' from which the familiar haematoxylin and eosin slides are produced (*Figure 1*).

The majority of histological diagnoses are made from the haematoxylin and eosin slide on the basis of morphology. This means that the tissues or cells display characteristic morphological features that indicate a pathological process (*Figure 2*). In such cases a diagnostic report can be ready within 2–3 days of receiving the specimen.

However, this is not always the case. A precise diagnosis (one always favoured by the patient) may require the examination of deeper levels in the tissue block or even further sampling of the specimen. Often ancillary tests are required. These are tests that aid the morphological assessment of the tissue and/or reveal the underlying molecular composition of the specimen. The former include chromogenic stains

**Dr Ian E Proctor** is Consultant Histopathologist in the Department of Cellular Pathology, University College London Hospital, London WC1E 6JJ  
([ian.proctor@nhs.net](mailto:ian.proctor@nhs.net))

which specifically stain certain microorganisms (e.g. bacteria and fungi) or tissue components (e.g. amyloid protein or fibrin). The latter include molecular tests such as immunohistochemical staining to identify disease-specific protein expression and techniques such as fluorescence in-situ hybridization and polymerase chain reaction which can detect disease-specific genetic abnormalities. Each of these tests can add up to 10 days to the diagnostic process.

## How to get the most out of your histopathologist

### Treat your specimen with respect

A specimen can become delayed almost as soon as it arrives in the department. Leaking specimens, specimens sent without formalin and incorrectly completed request forms are common causes of delay to specimens. Furthermore, unlike routine blood samples, histology specimens are typically hand-delivered leaving you at the mercy of the porters. If your

specimen is truly urgent then make sure you label it 'Urgent' and consider delivering it personally.

### Know your patients

While histopathologists are medically qualified they can not read minds or illegible handwriting. They especially like to know why you are sending a specimen, where it is from and whether or not the patient has any relevant past medical history. All these 'clues' will help them reach an accurate diagnosis. The absence of such key information can result in delays, unnecessary ancillary testing and additional costs.

### Consider a hospital postmortem

If a patient dies under your care you should consider requesting a hospital postmortem. Such requests are becoming increasingly rare and despite advances in radiological imaging autopsies frequently reveal significant pathology missed in life. If in doubt the duty pathologist will happily provide advice. This topic is explored further in the accompanying article about the hospital postmortem (Casey and Winstanley, 2015).

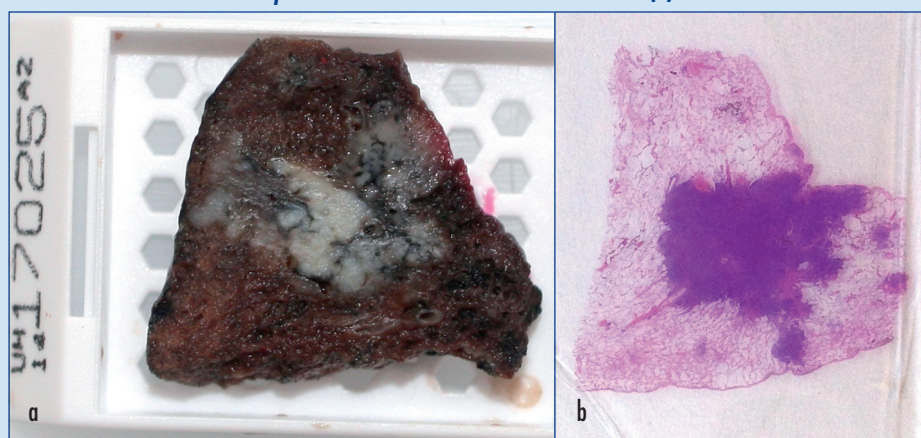
### The pathology report

If you have gone to the trouble of performing an invasive procedure and removing tissue for histology, then make sure you read the whole of the resulting report, not just the conclusion or 'bottom line'.

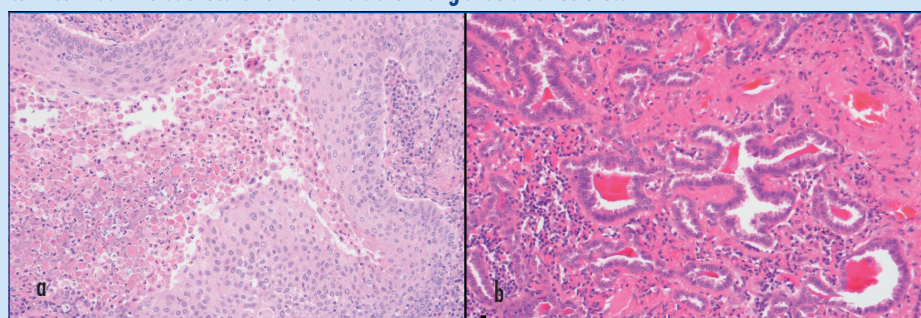
### Decoding the report

Pathologists, like most doctors, have developed a unique language in which they converse. Many of the terms are descriptive and identify characteristic diagnostic features – a selection of commonly used terms are translated in *Table 1*. Not all diagnoses

**Figure 1. a. Tissue block taken from a lung in which there is a carcinoma. b. Haematoxylin and eosin-stained section cut from paraffin embedded tissue block made from (a).**



**Figure 2. Microscopic images of two lung cancers (each taken at x 200 magnification). a. The squamous cell carcinoma forms solid nests with intracellular bridges and keratin formation (central cystic area). b. In contrast the adenocarcinoma forms abnormal glandular structures.**



**Table 1. Commonly used histological terms**

Granulomatous	A lesion contains variably sized collections of histiocytes (tissue macrophages). Some granulomas are necrotic (e.g. tuberculosis) while others are non-necrotic (e.g. sarcoidosis)
Differentiated	In a tumour this refers to how similar the tumour is to the tissue from which it originated, e.g. in contrast to squamous epithelium (seen in skin), poorly differentiated squamous cell carcinomas lack the intracellular bridges between cells and do not produce keratin. Differentiation can be graded well, moderate and poor. Patients with poorly differentiated tumours tend to do worse than those with well-differentiated ones
Pleomorphic	A term used to describe tumours comprising cells of different shapes and sizes. Pleomorphic tumours tend to have a worse prognosis
Mitotic rate	This refers to the number of mitoses present in a given area of a tumour. It is often used as a surrogate marker of tumour 'aggressiveness' – i.e. a tumour with a high mitotic rate is likely to be growing quickly and be more destructive
Lymphovascular invasion	This describes the presence of tumour emboli present within blood or lymphatic vessels. This is a worrying feature as it indicates that a tumour has entered the bloodstream and may be capable of metastasizing

are clear cut, especially when faced with small biopsies. In such cases the pathologist will try to convey his/her level of diagnostic confidence in the report and may recommend discussion at an multidisciplinary team meeting or even re-biopsy (Table 2).

Histology reports, especially those relating to solid tumour resections, frequently contain much more information than just the tumour type. For example, in the case of a lobectomy for lung cancer the report will define the type of lung cancer, its size and the presence or absence of lymph node metastases and direct spread into other structures. This information, together with clinical and radiological data, guides treatment and provides the tumour stage – a critical index of disease prognosis.

The pathology report will also describe the completeness of tumour excision. Unsurprisingly this is a powerful indicator of disease recurrence and positive margins may prompt treatment with local radiotherapy. Indeed the histological examination of resection margins has been central to development of new surgical approaches in the treatment of colorectal carcinoma – discussed further in the article in this issue (Palmer and West, 2015).

**Know the limits of a pathology report and attend multidisciplinary team meetings**

Disease processes often display a wide spectrum of morphological appearances and there can be considerable overlap between different pathological entities. For example, the inflammatory bowel diseases Crohn’s disease and ulcerative colitis share many histological features. Furthermore, there are similarities with other conditions such as infective colitis, diversion colitis and ischaemic colitis. In such circumstances it may not be possible to provide a definitive diagnosis based solely on the histological features present in a single biopsy.

Many cases require ‘clinicopathological correlation’, a process in which the histological findings are interpreted in the context of clinical and radiological findings. In cases of inflammatory bowel disease the histology report must be considered in the context of the site and extent of disease, the endoscopic appearances, behaviour over time, the response to treatment and whether there are any associated symptoms. The multidisciplinary team meeting is the perfect environment for this to be achieved.

**The future**

Histopathologists are still reliant on the morphological features of tissues and their constituent cells in order to make diagnoses. However, it is now increasingly possible to identify and more accurately characterize many diseases on the basis of their molecular or genetic composition. For example malignant breast cancer cells can be identified using immunohistochemical staining which indicates abnormal protein expression. Disease-specific gene defects can also be identified in fixed tissues using fluorescence in-situ hybridization and polymerase chain reaction. These tests not only provide diagnostic information but are increasingly being used to predict whether a patient is likely to respond to a specific class of therapeutic agent – so-called ‘personalized medicine’. With the development of ‘next generation’ or high throughput DNA sequencing it is now possible to identify literally thousands of genetic defects within a tumour. This information is likely to revolutionize our understanding of many diseases and provide new diagnostic and prognostic tools in the years ahead (Moore and Le Quesne, 2015). [BJHM](#)

*Conflict of interest: none.*

Casey L, Winstanley A (2015) The hospital postmortem: time for a revival. *Br J Hosp Med* 76(5): C77–C80 (doi.org/10.12968/hmed.2015.76.5.C77)  
 Moore DA, Le Quesne JPC (2015) The molecular approach to diagnosis in lung cancer. *Br J Hosp Med* 76(5): C74–6 (doi.org/10.12968/hmed.2015.76.5.C74)  
 Palmer TG, West NP (2015) Histopathology: improving outcomes in bowel cancer. *Br J Hosp Med* 76(5): C69–C73 (doi.org/10.12968/hmed.2015.76.5.C69)

**Table 2. Conveying levels of diagnostic confidence**

‘The features are those of...’ = the specimen has all the features necessary for a firm diagnosis
‘The features are consistent with...’ = the specimen lacks some diagnostic features but the clinical information provided would support this diagnosis
‘The features are suspicious of.../raise the possibility of...’ = the specimen has some diagnostic features and/or the specimen is limited/poorly preserved so a firm diagnosis cannot be made

**KEY POINTS**

- Histopathology usually provides the definitive diagnosis.
- The preparation of histological specimens takes several days – bear this in mind when booking follow-up outpatient appointments.
- Help your histopathologist by placing your specimen in sufficient formalin, completing a legible request form and providing clinical details and relevant past medical history.
- Always consider performing a hospital postmortem if one of your patients dies. If you do request one you should attend.
- Read the whole histology report and consider discussing the case at a multidisciplinary meeting.
- Molecular testing will play an increasing role in diagnostic histopathology – make sure you understand what the tests are and what they mean to your patients.