

ultrasound-guided transbronchial needle aspiration has also been suggested as a safe and effective alternative to conventional ultrasound-guided needle aspiration for sampling of thyroid tissue located below the thoracic inlet (Casal et al, 2014), an approach supported by this case. **BJHM**

Basaria S, Westra WH, Cooper DS (2001) Ectopic lingual thyroid masquerading as thyroid cancer metastases. *J Clin Endocrinol Metab* **86**(1): 392–395. <https://doi.org/10.1210/jcem.86.1.7130>

Casal RF, Phan MN, Keshava K et al (2014) The use of endobronchial ultrasound-guided transbronchial needle aspiration in the diagnosis of thyroid lesions. *BMC Endocr Disord* **14**: 88. <https://doi.org/10.1186/1472-6823-14-88>

Navani N, Lawrence DR, Kolvekar S et al; REMEDY

Trial Investigators (2012) Endobronchial ultrasound-guided transbronchial needle aspiration prevents mediastinoscopies in the diagnosis of isolated mediastinal lymphadenopathy: a prospective trial. *Am J Respir Crit Care Med* **186**(3): 255–260. <https://doi.org/10.1164/rccm.201203-0393OC>

Navani N, Nankivell M, Lawrence DR et al; Lung-BOOST trial investigators (2015) Lung cancer diagnosis and staging with endobronchial ultrasound-guided transbronchial needle aspiration compared with conventional approaches: an open-label, pragmatic, randomised controlled trial. *Lancet Respir Med* **3**(4): 282–289. [https://doi.org/10.1016/S2213-2600\(15\)00029-6](https://doi.org/10.1016/S2213-2600(15)00029-6)

Noussios G, Anagnostis P, Goulis DG, Lappas D, Natsis K (2011) Ectopic thyroid tissue: anatomical, clinical, and surgical implications of a rare entity. *Eur J Endocrinol* **165**(3): 375–382. <https://doi.org/10.1530/EJE-11-0461>

LEARNING POINTS

- Ectopic thyroid should form part of the differential diagnosis for patients with mediastinal lesions of unknown aetiology, especially in the absence of B-symptoms.
- Ectopic thyroid can be non-functional and therefore scintigraphy alone cannot be relied upon to diagnose all cases.
- Endobronchial ultrasound-guided transbronchial needle aspiration is an effective diagnostic technique in mediastinal diseases of this nature.

Images in Medicine

Upper gastrointestinal bleeding caused by fistula of the stomach and splenic artery pseudoaneurysm

A 47-year-old man with chronic pancreatitis potentiated by long-time alcohol consumption was admitted to the emergency medicine department for haematemesis. Emergency

oesophagogastroduodenoscopy revealed a spherical growth on the posterior wall of the proximal third of the stomach corpus with three adherent clots, two of which were irrigated with water. Emergency computed tomography angiography of the abdomen showed a pseudocyst of the pancreatic tail with a pseudoaneurysm of the splenic artery. This was causing active extravasation of contrast material into the stomach lumen (*Figure 1*) (Tessier et al, 2003; Budimir et al, 2012).

A right transfemoral approach was used to perform angiography of the visceral branches and showed the truncus coelicus. The splenic artery was selectively catheterized using the

Sidewinder 6F guiding catheter. Embolization was performed using the 'sandwich' technique before and after the pseudoaneurysm by installing pushable coils of various dimensions, 6–10 mm wide. The arteriogastric fistula was permanently occluded using glue (*Figure 2*). Control angiography showed a good embolization effect and prompt creation of collateral circulation (gastroduodenal artery) to the spleen. **BJHM**

Budimir I, Nikolić M, Supanc V, Ljubicić N, Krpan T, Zovak M, Sabol M (2012) Secondary arterioenteric fistula: case report and review of the literature. *Acta Clin Croat* **51**: 79–82

Tessier DJ, Stone WM, Fowl RJ, Abbas MA, Andrews JC, Bower TC, Gloviczki P (2003) Clinical features and management of splenic artery pseudoaneurysm: case series and cumulative review of literature. *J Vasc Surg* **38**: 969–974. [https://doi.org/10.1016/S0741-5214\(03\)00710-9](https://doi.org/10.1016/S0741-5214(03)00710-9)

Dr I Budimir, Consultant Gastroenterologist and Hepatologist, Department of Gastroenterology and Hepatology, Clinic of Internal Medicine, Sestre milosrdnice University Hospital Centre, Zagreb, Croatia

Dr P Jurčić, Medical Oncology Trainee, Department of Radiotherapy and Medical Oncology, University Hospital for Tumours, Sestre milosrdnice University Hospital Centre, 10000, Zagreb, Croatia

Dr M Nikolić, Consultant Gastroenterologist and Hepatologist, Division of Gastroenterology, Department of Internal Medicine, Sestre milosrdnice Clinical Hospital Centre, University of Zagreb School of Medicine and School of Dental Medicine, Zagreb, Croatia

Dr N Ljubicić, Professor of Medicine and Consultant Gastroenterologist and Hepatologist, Division of Gastroenterology, Department of Internal Medicine, Sestre milosrdnice Clinical Hospital Centre, University of Zagreb School of Medicine and School of Dental Medicine, Zagreb, Croatia

Correspondence to: Dr P Jurčić (petra.jurcic@gmail.com)

Figure 1. Volume-rendering computed tomography image of the splenic artery pseudoaneurysm.

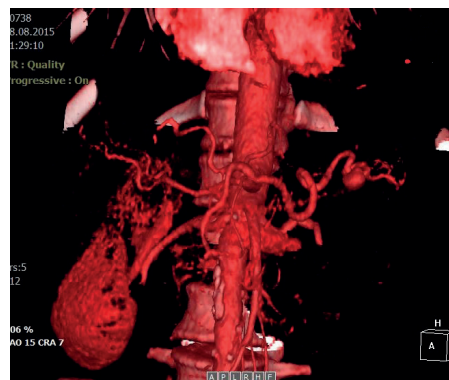


Figure 2. Follow-up oesophagogastroduodenoscopy showing the location of the obliterated arteriogastric fistula, about 1 mm in diameter, in the proximal third of the stomach.

