

Artifact simulating supracondylar femoral fracture on computed tomography

A 40-year-old man was involved in a machine accident in which his right knee was crushed. A tibial plateau fracture and femoral condylar fracture were detected by X-ray (*Figure 1*). The sagittal and three-dimensional reconstruction computed tomography images were considered to also show a supracondylar femoral fracture (*Figure 2*), which it was suggested should be treated with open reduction and internal fixation.

However, one orthopaedic surgeon thought that the supracondylar femoral fracture was an artifact because it lacked a fracture line in the coronal reconstruction computed tomography (*Figure 3*) and because there were possible artifacts in three cross-sectional images (*Figure 4*). Sagittal

magnetic resonance imaging did not show a supracondylar femoral fracture (*Figure 5*).

The sagittal computed tomography images were closely studied again and anterior and posterior duplication of soft tissue was found which is highly suggestive of motion artifact (*Figure 2* white arrows). Three days later,

another computed tomography scan of the knee was performed and the supracondylar femoral fracture was non-existent (*Figure 6*). The patient was treated with external fixation using plaster on the lower limb and surgery was not required. **BJHM**

Figure 1. Anteroposterior and lateral film showing tibial plateau fracture and femoral condylar fracture.

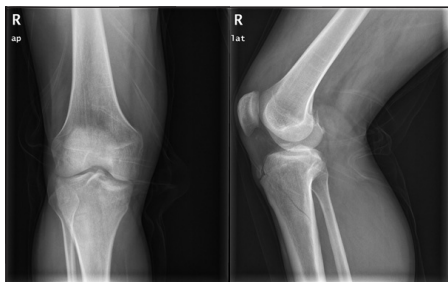

Figure 2. Sagittal and three-dimensional reconstruction computed tomography images showing tibial plateau fracture, femoral condylar fracture and supracondylar femoral fracture (arrow indicates motion artifact seen anteriorly and posteriorly).

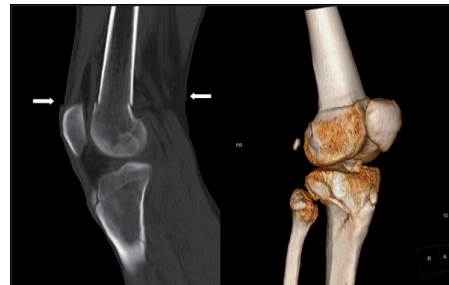


Figure 3. Coronal reconstruction computed tomography image showing supracondylar femoral fracture is non-existent.

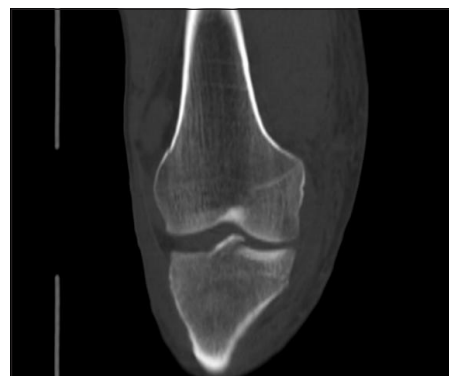

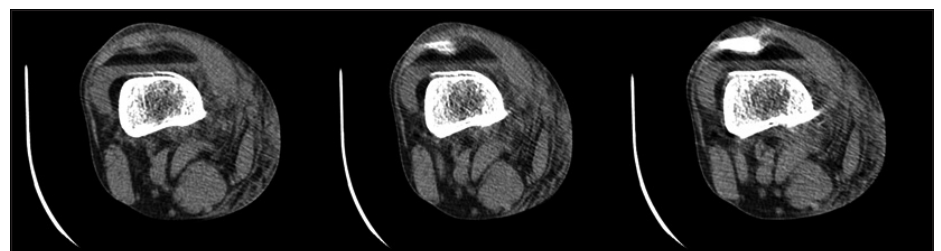
Figure 5. Sagittal T2-weighted magnetic resonance image showing no supracondylar femoral fracture.

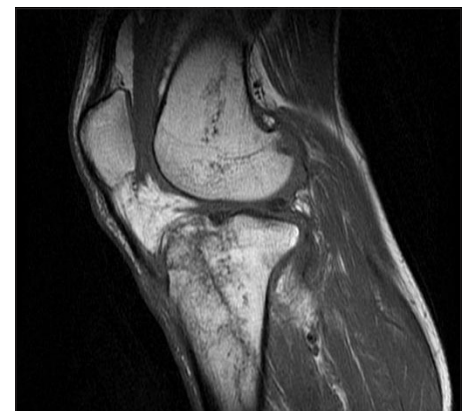

Figure 6. Three-dimensional reconstruction showing no supracondylar femoral fracture (second computed tomography scan).

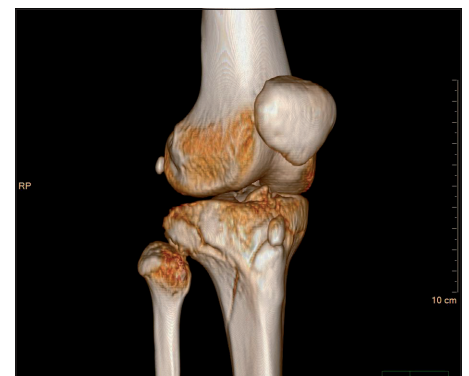

Figure 4. Cross-sectional computed tomography images showing possible artifacts.



***Dr Su Hao** is Attending Surgeon in the Department of Traumatic Orthopaedics, the Affiliated Yantai Yuhuangding Hospital of Qingdao University, Yantai, Shandong Province, China

***Ms Liu Juan** is Associate Professor in the YanTai Center for Disease Control and Prevention, Yantai, Shandong Province, China

Professor Wang Xin is Consultant Orthopaedic Surgeon in the Department of Traumatic Orthopaedics, the Affiliated Yantai Yuhuangding Hospital of Qingdao University, Yantai, Shandong Province, China

Correspondence to: Dr S Hao (shj1022@163.com)

**Dr S Hao and Ms L Juan contributed equally to this work and should be regarded as first joint authors*