

Parathyroid surgery: from inception to the modern day

The concept of surgery for hyperparathyroidism is still relatively novel. This is primarily because our understanding of the parathyroids and their function and dysfunction is only recent. The evolution of our understanding of hyperparathyroidism has guided the introduction and development of parathyroid surgery. Advances in technology have led to leaps in diagnostic capability and preoperative workup and have reduced surgical morbidity, culminating in an expansion of the availability of surgery for patients and the use of internationally recognized guidelines to predict surgical appropriateness in asymptomatic patients.

As a result of technological advancement, particularly from the 1970s onwards, and an increased awareness and recognition of the conditions involved, the majority of patients now operated on for hyperparathyroidism are well with biochemical disease rather than symptomatic with overt disease. This is a far cry from the pre-1970s era when 75% of surgical patients had symptomatic nephrocalcinosis.

This review describes the history of parathyroid surgery and its evolution to contemporary best practice.

The parathyroid glands

In 1864, Sir Richard Owen (Hunterian Professor and Conservator of the museum in the Royal College of Surgeon of England) published his dissection findings of a great Indian rhinoceros. He described a small yellow gland attached to the thyroid, which is now recognized as the first description of the parathyroid gland (Owen, 1862). In 1880, Ivar Sandström (a Swedish medical student) identified a gland entirely separate from but closely adjacent to the thyroid gland in a dog, and subsequently in other animals. He eventually progressed to human cadaveric dissection and identified symmetrically located glands which he named glandulae parathyroidae (Sandström et al, 1938) (*Figure 1*). However, it was not until 1891 that Eugene Gley, a French physiologist, reported tetany in dogs when these glands were removed during thyroidectomy (Gley, 1891).

Simultaneously, Friedrich von Recklinghausen reported a patient with severe bone disease including pathological fractures, cysts and brown cell tumours, subsequently referred to as 'osteitis fibrosa cystica of von Recklinghausen' (Recklinghausen, 1891). This was not correlated to parathyroid abnormality until 1915, when Friedrich Schlagenhauer identified a single parathyroid tumour (on post-mortem examination) in two patients with osteomalacia (Schlagenhauer, 1915).

ABSTRACT

Parathyroid surgery has undergone great changes since its inception less than a century ago. It is still the only definitive option available to cure primary or tertiary hyperparathyroidism. This review details the development of parathyroid surgery, our understanding of hyperparathyroidism and the treatment options available. It also discusses the technological advances that have enabled parathyroid localization and prediction of surgical success.

Development of the understanding of hyperparathyroidism

A Viennese pathologist, Jacob Erdheim, having previously demonstrated tetany in animals undergoing parathyroidectomy, performed post-mortem examinations on patients with osteomalacia identifying parathyroid hyperplasia and tumours (Erdheim, 1907). He hypothesized an association between the parathyroid glands and osteomalacia. Unfortunately, this theorized a compensatory hypertrophy or hyperplasia of the parathyroid glands in response to bone disease.

This theory was challenged and successfully disproved by Felix Mandl in 1925. Initially he attempted to treat patients with cystic bone lesions and elevated levels of urinary calcium by transplantation of cadaveric parathyroid tissue. When this failed, on 30 July 1925, he performed exploratory surgery under local anaesthesia on a patient suffering from osteitis fibrosa and found a parathyroid tumour. Following removal of the tumour, the patient's condition improved (Mandl, 1925). This landmark intervention flew in the face of Erdheim's compensation theory and was an epochal moment in understanding the relationship between parathyroid tumours and bone disease.

Subsequent landmark occurrences in the development of the understanding of hyperparathyroidism included confirmation of the role of parathyroid hormone in calcium regulation by Collip in 1925, when he used parathyroid hormone extract to relieve tetany induced by

Mr Neeraj Sethi, Specialist Registrar, Department of Otorhinolaryngology-Head and Neck Surgery, Hull Teaching Hospitals NHS Trust, Castle Hill Hospital, Cottingham, East Yorkshire

Mr R James A England, Consultant Ear, Nose and Throat Surgeon, Department of Otorhinolaryngology-Head and Neck Surgery, Hull Teaching Hospitals NHS Trust, Castle Hill Hospital, Cottingham, East Yorkshire HU16 5JQ

Correspondence to: Mr RJA England (rjaeathome@aol.com)

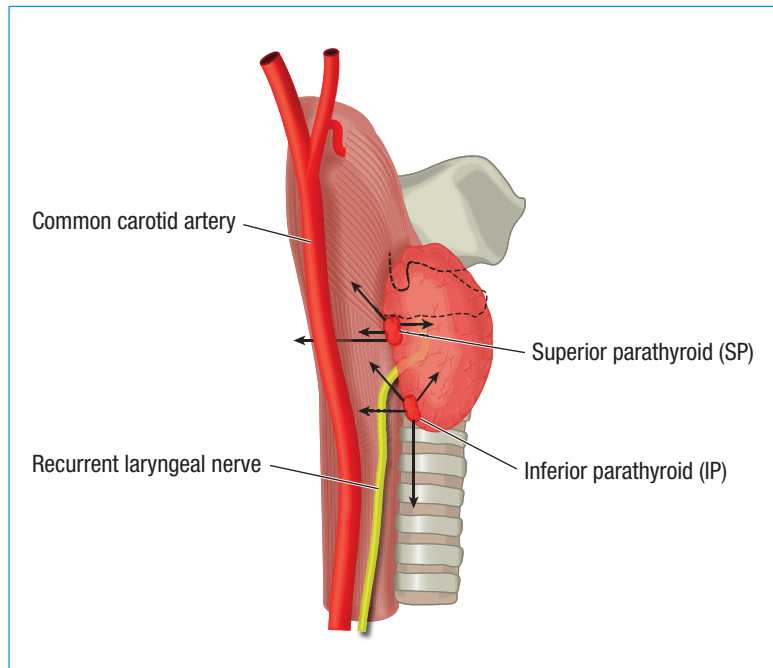


Figure 1. Position of the parathyroid glands. The superior parathyroid is in this position in 80% of cases but it may be higher, retro-oesophageal, paraoesophageal, intrathyroidal or lateral because of migration or embryological ectopia. The inferior parathyroid is in this position in 70% of cases but may be higher, intrathyroidal, intramediastinal, intrathyroidal or lateral.

parathyroidectomy (Collip and Leitch, 1925). However, parathyroid hormone extraction was not reliably and reproducibly possible until 1959.

At this stage, hyperparathyroidism was a disease entity that presented clinically. Indeed Albright et al (1934) noted that nearly 80% of patients with osteitis fibrosa cystica of von Recklinghausen had nephrocalcinosis or nephrolithiasis. These became the hallmark features of hyperparathyroidism until the latter half of the 20th century.

Development of the understanding of surgical options

Before the 1950s, diagnostic tests were carried out by technicians and were slow and expensive with frequent errors occurring. However, in 1951, the American biochemist Leonard Skeggs invented the autoanalyser. The design was purchased by the Technicon Company in 1954 but initially there was little interest in the new technology with only 50 machines being sold in 1957. However, by 1969, 18 000 machines were sold annually. Rapid advances in this new technology led to cheap, rapid serum analysis. This in turn led to an increased awareness of hypercalcaemia found incidentally on serum sampling and the earlier diagnosis of hyperparathyroidism (Marsh, 1963).

Although the ability to diagnose hyperparathyroidism had improved greatly as a result of technological advances, the optimal surgical treatment for the hyperparathyroid patient was still controversial. Many prominent surgeons advocated a 3.5 gland parathyroidectomy to prevent the high recurrence rate reported at the time (Block et al, 1967).

It was generally agreed that 'all four parathyroids should be identified before any tissue is excised' (Taylor, 1976). However, the 3.5 operation was associated with a 10% tetany rate postoperatively, in some cases a symptom more severe than the original complaint. Again this particular surgical impasse has, to a great extent, been resolved by the evolution of understanding of the disease processes underlying hyperparathyroidism, and technological developments refining the clinician's ability to localize disease pre- and intraoperatively, and predict cure.

Previously Cope et al (1958), describing a series of 200 cases, showed clearly that the vast majority of cases were caused by single gland disease (79% in this series). Subsequently others demonstrated excellent results by removing only enlarged glands leaving other normal-sized glands in situ (Wang, 1981). Simultaneously, understanding of the differing parathyroid pathologies requiring surgical intervention was growing. Secondary hyperparathyroidism (hyperparathyroidism caused by stimuli external to the glands themselves, most commonly renal failure and hypovitaminosis D) was increasingly treated surgically with subtotal parathyroidectomy (Katz et al, 1968).

Parathyroid cancer, a cancer which only comprises 0.005% of cancers recorded in the National Cancer Database, was described by Wilder in 1929, but the histopathological criteria required to diagnose parathyroid cancer were not described until 1973 (Schantz and Castleman, 1973; Hundahl et al, 1999). Although the optimal treatment of parathyroid cancer is still debatable, particularly in the rare genetically associated hyperparathyroidism-jaw tumour syndrome, preoperative diagnosis is difficult in many cases and as it is recognized that the tumour is radio-resistant, en bloc resection in suspected cases is now widely accepted as appropriate (Lee et al, 2016).

In 1954, Wermer was the first to describe the phenotype for multiple endocrine neoplasia type 1 (MEN1) in a family in which a father and four of nine children were affected (Wermer, 1954). In 1961, Sipple described a patient with bilateral pheochromocytomas, thyroid cancer and enlarged parathyroid glands (MEN2A, Sipple syndrome). Increasing understanding of these two inherited conditions has led to general acceptance that MEN1 hyperparathyroidism is a far more aggressive disease process than MEN2A hyperparathyroidism, which needs treating differently (Li and Simonds, 2016).

In addition new drug therapies, most importantly the addition of cinacalcet, a calcium receptor antagonist or calcimimetic, to the pharmacological armamentarium, has modified the need for parathyroidectomy, particularly in patients with secondary hyperparathyroidism (Peacock et al, 2005).

With increasing understanding and earlier diagnosis of hyperparathyroidism, it is now far more rare for patients to present with evidence of overt end organ damage. The widespread use of the serum autoanalyser has resulted in most cases of hyperparathyroidism being diagnosed

Table 1. International consensus guidelines for parathyroidectomy in the asymptomatic patient

Measurement	
Serum calcium	Persistently elevated by 0.25 mmol/litre
Skeletal	A T score -2.5 or worse on DEXA (dual energy X-ray absorptiometry) at any site
	B Vertebral fracture
Renal	A Creatinine clearance <60 cc/min
	B 24-hour urinary calcium >400 mg/day
	C Presence of nephrolithiasis or nephrocalcinosis
Age	<50 years

From Bilezikian et al (2014)

Table 2. Localization techniques used during parathyroid surgery

Preoperative methods	Ultrasound or technetium sestamibi scanning with or without radioiodine subtraction
	Computed tomography or magnetic resonance imaging (particularly for ectopic disease)
	Four-dimensional computed tomography
	Positron emission tomography-computed tomography
Intraoperative methods	Minimally invasive image-guided or traditional four-gland exploration
	Gamma probe localization with technetium-99m
	Intraoperative parathyroid hormone monitoring (a fall of 50% or greater is an accurate predictor of surgical success)
	Highly selective venous sampling (rarely used for revision cases)
	Temporary inferior thyroid artery occlusion (may lead to discolouration of parathyroid tissue differentiating it from surrounding fat)
	Intravenous methylene blue
	Frozen section confirmation

following an incidental finding of hypercalcaemia on routine biochemical testing. The question subsequently arises as to whether surgery is necessary in these patients. As a result, an international workshop of experts in the field of hyperparathyroidism has developed guidelines to aid decision making in the case of the asymptomatic patient. From their first release in 1990, these guidelines have been progressively updated in 2002, 2008 and 2013 (Bilezikian et al, 2014) (*Table 1*). The trend shows an increased tendency to recommend surgery in otherwise well patients because of the increasing recognition of the cardiovascular, skeletal, renal and neurocognitive effects of the disease process.

Parathyroid localization

The debate and refinement of surgical philosophy has been heavily influenced by advancement in pre- and intraoperative localization strategies (*Table 2*). Parathyroid localization began to create interest in the 1950s with the development of cine-oesophagography and arteriography.

In the 1960s, the use of toluidine blue for parathyroid localization was first described in dogs and quickly demonstrated as effective in humans (Klopper and Moe, 1966). Owing to its potentially cardiotoxic effects, this was replaced by the use of methylene blue as proposed by Dudley (1971) and this technique is still used by some today. However, adverse neurological events have been reported in patients taking serotonergic medications and the use of methylene blue is by no means universal (Patel et al, 2012).

Selective venous catheterization, involving passing a catheter through the femoral vein, inferior vena cava, right heart and into the neck veins, became a useful adjunct for preoperative localization particularly in revision surgery (O'Riordan et al, 1971). Selected blood samples are taken to localize the area of peak parathyroid hormone release and hence the region containing the overactive parathyroid gland. This technique is reserved for revision cases and again is only practiced in limited centres as morbidity is potentially high.

KEY POINTS

- The parathyroid glands were the last endocrine glands to be discovered and described.
- Parathyroid surgery is comparatively new and techniques continue to develop in parallel with technological advances.
- The nationwide introduction of the serum autoanalyser has led to earlier diagnosis and the concept of asymptomatic hyperparathyroidism.
- International guidelines exist that enable surgeons to advise when and when not to operate on asymptomatic patients, these are regularly updated.

Reports of ultrasonography identifying parathyroid tumours first arose in the 1970s. Ultrasound, while operator dependent, has been reported to successfully identify single adenomas in 93% of cases, when used as the sole imaging modality before surgery (Reeder et al, 2002). The use of colour or power Doppler imaging to distinguish differing blood flow in tissues of similar appearance is key in the successful application of ultrasound in parathyroid imaging (Baskin et al, 2008).

Parathyroid localization techniques have increasingly involved the use of radionuclides. Some centres suggest that nuclear scintigraphy (technetium Tc99m sestamibi) can successfully identify solitary adenomas in 95% of cases and multigland disease in 80% (Thompson et al, 1994; Hindié et al, 1997). Current accepted practice when attempting preoperative localization recommends combining ultrasound and sestamibi to optimize the likelihood of success in a minimally invasive or focussed parathyroidectomy. The combination of these imaging modalities has given rise to the phrase 'double image concordant'.

Ectopic parathyroid adenomata occur in 10% of cases and multigland disease in 15% (Gunasekaran et al, 2015). These present additional challenges when localization is attempted and lead to increased surgical failure rates. Improved localization results in these situations are being reported using four-dimensional computed tomography, C-methionine positron emission tomography-computed tomography, C-choline positron emission tomography-computed tomography and single photon emission computed tomography although optimal imaging guidelines in primary surgery, multi-gland disease and revision surgery are still debated and these modalities are less readily available in most centres (Hindié et al, 2015; Lee et al, 2016). Positron emission tomography-magnetic resonance imaging, a novel imaging modality in this field, has also shown promise in revision cases (Purz et al, 2013).

Radionuclides may also be used intraoperatively. Intraoperative frozen section provides accurate tissue confirmation in up to 99% of cases (Westra et al, 1998). However, this is time-consuming and prohibits efficient theatre time usage, so remains an unpopular regular choice for many surgeons.

Radio-guided surgery is used in some centres with considerable success. Norman and Chheda first reported their results using a preoperative injection of technetium

Tc-99 and a gamma probe intraoperatively in the 1990s (Norman, 1997; Norman and Chheda, 1997). This technique is particularly useful for assisting in minimally invasive, ambulatory surgery and has been reported to deliver success rates of 100% (Desiato et al, 2016).

In the 1980s, the development of a rapid intact parathyroid hormone molecule assay paved the way towards a realistic ability to surgically manage parathyroid disease in a focussed manner (Sebag et al, 2003). Before 1987 parathyroid hormone radioimmunoassays were available and useful in confirming the diagnosis of hyperparathyroidism, but the assays available measured the C-terminal of the parathyroid hormone molecule or the mid-molecule component. As the fragments had variable half lives results could be misleading. In 1987, however, Nussbaum's team in Boston developed a two-site antibody immunoradiometric assay that measured intact parathyroid hormone levels. By measuring two sites of the parathyroid hormone molecule accurate results were obtained (Nussbaum et al, 1987, 1988).

Subsequently, the utility of the short half-life of parathyroid hormone (3–5 minutes) enabled accurate prediction of cure intraoperatively when intraoperative assays demonstrated a 50% or greater fall in preoperative parathyroid hormone levels once suspected adenomatous tissue had been removed (Irvin et al, 2004), and also implied multigland disease when the fall did not occur (Irvin et al, 1993). The necessity of intraoperative parathyroid hormone level monitoring, although now a cheap potential adjunct to surgery, remains debatable with those for and those against, the latter group believing that the added benefit is at best marginal with added cost (Roshan et al, 2006; Morris et al, 2010).

Conclusions

The parathyroid gland was the last endocrine gland recognized and the history of parathyroid surgery has existed for less than 100 years. During that period the understanding of the disease processes causing hyperparathyroidism and their systemic relevance has developed substantially. This development has been paralleled by advances in technology that have enabled earlier diagnosis and preoperative and intraoperative localization, allowing the introduction of minimally invasive techniques with increased surgical success rates and reduced surgical morbidity. Modern day parathyroid surgery requires understanding of the disease process causing the presentation, adequate preoperative workup and subsequent tailoring of the operative intervention for the appropriate surgical scenario. **BJHM**

Conflict of interest: none.

- Albright F, Aub JC, Bauer W (1934) Hyperparathyroidism: A common and polymorphic condition as illustrated by 17 cases from one clinic. *J Am Med Assoc* **102**(16): 1276. <https://doi.org/10.1001/jama.1934.02750160010003>
- Baskin HJ, Duick DS, Levine RA (2008) *Thyroid Ultrasound and Ultrasound-guided FNA*. Springer, New York

- Bilezikian JP, Brandi ML, Eastell R, Silverberg SJ, Udelsman R, Marcocci C, Potts JT Jr (2014) Guidelines for the management of asymptomatic primary hyperparathyroidism: summary statement from the Fourth International Workshop. *J Clin Endocrinol Metab* **99**(10): 3561–3569. <https://doi.org/10.1210/jc.2014-1413>
- Block MA, Greenawald K, Horn RC Jr, Frame B (1967) Involvement of multiple parathyroids in hyperparathyroidism. *Am J Surg* **114**(4): 530–537. [https://doi.org/10.1016/0002-9610\(67\)90012-8](https://doi.org/10.1016/0002-9610(67)90012-8)
- Collip JB, Leitch DB (1925) A Case of Tetany treated with Parathyrin. *Can Med Assoc J* **15**(1): 59–60.
- Cope O, Keynes WM, Roth S, Castleman B (1958) Primary chief-cell hyperplasia of the parathyroid glands: a new entity in the surgery of hyperparathyroidism. *Ann Surg* **148**(3): 375–388. <https://doi.org/10.1097/00000658-195809000-00007>
- Desiato V, Melis M, Amato B, Bianco T, Rocca A, Amato M, Quarto G, Benassai G (2016) Minimally invasive radioguided parathyroid surgery: A literature review. *Int J Surg* **28** (Suppl 1): S84–S93. <https://doi.org/10.1016/j.ijss.2015.12.037>
- Dudley NE (1971) Methylene blue for rapid identification of the parathyroids. *BMJ* **iii**(5776): 680–681. <https://doi.org/10.1136/bmj.3.5776.680>
- Erdheim J (1907) Über Epithelkörperbefunde bei Osteomalacie. Sitzungsber d kais Akad d Wissensch in Wien, math naturw. *Klasse Abt III* **116**: 311–370.
- Gley E (1891) Sur Les fonctions du corps thyroïde. *CR Soc Biol (Paris)* **43**: 841–847.
- Gunasekaran S, Wallace H, Snowden C, Mikl D, England RJA (2015) Parathyroid ectopia: development of a surgical algorithm based on operative findings. *J Laryngol Otol* **129**(11): 1115–1120. <https://doi.org/10.1017/S0022215115002273>
- Hindie E, Mellière D, Perlemuter L, Jeanguillaume C, Galle P (1997) Primary hyperparathyroidism: higher success rate of first surgery after preoperative Tc-99m sestamibi-I-123 subtraction scanning. *Radiology* **204**(1): 221–228. <https://doi.org/10.1148/radiology.204.1.9205251>
- Hundahl SA, Fleming ID, Fremgen AM, Menck HR; The American College of Surgeons Commission on Cancer and the American Cancer Society (1999) Two hundred eighty-six cases of parathyroid carcinoma treated in the U.S. between 1985–1995. *Cancer* **86**(3): 538–544. [https://doi.org/10.1002/\(SICI\)1097-0142\(19990801\)86:3<538::AID-CNCR25>3.0.CO;2-K](https://doi.org/10.1002/(SICI)1097-0142(19990801)86:3<538::AID-CNCR25>3.0.CO;2-K)
- Irvin GL 3rd, Dembrow VD, Prudhomme DL (1993) Clinical usefulness of an intraoperative quick parathyroid hormone assay. *Surgery* **114**(6): 1019–1022, discussion 1022–1023.
- Irvin GL 3rd, Solorzano CC, Carneiro DM (2004) Quick intraoperative parathyroid hormone assay: surgical adjunct to allow limited parathyroidectomy, improve success rate, and predict outcome. *World J Surg* **28**(12): 1287–1292. <https://doi.org/10.1007/s00268-004-7708-6>
- Katz AI, Hampers CL, Wilson RE, Bernstein DS, Wachman A, Merrill JP (1968) The place of subtotal parathyroidectomy in the management of patients with chronic renal failure. *Trans Am Soc Artif Intern Organs* **14**: 376–384.
- Klopper PJ, Moe RE (1966) Demonstration of the parathyroids during surgery in dogs, with preliminary report of results in some clinical cases. *Surgery* **59**(6): 1101–1107.
- Lee GS, McKenzie TJ, Mullan BP, Farley DR, Thompson GB, Richards ML (2016) A multimodal imaging protocol, 123I/99Tc-Sestamibi, SPECT, and SPECT/CT, in primary hyperparathyroidism adds limited benefit for preoperative localization. *World J Surg* **40**(3): 589–594. <https://doi.org/10.1007/s00268-015-3389-6>
- Li Y, Simonds WF (2016) Endocrine neoplasms in familial syndromes of hyperparathyroidism. *Endocr Relat Cancer* **23**(6): R229–R247. <https://doi.org/10.1530/ERC-16-0059>
- Mandl F (1925) Therapeutischer Versuch bei Ostitis fibrosa generalisata mittels extirpation eines Epithelkörperchentumors. *Wien Klin Wochenschr* **38**: 1343–1344.
- Marsh WH (1963) *Automation in Clinical Chemistry*. Thomas, Springfield, Ill
- Morris LF, Zanocco K, Ituarte PHG, Ro K, Duh QY, Sturgeon C, Yeh MW (2010) The value of intraoperative parathyroid hormone monitoring in localized primary hyperparathyroidism: a cost analysis. *Ann Surg Oncol* **17**(3): 679–685. <https://doi.org/10.1245/s10434-009-0773-1>
- Norman J (1997) The technique of intraoperative nuclear mapping to facilitate minimally invasive parathyroidectomy. *Cancer Control* **4**(6): 500–504.
- Norman J, Chheda H (1997) Minimally invasive parathyroidectomy facilitated by intraoperative nuclear mapping. *Surgery* **122**(6): 998–1004, discussion 1003–1004. [https://doi.org/10.1016/S0039-6060\(97\)90201-4](https://doi.org/10.1016/S0039-6060(97)90201-4)
- Nussbaum SR, Zahradnik RJ, Lavigne JR et al (1987) Highly sensitive two-site immunoradiometric assay of parathyrin, and its clinical utility in evaluating patients with hypercalcemia. *Clin Chem* **33**(8): 1364–1367.
- Nussbaum SR, Thompson AR, Hutcheson KA, Gaz RD, Wang CA (1988) Intraoperative measurement of parathyroid hormone in the surgical management of hyperparathyroidism. *Surgery* **104**(6): 1121–1127.
- O’Riordan JLH, Kendall BE, Woodhead JS (1971) Preoperative localisation of parathyroid tumours. *Lancet* **298**(7735): 1172–1175. [https://doi.org/10.1016/S0140-6736\(71\)90488-0](https://doi.org/10.1016/S0140-6736(71)90488-0)
- Owen R (1862) On the anatomy of the Indian Rhinoceros (Rh. Unicornis, L.). *Trans Zool Soc Lond* **4**: 31–58.
- Patel HP, Chadwick DR, Harrison BJ, Balasubramanian SP (2012) Systematic review of intravenous methylene blue in parathyroid surgery. *Br J Surg* **99**(10): 1345–1351. <https://doi.org/10.1002/bjs.8814>
- Peacock M, Bilezikian JP, Klassen PS, Guo MD, Turner SA, Shoback D (2005) Cinacalcet hydrochloride maintains long-term normocalcemia in patients with primary hyperparathyroidism. *J Clin Endocrinol Metab* **90**(1): 135–141. <https://doi.org/10.1210/jc.2004-0842>
- Purz S, Kluge R, Barthel H, Steinert F, Stumpp P, Kahn T, Sabri O (2013) Visualization of ectopic parathyroid adenomas. *N Engl J Med* **369**(21): 2067–2069. <https://doi.org/10.1056/NEJMc1305558>
- Recklinghausen VF (1891) Die fibröse oder deformierende Ostitis, die Osteomalacie und die osteoplastische Carcinose in Ihren gegenseitigen Beziehungen. In: Festschrift R. Virchow zu seinem 71. Geburtstag. G. Reimer, Berlin
- Reeder SB, Desser TS, Weigel RJ, Jeffrey RB (2002) Sonography in primary hyperparathyroidism: review with emphasis on scanning technique. *J Ultrasound Med* **21**(5): 539–552, quiz 553–554. <https://doi.org/10.7863/jum.2002.21.5.539>
- Roshan A, Kamath B, Roberts S, Atkin SL, England RJA (2006) Intra-operative parathyroid hormone monitoring in secondary hyperparathyroidism: is it useful? *Clin Otolaryngol* **31**(3): 198–203. <https://doi.org/10.1111/j.1749-4486.2006.01200.x>
- Sandström IV, Seipel CGM, Peters CH, Fulton JF, Hammar JA (1938) *On a new gland in man and several mammals (glandulae parathyroideae)*. The Johns Hopkins Press, Baltimore
- Schantz A, Castleman B (1973) Parathyroid carcinoma. A study of 70 cases. *Cancer* **31**(3): 600–605. [https://doi.org/10.1002/1097-0142\(197303\)31:3<600::AID-CNCR2820310316>3.0.CO;2-0](https://doi.org/10.1002/1097-0142(197303)31:3<600::AID-CNCR2820310316>3.0.CO;2-0)
- Schlagenhauser F (1915) Zwei Fälle von Parathyreoideatumoren. Offizielles Protokoll der k.k. Gesellschaft der Aerzte in Wien Sitzung von 3 Dezember 1915. *Wien Klin Wochenschr* **28**: 1362.
- Sebag F, Shen W, Brunaud L, Kebebew E, Duh QY, Clark OH (2003) Intraoperative parathyroid hormone assay and parathyroid reoperations. *Surgery* **134**(6): 1049–1055, discussion 1056. <https://doi.org/10.1016/j.surg.2003.08.007>
- Sipple JH (1961) The association of pheochromocytoma with carcinoma of the thyroid gland. *Am J Med* **31**(1): 163–166. [https://doi.org/10.1016/0002-9343\(61\)90234-0](https://doi.org/10.1016/0002-9343(61)90234-0)
- Taylor S (1976) Hyperparathyroidism: retrospect and prospect. *Ann R Coll Surg Engl* **58**(4): 255–265.
- Thompson GB, Mullan BP, Grant CS et al (1994) Parathyroid imaging with technetium-99m-sestamibi: an initial institutional experience. *Surgery* **116**(6): 966–972, discussion 972–973.
- Wang CA (1981) Surgery of hyperparathyroidism: A conservative approach. *J Surg Oncol* **16**(3): 225–228. <https://doi.org/10.1002/jso.2930160305>
- Wermer P (1954) Genetic aspects of adenomatosis of endocrine glands. *Am J Med* **16**(3): 363–371. [https://doi.org/10.1016/0002-9343\(54\)90353-8](https://doi.org/10.1016/0002-9343(54)90353-8)
- Westra WH, Pritchett DD, Udelsman R (1998) Intraoperative confirmation of parathyroid tissue during parathyroid exploration: a retrospective evaluation of the frozen section. *Am J Surg Pathol* **22**(5): 538–544. <https://doi.org/10.1097/00000478-199805000-00003>