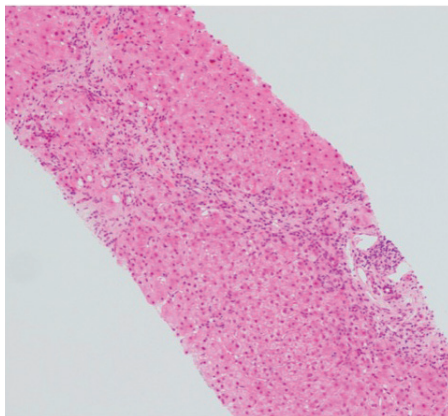


# Chronic hepatitis in the transplant patient

## Introduction

Hepatitis E virus typically causes an acute spontaneously-resolving hepatitis illness following enteric transmission. This article reports a renal transplant recipient who had fatigue and a persistent elevated serum alanine aminotransferase level of 200–350 U/litre. A standard battery of liver serological investigations and hepatobiliary imaging failed to explain his transaminitis. A liver biopsy showed significant liver fibrosis. He was subsequently found to have positive hepatitis E virus IgM antibodies and a high hepatitis E virus viral load. Less than 1 month after starting treatment with

**Figure 1. Mild inflammatory cell infiltrate of portal tracts, interface hepatitis and significant fibrosis.**



**Dr Shahana Shahid**, Gastroenterology Registrar, Gastroenterology Office, Wycombe Hospital, Buckinghamshire Healthcare NHS Trust, High Wycombe HP11 2TT

**Dr Sabina Rait**, Consultant, Department of Histopathology, Buckinghamshire Healthcare NHS Trust, High Wycombe

**Dr Edward Sharples**, Renal Physician, Churchill Hospital, Oxford Kidney Unit and Oxford Transplant Centre, Oxford

**Dr David Gorard**, Consultant, Department of Gastroenterology, Buckinghamshire Healthcare NHS Trust, High Wycombe

Correspondence to: Dr S Shahid (Shahana.shahid@doctors.org.uk)

ribavirin the patient's liver biochemistry returned to normal and after completing 14 weeks of treatment with ribavirin his viral load became undetectable by polymerase chain reaction.

This case highlights that in immunocompromised individuals, including transplant recipients on

immunosuppressive therapy, hepatitis E virus can cause chronic infection progressing to fibrosis and advanced liver disease. Gastroenterologists and physicians caring for solid organ transplant recipients and other immunocompromised patients need to be aware of the entity of chronic hepatitis E virus infection.

## CASE REPORT

A 67-year-old man was referred to the gastroenterology clinic with several months of a persistently elevated alanine aminotransferase level of 150–250 U/litre (normal range 10–35 U/litre). He had received a renal transplant for adult polycystic kidney disease 2 years earlier, and there were no liver biochemical abnormalities in the first year after transplantation. He reported extreme fatigue as his only symptom and denied abdominal pain, jaundice or any previous history of liver disease. His other health problems included hypertension, hypothyroidism and prostatectomy for prostate cancer. His medication included mycophenolate 500 mg twice daily, tacrolimus 1 mg twice daily, bisoprolol, aspirin and levothyroxine. A trial of immunosuppressant dose reduction did not improve his transaminitis. He did not drink alcohol and denied using any over-the-counter or herbal medications. He had no family history of liver disease.

Clinical examination revealed no stigmata of chronic liver disease; abdominal examination revealed his palpable polycystic kidneys and transplanted kidney in the left iliac fossa.

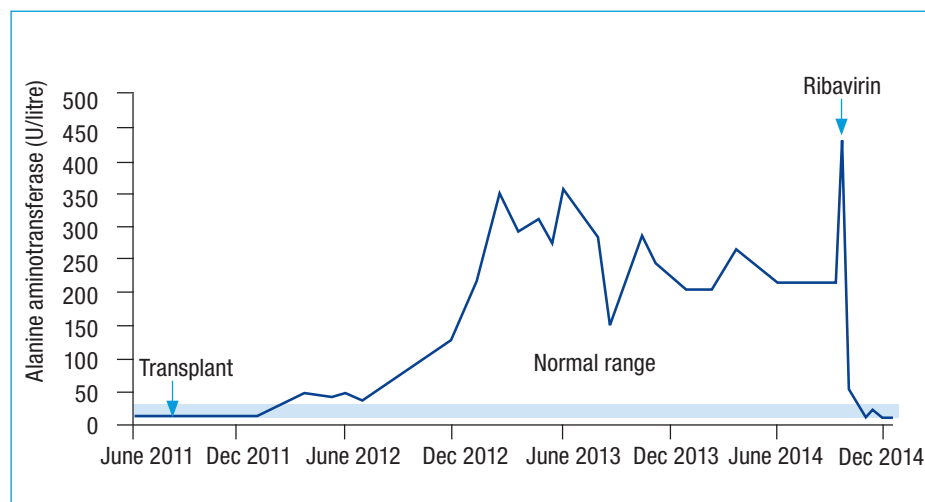
Blood tests showed alanine aminotransferase levels of 284 U/litre and levels of this liver enzyme remained elevated between 150 and 350 U/litre for the next year. Serum albumin, bilirubin and alkaline phosphatase levels were persistently normal. An ultrasound scan showed the presence of multiple liver cysts in keeping with adult polycystic kidney disease. A magnetic resonance imaging scan of the liver again demonstrated multiple liver cysts and showed no evidence of bile duct calculi.

Serological tests for hepatitis B, hepatitis C, autoimmune liver disease and coeliac disease were all negative. Serum concentrations of immunoglobulins, alpha-1-antitrypsin and ferritin were all normal. Since his transaminitis persisted, a liver biopsy was arranged and showed mild inflammatory cell infiltrate of the portal tracts with some interface hepatitis and significant fibrosis (Ishak fibrosis stage 3/6) (Figure 1).

It was initially believed that although rare, the underlying polycystic disease might account for the changes seen on the liver biopsy. However, the patient was subsequently tested for hepatitis E virus, which is usually perceived as a rare cause of acute hepatitis in the west. Hepatitis E virus IgM antibody was positive. Subsequent polymerase chain reaction testing was positive, identifying the circulating RNA virus as genotype 3, with a viral load of 900 000 iu/ml.

The patient was prescribed the antiviral drug ribavirin 400 mg morning, 600 mg evening. To lessen immunosuppression, the mycophenolate dose was reduced from 500 mg to 250 mg twice daily. Within 3 weeks of starting ribavirin, his alanine aminotransferase levels normalized and his viral load reduced to 240 000 iu/ml. His viral load became undetectable after 14 weeks of treatment at which point ribavirin was stopped. During the last month of treatment he developed symptomatic anaemia, with haemoglobin falling from 144 to 93 g/litre, requiring a reduction in the ribavirin dose to 400 mg twice daily and administration of erythropoietin injections. Viral clearance and alanine aminotransferase normalization coincided with a resolution of his fatigue (Figure 2).

Figure 2. Liver transaminitis preceding diagnosis and response to treatment.



## LEARNING POINTS

- In immunocompromised individuals, including transplant recipients on immunosuppressive therapy, hepatitis E virus can cause chronic infection.
- Chronic hepatitis E virus infection should now be considered as a cause of abnormal liver biochemistry in immunosuppressed patients.
- Chronic infection with hepatitis E virus can lead to the development of advanced liver disease.
- Ribavirin treatment can lead to a sustained virological response.

## Discussion

There are multiple causes of deranged liver function tests after organ transplantation including drugs, de novo viral infection and reactivation of latent hepatitis B. This patient's transaminitis persisted despite reduction in levels of immunosuppression. Hepatitis E virus was tested for to exclude more unusual causes of a persistent transaminitis. Chronic hepatitis E virus infection should now also be considered as a cause of abnormal liver biochemistry in an immunosuppressed patient.

Hepatitis E virus is a single-stranded RNA virus transmitted via the faecal-oral route, and has four genotypes. Genotypes 1, 2 and 4 are more common in Asia and Africa and can cause outbreaks via contaminated water. Genotype 3 is found worldwide including Europe and is usually transmitted through contaminated food intake, giving rise to sporadic cases. The virus is found in animals such as pigs and zoonotic transmission results from eating undercooked pork. There have been reports of hepatitis E virus transmission in blood products and in the setting of transplant via the transplanted organ itself (Behrendt et al, 2014; Kamar et al, 2014a).

In immunocompetent individuals, acute hepatitis E virus infection is usually asymptomatic – in the UK the seroprevalence of hepatitis E virus IgG antibodies in blood donors is 3.6–16.2% (Behrendt et al, 2014). Fewer than 10% of acute infections lead to a self-resolving hepatitis illness with or without jaundice. This usually follows an incubation period of 2–8 weeks and symptoms usually resolve within 6 weeks with complete viral

clearance. Fulminant disease rarely develops but pregnant women and patients with underlying liver disease are at higher risk. Overall mortality from hepatitis E virus is 1% but this increases up to 25% in pregnant women (Behrendt et al, 2014; Kamar et al, 2014a).

In immunocompromised individuals including immunosuppressed transplant recipients, patients with HIV or haematological malignancy, hepatitis E virus can cause a chronic hepatitis, rapidly leading to liver fibrosis with development of end-stage liver disease. In transplant recipients on immunosuppressants, hepatitis E virus can cause a chronic hepatitis in more than 60% of infected patients (viraemia persisting after 6 months) as a result of an impaired immune response to the virus (Behrendt et al, 2014; Fujiwara et al, 2014). This is likely secondary to abnormal T-cell response to the virus as supported by chronic hepatitis E virus in HIV patients with low CD4 counts (Kamar et al, 2008).

Although active hepatitis E virus infection is usually detected by hepatitis E virus IgM antibody testing, impaired immune function can make such serological testing unreliable in immunosuppressed patients, and so diagnosis is more reliably made by detecting and measuring hepatitis E virus-RNA via polymerase chain reaction. Chronic hepatitis E virus in solid organ transplant recipients is invariably genotype 3 (Zhou et al, 2013; Fujiwara et al, 2014).

Management of chronic hepatitis E virus infection in the transplant recipient involves cautious reduction of immunosuppressants

while monitoring for and balancing the risk of transplant organ rejection. Hepatitis E virus clearance can occur after reduction of immunosuppressants, notably tacrolimus, in up to 30% of patients (Fujiwara et al, 2014; Kamar et al, 2014b). Antiviral therapy involving ribavirin monotherapy has been shown to be effective in treatment of hepatitis E virus infection. A sustained virological response was achieved in 78% of infected transplant recipients after a median of 3 months treatment. Anaemia is the most common side effect of ribavirin treatment and can require dose reduction or treatment cessation (Kamar et al, 2014b). **BJHM**

- Behrendt P, Steinmann E, Manns MP, Wedemeyer H (2014) The impact of hepatitis E in the liver transplant setting. *J Hepatol* **61**(6): 1418–1429. <https://doi.org/10.1016/j.jhep.2014.08.047>
- Fujiwara S, Yokokawa Y, Morino K, Hayasaka K, Kawabata M, Shimizu T (2014) Chronic hepatitis E: a review of the literature. *J Viral Hepat* **21**(2): 78–89. <https://doi.org/10.1111/jvh.12156>
- Kamar N, Selves J, Mansuy JM et al (2008) Hepatitis E virus and chronic hepatitis in organ-transplant recipients. *N Engl J Med* **358**(8): 811–817. <https://doi.org/10.1056/NEJMoa0706992>
- Kamar N, Dalton HR, Abravanel F, Izopet J (2014a) Hepatitis E virus infection. *Clin Microbiol Rev* **27**(1): 116–138. <https://doi.org/10.1128/CMR.00057-13>
- Kamar N, Izopet J, Tripot S et al (2014b) Ribavirin for chronic hepatitis E virus infection in transplant recipients. *N Engl J Med* **370**: 1111–1120. <https://doi.org/10.1056/NEJMoa1215246>
- Zhou X, de Man RA, de Knegt RJ, Metselaar HJ, Peppelenbosch MP, Pan Q (2013) Epidemiology and management of chronic hepatitis E infection in solid organ transplantation: a comprehensive literature review. *Rev Med Virol* **23**(5): 295–304. <https://doi.org/10.1002/rmv.1751>