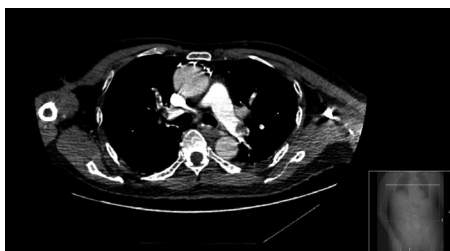

An unusual presentation of silent pulmonary embolism

Introduction

Neutrophilia is a marker of inflammation most commonly caused by bacterial infection. This article presents a case where persistent neutrophilia was the only indication of an underlying diagnosis of pulmonary embolism. It was an incidental finding on computed tomography of the urinary tract that highlighted a suspicious nodule in the lower lobe of the right lung. Further investigation of this nodule led to the discovery of extensive pulmonary embolism on computed tomography of the chest. After commencing rivaroxaban, the neutrophilia that had lasted for more than 3 weeks rapidly resolved, and subsequently diagnosed deep vein thromboses were appropriately treated. Although an unusual presentation, pulmonary embolism should be considered in any patient with a persistent neutrophilia for whom an underlying infective cause cannot be found.

Figure 1. Computed tomography showing embolism of the left main pulmonary artery and right upper pulmonary arteries.



Dr Victoria Jenkins, FY1 Doctor, Department of Geriatric Medicine, Queens Hospital, Barking Havering and Redbridge University Hospitals NHS Trust, London RM7 OAG

Dr Trevor Gaunt, Specialist Registrar in Clinical Radiology, Department of Radiology, Norfolk and Norwich University Hospitals NHS Foundation Trust, Norwich

Dr Gursharan Bawa, Consultant in Anaesthesia and Intensive Care Medicine, Department of Anaesthesia, Barking Havering and Redbridge University Hospitals NHS Trust, London

Correspondence to: Dr V Jenkins (v.jenkins1@nhs.net)

Discussion

The incidence of pulmonary embolism is reported as up to 1 per 1000 (Konstantinides et al, 2014). One review commented that the actual figures are likely to be much higher because of the phenomenon of silent pulmonary emboli, highlighting a discrepancy between clinical data and autopsy studies, showing over 50% of patients had emboli not diagnosed in life

(Belohlávek et al, 2013). They also note that pulmonary embolism may remain undiagnosed, particularly in the elderly.

In this case, nothing in the clinical presentation indicated pulmonary embolism. A small retrospective study looking at presentations of pulmonary embolism found that more elderly patients presented with collapse rather than the classical symptoms of chest pain and dyspnoea. They also found

CASE REPORT

A 79-year-old man was found on the floor at home following a long lie of 2–3 days. He had a history of Parkinson's disease, hypertension and hypercholesterolaemia. On admission, his observations were all within normal limits: respiratory rate 18 breaths per minute, oxygen saturation 95%, blood pressure 143/89 mmHg, pulse 75 beats per minute. On examination, he had a carpet burn on the sacrum secondary to long lie, a known right-sided inguinal hernia, and cogwheeling and rigidity of the upper limbs with bilateral resting tremor. Respiratory examination was unremarkable.

Admission bloods showed a raised white cell count of 14.2×10^9 /litre with neutrophils 11.4×10^9 /litre. Urea (21.6 mmol/litre), creatinine (115 μ mol/litre) and creatine kinase (4909 U/litre) levels were also elevated. Electrocardiogram showed sinus rhythm, and both chest radiograph and computed tomography head showed no abnormalities.

The initial diagnosis was a fall secondary to Parkinson's disease with subsequent mild rhabdomyolysis for which he was treated with intravenous fluids. However, the patient had persistent neutrophilia, ranging from 7.7 – 18×10^9 /litre with white cells 11.2 – 20.8×10^9 /litre. On day 12 of admission he clinically deteriorated, becoming more confused with pyrexia of 38°C. He was treated for sepsis of unknown origin and commenced on tazocin and amikacin as per hospital protocol. The repeat chest radiograph remained normal, and mid-stream urine and sacral swabs were negative. Blood cultures grew coagulase-negative staphylococcus, presumed to be a contaminant, but antibiotics were switched to teicoplanin on the advice of microbiology. He slowly began to

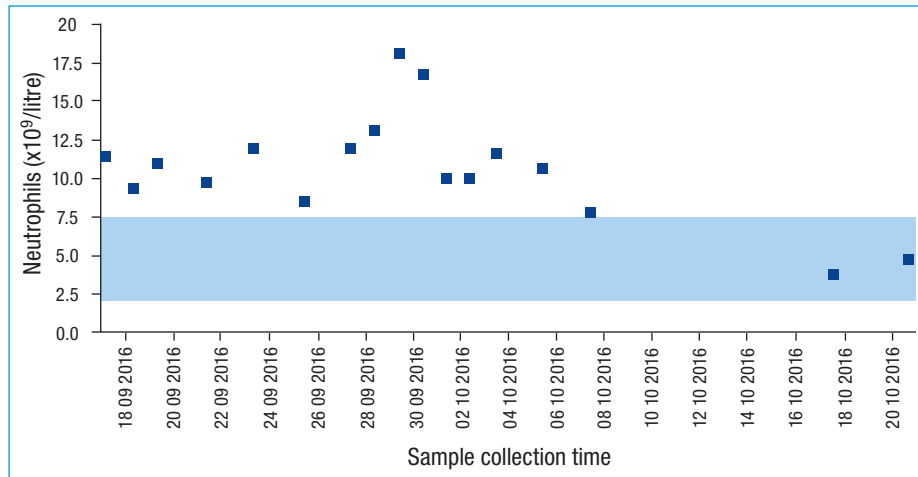
improve clinically, but neutrophils as well as other inflammatory markers remained elevated, including C-reactive protein 76–160 mg/litre.

The patient was then found to be in urinary retention. The prostate-specific antigen level was raised at 42.5 μ g/litre and ultrasound measured the prostate at 134 cc. Computed tomography of the urinary tract revealed an incidental 12 mm soft tissue density nodule in the lower lobe of the right lung. Computed tomography chest was suggested to clarify the nature of the nodule, which was found to be a prominent pulmonary arterial branch. However, there were also multiple defects in the left pulmonary artery, extending into the lower lobar segmental branches (Figure 7). Pulmonary embolus had developed despite enoxaparin thromboprophylaxis given for reduced mobility while in hospital. The patient was started on lifelong rivaroxaban on the advice of haematology.

The next day, the patient reported a painful right leg. On examination the calf was tender, red and swollen. There was no previous documentation of examination of his calves. Ultrasound Doppler showed a deep vein thrombosis completely occluding the external iliac vein of the right leg with post-thrombotic scarring at the posterior tibial and peroneal veins. It also revealed deep vein thrombosis at the external iliac and common femoral veins in the left leg, again with post-thrombotic scarring and narrowing.

After starting rivaroxaban, the patient's neutrophilia resolved (Figure 2) and his white cell count returned to normal. Further investigations into the raised prostate-specific antigen level and enlarged prostate, including nuclear bone scanning, were normal. He made a good recovery and was transferred for further rehabilitation.

Figure 2. Neutrophil count during admission. Blue band represents laboratory reference range.



that 33% of patients had mild neutrophil leucocytosis (Timmons et al, 2003). This may be secondary to infarction caused by pulmonary embolism (Table 1).

The National Institute for Health and Care Excellence (2016) recommends first using the two-level Wells score to estimate clinical probability of pulmonary embolism, then if high to perform immediate computed tomography pulmonary angiogram. A meta-analysis of 1250 patients showed the sensitivity and specificity of computed tomography pulmonary angiogram in detection of pulmonary embolism to be 74–90% and 68–100% respectively (Safriel and Zinn, 2002). However, this depends on adequate opacification of pulmonary vasculature, which in turn depends on chronicity of the embolism. The mean attenuation of acute pulmonary embolism is 33 HU, lower than that of chronic pulmonary embolism at approximately 90 HU (Wittram et al, 2005). Based on simulated lesions (Meaney et al, 1980), the minimum opacification of adjacent vessel should be 211 HU to detect all acute and chronic emboli (Wittram, 2007). Anything below is considered suboptimal and indeterminate, prompting consideration of repeat computed tomography pulmonary angiogram or ventilation–perfusion scintigraphy.

Elderly patients are not only at high risk of pulmonary embolism, but also at high risk of adverse clinical outcomes (Robert-Ebadi and Righini, 2014). The diagnostic process itself is not without adverse effects – computed tomography pulmonary angiogram exposes aged kidneys to nephrotoxic contrast media and high levels of radiation. However, for patients with persistent neutrophilia,

investigations to exclude pulmonary embolism could provide the critical diagnosis and allow potential prevention of further life-threatening emboli. **BJHM**

Belohlávek J, Dytrych V, Linhart A (2013) Pulmonary embolism, part I: Epidemiology, risk factors and risk stratification, pathophysiology, clinical presentation, diagnosis and nonthrombotic pulmonary embolism. *Exp Clin Cardiol* **18**(2): 129–138.

Konstantinides SV, Torbicki A, Agnelli G et al; The Task Force for the Diagnosis and Management of Acute Pulmonary Embolism of the European Society of Cardiology (ESC) (2014) ESC Guidelines on the diagnosis and management of acute pulmonary embolism. *Eur Heart J* **35**(43): 3033–3069, 3069a–3069k. <https://doi.org/10.1093/eurheartj/ehu283>

Meaney TF, Raudkivi U, McIntyre WJ, Gallagher JH, Haaga JR, Havrilla TR, Reich NE (1980) Detection of low-contrast lesions in computed body tomography: an experimental study of simulated lesions. *Radiology* **134**(1): 149–154. <https://doi.org/10.1148/radiology.134.1.7350595>

National Institute for Health and Care Excellence. (2016) Diagnosing venous thromboembolism in primary, secondary and tertiary care. <http://pathways.nice.org.uk/pathways/venous-thromboembolism> (accessed 23 April 2017)

Provan D, Baglin T, Dokal I, de Vos J (2015) *Oxford Handbook of Clinical Haematology*. Oxford University Press, New York: 114–115.

Robert-Ebadi H, Righini M (2014) Diagnosis and management of pulmonary embolism in the elderly. *Eur J Intern Med* **25**(4): 343–349. <https://doi.org/10.1016/j.ejim.2014.03.009>

Safriel Y, Zinn H (2002) CT pulmonary angiography in the detection of pulmonary emboli. *Clin Imaging* **26**(2): 101–105. [https://doi.org/10.1016/S0899-7071\(01\)00366-7](https://doi.org/10.1016/S0899-7071(01)00366-7)

Timmons S, Kingston M, Hussain M, Kelly H, Liston R (2003) Pulmonary embolism: differences in presentation between older and younger patients. *Age Ageing* **32**(6): 601–605. <https://doi.org/10.1093/ageing/afg098>

Wittram C (2007) How I do it: CT pulmonary angiography. *AJR AM J Roentgenol* **188**(5): 1255–1261. <https://doi.org/10.2214/AJR.06.1104>

Wittram C, Maher MM, Halpern EF, Shepard JA (2005) Attenuation of acute and chronic pulmonary emboli. *Radiology* **235**(3): 1050–1054. <https://doi.org/10.1148/radiol.2353040387>

LEARNING POINTS

- Elderly patients have atypical presentations.
- When a patient has a persistent neutrophilia with no evidence of infection, venous thromboembolism is an important differential to consider.
- Pulmonary emboli in the elderly are often a difficult and underdiagnosed condition as their symptoms may overlap with other cardiopulmonary conditions prevalent in this population such as cardiac failure or pneumonias.

Table 1. Causes of neutrophilia (>7.5x10⁹/litre)

Infection	Acute
	Chronic
Inflammation	Trauma
	Infarction (secondary to arterial or venous thromboembolism)
	Vasculitis
	Pancreatitis
Drugs	Rheumatoid disease
	Burns
	Adrenaline
Physiological	Corticosteroids
	Granulocyte colony-stimulating factor, granulocyte-macrophage colony-stimulating factor
	Labour
	Surgery
	Anaesthesia
Haematological	Cold/heat
	Exercise
	Stress
	Cigarette smoking
Malignancy	Myeloproliferative disease
	Chronic myeloid leukaemia
	Post-splenectomy
	Chronic bleeding
From Provan et al (2015)	