

An unusual cause of a postpartum headache

A 38-year-old woman, 10 days postpartum, presented with a severe fronto-occipital headache, which was subacute in onset, increasing in severity and not resolving with simple analgesics. Although she had a history of migraines, this headache was different and she denied any photophobia, neck stiffness or any other associated symptoms. Clinical examination was normal, except for hypertension (blood pressure 165/96 mmHg). Unenhanced computed tomography of the brain was normal and a computed tomography venogram excluded a venous sinus thrombosis. A lumbar puncture revealed a normal white cell count and was negative for xanthochromia. Her headaches and hypertension persisted. Her urine dipstick was negative for proteinuria. A magnetic resonance imaging scan of the brain (**Figure 1**) was performed, which showed changes consistent with posterior reversible encephalopathy syndrome.

She was commenced on antihypertensives (initially intravenous, then oral, labetalol and amlodipine) and secondary causes of hypertension were excluded. Her headaches settled and her antihypertensives were weaned off subsequently in outpatients. Follow-up magnetic resonance imaging of the brain 6 weeks later (**Figure 2**) showed resolution of the changes.

Author details

¹Department of Medicine, Mayo University Hospital, Castlebar, Ireland

²Department of Radiology, Mayo University Hospital, Castlebar, Ireland

BJ Renton¹

A Shahid¹

MN Nasir¹

P Dixon¹

AM Browne²

Author details can be found at the end of this article

Correspondence to:

BJ Renton;
bryan.renton@hse.ie

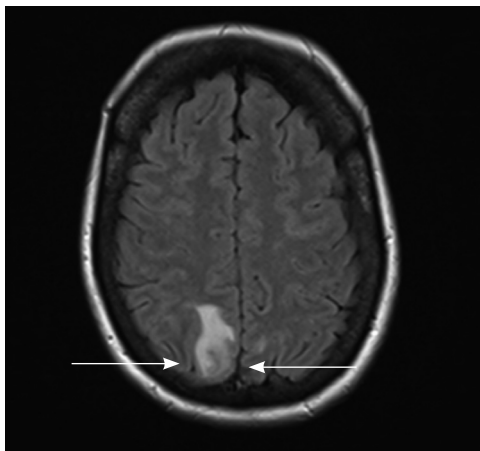


Figure 1. Magnetic resonance imaging of the brain demonstrating a confluent FLAIR signal abnormality within the posterior right frontal lobe with a tiny amount of FLAIR hyperintensity present within the posterior left frontal lobe, consistent with posterior reversible encephalopathy syndrome.

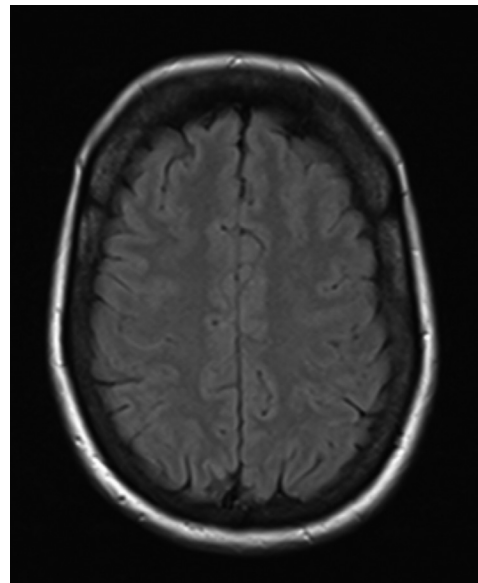


Figure 2. Magnetic resonance imaging scan of the brain illustrating resolution of the changes.

How to cite this article:

Renton BJ, Shahid A, Nasir MN, Dixon P, Browne AM. An unusual cause of a postpartum headache. *Br J Hosp Med.* 2021. <https://doi.org/10.12968/hmed.2019.0331>