

Degenerative meniscal tears of the knee: evaluation and management

ABSTRACT

Meniscal injuries are among the most common orthopaedic injuries seen in knee clinics. Meniscal tears can occur as a result of acute injuries or chronic degeneration. However, the exact incidence of meniscal tears is difficult to ascertain because of the high number of asymptomatic tears and the high rate of degenerative tears in patients with advanced degenerative joint disease. The management of patients with knee pain is non-operative both for degenerative meniscal tears and degenerative joint disease in its initial stages. Magnetic resonance imaging has little added value in the management of middle-aged and elderly patients with degenerative disease. Failure to respond to non-operative measures warrants orthopaedic assessment with radiographic studies and counselling on managing degenerative joint disease both non-operatively and operatively. This article focuses on assessment and management of degenerative meniscal tears.

Meniscal injuries are among the most common orthopaedic injuries seen in knee clinics. Meniscal tears can occur as a result of acute injuries or chronic degeneration. However, the exact incidence of meniscal tears is difficult to ascertain because of the high number of asymptomatic tears and the high rate of degenerative tears in patients with advanced degenerative joint disease. This article focuses on assessment and management of degenerative meniscal tears.

Anatomy and function

The menisci are wedge-shaped and semilunar tissues anchored within the medial and lateral sides of the knee joint by a network of ligaments. They play an important role in increasing the congruence between the articulating femoral condyle and tibial plateau, stabilizing joint movement, and distributing joint loads. Loss or injury of the meniscus leads to alterations in joint loading as well as local biochemical alterations that are strongly associated with joint degeneration and osteoarthritis

Mr Hosam E Matar, Specialty Registrar in Trauma and Orthopaedics, Department of Orthopaedic Surgery, Wrightington Hospital, Wigan WN6 9EP

Mr Stephen P Duckett, Consultant Trauma and Orthopaedic Surgeon, Department of Orthopaedic Surgery, Leighton Hospital, Crewe

Professor Videshnandan Raut, Honorary Professor Edge Hill University, and Consultant Hip and Knee Orthopaedic Surgeon, Department of Orthopaedic Surgery, Wrightington and Lancashire Teaching Hospitals, Wigan

Correspondence to: Mr HE Matar (hematar@doctors.org.uk)

(Englund et al, 2009a). The medial and lateral menisci are joined together by the transverse meniscal ligament, and each meniscus is anchored to the tibial plateau via anterior and posterior meniscal horns. In turn, these horns connect the meniscus to the underlying bone, maintaining its position within the joint. The insertion sites of the horns are highly innervated. When first formed in the body, both menisci are completely vascular and have a high degree of cellularity. This vascularity diminishes towards adulthood leaving only a third of the peripheral menisci with blood supply (Arnoczky and Warren, 1982); this zone is also innervated circumferentially (Verdonk et al, 2005).

During normal daily activities such as walking or ascending stairs, the knee joint experiences loads of up to five times body weight (Masouros et al, 2008). The menisci bear anywhere from 45% to 75% of this total joint load, varying with the degree of joint flexion and the health of the tissue (Flandry and Hommel, 2011). Further, the menisci also act as spacers to create approximately 1 mm of space between most of the articulating femoral and tibial surfaces and allowing only about 10% of these surfaces to contact. In the absence of a functional meniscus, support of the femoral condyles is dramatically reduced and the joint force is concentrated, increasing the stress on the articular cartilage to two to three times higher than normal (McNulty and Guilak, 2015). Patients with meniscal injuries or following meniscectomies were found to develop signs of osteoarthritis such as articular cartilage fibrillation and erosion, bone remodelling with osteophytes formation, and joint space narrowing (Roos et al, 1998).

Meniscal injury

Meniscal tissue is prone to degenerative changes and with degeneration the meniscus becomes more prone to injury (Englund et al, 2009b). In particular, osteoarthritis can cause widespread degenerative changes in the meniscus as well as the surrounding hyaline cartilage, and has been implicated in promoting meniscal injury. More than 75% of patients with symptomatic osteoarthritis have meniscal injury (Jarraya et al, 2017). Osteoarthritis is also associated with calcification of the meniscus. Further, severe osteoarthritis causes medial joint space narrowing as the medial meniscus displaces radially. This acts to preserve the tissue at the horns slightly, but the load-bearing function of the tissue is lost and widespread meniscal degeneration becomes apparent (Jarraya et al, 2017). Meniscal tears cause symptoms such as locking and catching of the knee, a sensation of giving way, and joint pain. Meniscal tears affect men more often than women, with 70–80% of meniscal

tears occurring in men (Englund et al, 2009a). Traumatic injuries are more common in younger patients, whereas older patients are more prone to degenerative changes. Degenerative (complex) tears describe an overall fraying of the inner meniscal edge consisting of many different types of tears. The medial meniscus is less mobile than the lateral and, consequently, more liable to tearing when subjected to abnormal stresses. Grinding forces split the fibres of the meniscus which are arranged circumferentially (Flandry and Hommel, 2011).

Clinical evaluation

A complete history and clinical examination are essential when evaluating any patient with knee pain and possible meniscal pathology. Patients with meniscal tears typically complain of pain localizing to the joint line, swelling, joint effusion, locking, catching, giving way and reduced range of movement. In a study of the mechanism of meniscal injury in the general population, two thirds of meniscal tears occurred in non-sporting activities (frequently everyday activities such as squatting) and 29% of patients had no identifiable mechanism (Drosos and Pozo, 2004). Specialized clinical examinations for meniscal tears include joint line palpation, McMurray test and the Apley grind test; however, these tests have poor sensitivity, specificity and positive predictive values, especially in isolation. Joint line tenderness with palpation is the most sensitive clinical examination test and has 74% sensitivity (Evans et al, 1993; Hegedus et al, 2007; Smith et al, 2015). Clinical examination should also include a ligamentous examination to assess instability and an examination for degenerative joint disease.

Investigations

Standard knee radiographs should be obtained to evaluate for bone injuries or abnormalities. A weight-bearing radiograph is necessary to evaluate for osteoarthritis, including an anteroposterior or 45° posterioranterior flexion view (Rosenberg view) (Rosenberg et al, 1988; Boegård and Jonsson, 1999). Knee radiographs do not confirm a diagnosis of meniscal tears but are very important in evaluating the knee for joint space narrowing, calcification of the meniscus and degenerative changes.

Magnetic resonance imaging is the diagnostic modality of choice for meniscal pathology and has a high negative predictive value for meniscal tears. Another consideration when evaluating magnetic resonance imaging includes the high rate of positive readings in asymptomatic individuals (LaPrade et al, 1994). Therefore, magnetic resonance imaging should be used as a diagnostic tool to supplement the clinical diagnosis. The menisci are uniformly low in signal on both T1- and T2-weighted sequences. With T2-sequences the menisci may demonstrate some internal signal. However, with T1-weighted images any signal within the meniscus is abnormal in an adult individual (Rosas and De Smet, 2009). Meniscal signal that does not disrupt an articular surface represents intrasubstance degeneration,

“ Patients with meniscal tears typically complain of pain localizing to the joint line, swelling, joint effusion, locking, catching, giving way and reduced range of movement. ”

which is myxoid degeneration of the fibrocartilage. It is not believed to be symptomatic and cannot be diagnosed clinically or with arthroscopy. A true meniscal tear is seen as a linear signal that disrupts the articular surface (Lotysch et al, 1986; Rosas and De Smet, 2009). This distinction forms the basis for the Lotysch grading system (Lotysch et al, 1986) (*Table 1*). Some radiologists may wrongly report grade 1–2 findings as meniscal tear, but only grade 3 represents a tear (*Figure 1*).

The main drawback of magnetic resonance imaging in evaluating meniscal pathology is the high prevalence of positive findings in asymptomatic patients. A large population-based observational study evaluated incidental meniscal findings on knee magnetic resonance imaging in 991 middle-aged and elderly persons. The prevalence of a meniscal tear detected on magnetic resonance imaging ranged from 19% (95% confidence interval 15–24%) among women 50–59 years of age to 56% (95% confidence interval 46–66%) among men 70–90 years of age. In those who had radiographic evidence of osteoarthritis, the prevalence of a meniscal tear was 63% among those with knee pain, aching, or stiffness on most days and 60% among those without these symptoms. The corresponding prevalence among persons without radiographic evidence of osteoarthritis were 32% and 23%. More importantly, however, 61% of subjects who had meniscal tears on magnetic resonance imaging were asymptomatic (Englund et al, 2008).

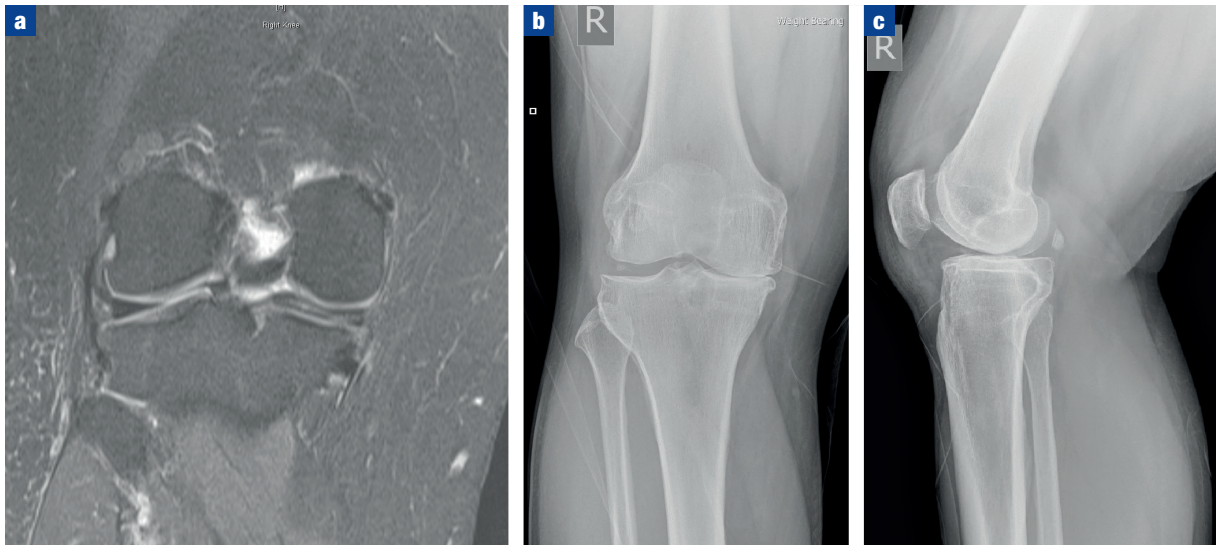
The differential diagnosis for meniscal tears includes intra-articular diagnoses (medial patella plica, patellofemoral pain syndromes, loose bodies, pigmented villonodular synovitis, inflammatory arthropathies or osteonecrosis), and extra-articular diagnoses (bone or soft-tissue tumours, osteomyelitis, synovial cyst, pes anserine or medial collateral ligament bursitis, injury, lumbar radiculopathy, ilio-tibial band friction, and stress fractures).

Table 1. Magnetic resonance imaging classification system of meniscal pathology

Grade	Magnetic resonance imaging finding	Interpretation
Grade 1	Rounded or amorphous signal that does not disrupt an articular surface	Intrasubstance degeneration
Grade 2	Linear signal that does not disrupt an articular surface	Intrasubstance degeneration
Grade 3	Rounded or linear signal that disrupts an articular surface	Meniscal tear

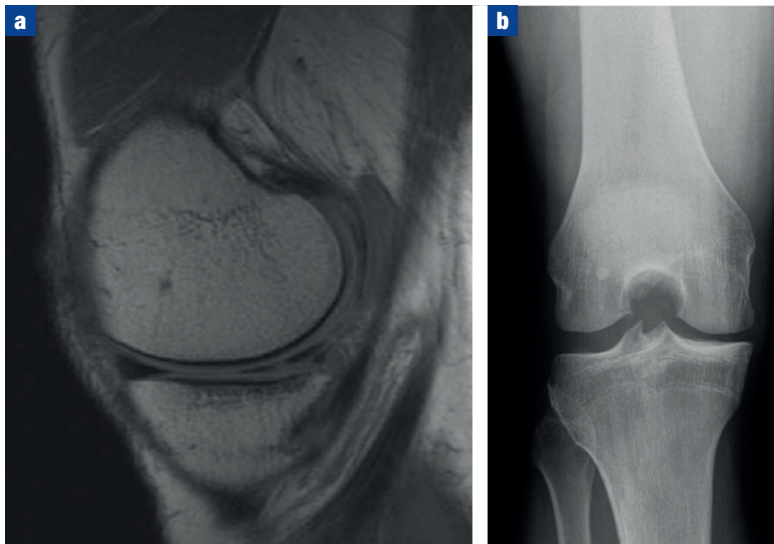
From Lotysch et al (1986)

Figure 1. A 56-year-old man who presented with knee pain affecting the medial side associated with mechanical symptoms of locking and giving way. Magnetic resonance imaging showed a degenerative medial meniscal tear with extruded posterior horn, so he was referred to the knee clinic. Clinical and radiographic assessment confirmed degenerative joint disease. **a.** T2-weighted coronal magnetic resonance imaging of the right knee showing degenerative tear of the medial meniscus with extruded posterior horn. **b** and **c.** Weight-bearing radiographs of the right knee demonstrating advanced arthritis of the medial compartment with complete obliteration of the joint space, sclerosis and osteophyte formation – classic features of advanced degenerative joint disease.



Further, patients may present with knee pain following partial meniscectomy which may be the result of a degenerative re-tear. Magnetic resonance imaging findings of post-surgical menisci are far less accurate with 66–80% sensitivity, substantially below that for primary meniscal tears (92–96%) (Kijowski et al, 2017; Russo et al, 2017).

Figure 2. **a.** T1-weighted sagittal magnetic resonance image of the right knee demonstrating a complex degenerative tear of the posterior horn of the medial meniscus. **b.** Rosenberg radiographic view of the knee (posterioranterior with 45° flexion) is used to detect early signs of osteoarthritis as it allows the tibial plateau and femoral condyles to be free of any superimposition with the intercondylar notch. Here, the medial compartment is affected by early osteoarthritis with joint space narrowing and sclerosis, so the associated meniscal tear is likely to be degenerative.

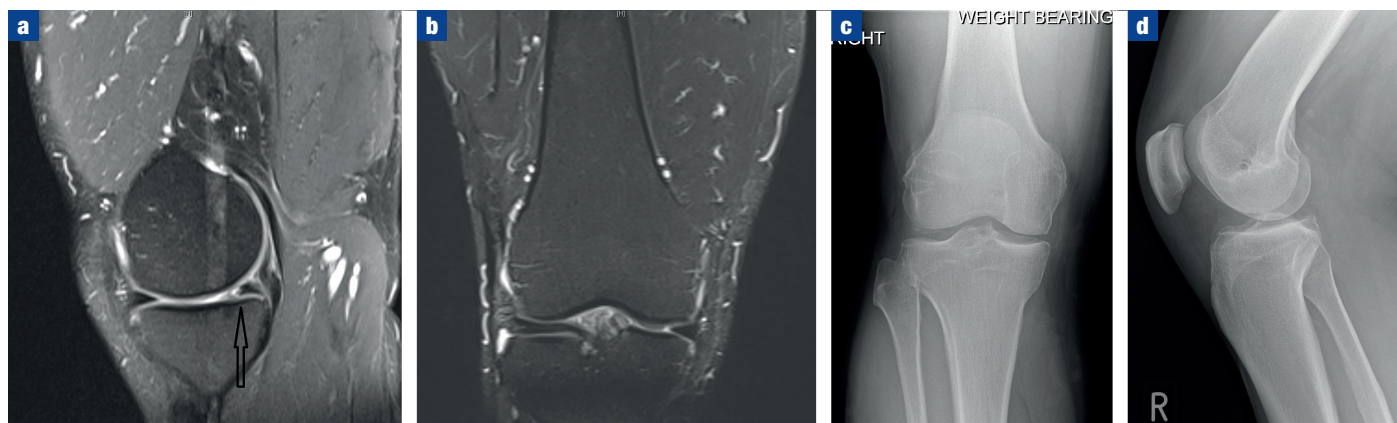


Management of degenerative meniscal tears

The conundrum of degenerative meniscal tears is that a meniscal tear can lead to knee osteoarthritis, but knee osteoarthritis can also lead to a degenerative meniscal tear. Thus, a degenerative meniscal tear often suggests early-stage knee osteoarthritis. Surgical resection of a degenerate tear may merely remove evidence of the disorder while the osteoarthritis and associated symptoms proceed (Englund et al, 2009a). The prevalence of meniscal abnormalities on magnetic resonance imaging increases with age and meniscal tears are systematically associated with knee osteoarthritis (Englund et al, 2008). Therefore, the mainstay of treatment for degenerative meniscal lesions is non-operative including rest, non-steroidal anti-inflammatory medications and physiotherapy. Surgical intervention with arthroscopic partial meniscectomy has been traditionally offered for patients with degenerative meniscal tears and mechanical symptoms who had failed non-operative treatment. However, a number of recent well-conducted high-quality randomized controlled trials have questioned the value of any surgical intervention for degenerative meniscal tears.

Sihvonen et al (2013) conducted a multicentre, randomized, double-blind, sham-controlled trial in 146 patients (35–65 years of age) who had knee symptoms consistent with a degenerative medial meniscus tear and no knee osteoarthritis comparing arthroscopic partial meniscectomy *vs* sham surgery. At 12 months follow up there was no statistically significant difference between the two groups. Moreover, in a subgroup analysis of patients with self-reported mechanical symptoms resection of a

Figure 3. A 42-year-old man with a flap tear of the medial meniscus who presented with locked knee. He underwent arthroscopic partial meniscectomy which led to relief of his symptoms. **a.** T2-weighted sagittal and **(b)** coronal magnetic resonance imaging demonstrating a flap tear of the medial meniscus. **c.** Anteroposterior and **(d)** lateral radiographs of the knee demonstrating mild medial joint space narrowing suggestive of early medial osteoarthritis.



torn meniscus had no added benefit over sham surgery to relieve knee catching or occasional locking (Sihvonen et al, 2016). Similarly, Kise et al (2016) in their randomized controlled trial of 140 patients compared exercise therapy *vs* arthroscopic partial meniscectomy for degenerative meniscal tears in middle-aged patients. They found no clinically relevant difference between the two groups at 2-year follow up, although 19% of the participants allocated to exercise therapy crossed over to surgery during the 2-year follow up, with no additional benefit. Herrlin et al (2007) also compared arthroscopic and non-operative treatment in a randomized trial, and found that 6 months after treatment, arthroscopic partial medial meniscectomy followed by supervised exercise did not result in lower pain and higher knee function compared with supervised exercise alone. In a recent meta-analysis of nine randomized controlled trials comparing arthroscopic meniscal surgery *vs* non-operative management in patients aged 40 years and older, there were no significant differences in clinical outcomes of relief in knee pain or improved knee function (Lee et al, 2018).

Further, in a multicentre longitudinal observational study of risk for knee replacement surgery after arthroscopic surgery for degenerative meniscal tears, 3337 patients were followed up for 9 years. Of these 335 participants underwent arthroscopic meniscectomy during follow up, of which 63 (18.8%) underwent knee replacement surgery in the same knee. Of the 335 propensity score matched participants 38 (11.1%) underwent knee replacement surgery during follow up. In this cohort, patients with knee osteoarthritis arthroscopic knee surgery with meniscectomy is associated with a three-fold increase in the risk for future knee replacement surgery (Rongen et al, 2017).

Moreover, in a randomized controlled trial Kirkley et al (2008) compared arthroscopic surgery in patients with moderate–severe osteoarthritis of the knee. Patients were randomly assigned to surgical lavage and arthroscopic debridement together with optimized physical and

medical therapy or to physical and medical therapy alone. At 2-year follow up, arthroscopic surgery for osteoarthritis of the knee provided no additional benefit to optimized physical and medical therapy. There is strong evidence that arthroscopic debridement with or without meniscectomy in patients with osteoarthritis of the knee or with meniscal injury from degenerative causes has no benefit over non-operative measures (Evidence Development and Standards Branch, Health Quality Ontario, 2014).

Role of surgery

The British Association for Surgery of the Knee has recently published their guidance on managing meniscal lesions based on expert consensus (Abram et al, 2018). Surgery may play a therapeutic role in patients with symptoms strongly suggestive of a treatable meniscal lesion. These are:

1. Locked knee: sudden onset, complete mechanical block to flexion or extension of the knee, detected on clinical examination and which does not resolve despite adequate analgesia
2. Locking: an intermittent block to normal range of movement of the knee (commonly a block to extension) with an associated unlocking movement. Knee returns to near normal after unlocking
3. Catching: the sensation of something intermittently out of place in the knee and interfering with joint movement
4. Tender, palpable meniscal tissue: the finding on clinical examination of a discrete, tender lump, close to the joint line.

Patients presenting with these symptoms may benefit from surgical intervention following formal assessment in the orthopaedic clinic (*Figure 3*).

Conclusions

The management of patients with knee pain is non-operative both for degenerative meniscal tears as well as degenerative joint disease in its initial stages.

KEY POINTS

- Management of degenerative meniscal tears is non-operative.
- Magnetic resonance imaging has little added value in managing patients with degenerative meniscal pathology.
- Surgery may play a role in managing patients with mechanical symptoms with no arthritis such as locking and catching.

Magnetic resonance imaging has little added value in the management of middle-aged and elderly patients with degenerative disease. Failure to respond to non-operative measures or symptoms strongly suggestive of treatable meniscal lesion would warrant orthopaedic assessment with radiographic studies and counselling on managing degenerative joint disease both non-operatively and operatively. **BJHM**

Conflict of interest: none.

- Abram SGF, Beard DJ, Price AJ; BASK Meniscal Working Group. National consensus on the definition, investigation, and classification of meniscal lesions of the knee. *Knee*. 2018 Oct;25(5):834–840. <https://doi.org/10.1016/j.knee.2018.06.001>
- Arnoczky SP, Warren RF. Microvasculature of the human meniscus. *Am J Sports Med*. 1982 Mar;10(2):90–95. <https://doi.org/10.1177/036354658201000205>
- Boegård T, Jonsson K. Radiography in osteoarthritis of the knee. *Skeletal Radiol*. 1999 Nov 12;28(11):605–615. <https://doi.org/10.1007/s002560050561>
- Drosos GI, Pozo JL. The causes and mechanisms of meniscal injuries in the sporting and non-sporting environment in an unselected population. *Knee*. 2004 Apr;11(2):143–149. [https://doi.org/10.1016/S0968-0160\(03\)00105-4](https://doi.org/10.1016/S0968-0160(03)00105-4)
- Englund M, Guermazi A, Gale D, Hunter DJ, Aliabadi P, Clancy M, Felson DT. Incidental meniscal findings on knee MRI in middle-aged and elderly persons. *N Engl J Med*. 2008 Sep 11;359(11):1108–1115. <https://doi.org/10.1056/NEJMoa0800777>
- Englund M, Guermazi A, Lohmander LS. The meniscus in knee osteoarthritis. *Rheum Dis Clin North Am*. 2009a Aug;35(3):579–590. <https://doi.org/10.1016/j.rdc.2009.08.004>
- Englund M, Guermazi A, Lohmander SL. The role of the meniscus in knee osteoarthritis: a cause or consequence? *Radiol Clin North Am*. 2009b Jul;47(4):703–712. <https://doi.org/10.1016/j.rcl.2009.03.003>
- Evans PJ, Bell GD, Frank CY. Prospective evaluation of the McMurray test. *Am J Sports Med*. 1993 Jul;21(4):604–608. <https://doi.org/10.1177/036354659302100420>
- Evidence Development and Standards Branch, Health Quality Ontario. Arthroscopic Debridement of the Knee: An Evidence Update. *Ont Health Technol Assess Ser*. 2014 Nov 1;14(13):1–43.
- Flandry F, Hommel G. Normal anatomy and biomechanics of the knee. *Sports Med Arthrosc Rev*. 2011 Jun;19(2):82–92. <https://doi.org/10.1097/JSA.0b013e318210c0aa>
- Hegedus EJ, Cook C, Hasselblad V, Goode A, Mccrory DC. Physical examination tests for assessing a torn meniscus in the knee: a systematic review with meta-analysis. *J Orthop Sports Phys Ther*. 2007 Sep;37(9):541–550. <https://doi.org/10.2519/jospt.2007.2560>
- Herrlin S, Hallander M, Wange P, Weidenhielm L, Werner S. Arthroscopic or conservative treatment of degenerative medial meniscal tears: a prospective randomised trial. *Knee Surg Sports Traumatol Arthrosc*. 2007 Apr;15(4):393–401. <https://doi.org/10.1007/s00167-006-0243-2>
- Jarraya M, Roemer FW, Englund M et al. Meniscus morphology: does tear type matter? A narrative review with focus on relevance for osteoarthritis research. *Semin Arthritis Rheum*. 2017 Apr;46(5):552–561. <https://doi.org/10.1016/j.semarthrit.2016.11.005>
- Kijowski R, Rosas H, Williams A, Liu F. MRI characteristics of torn and unrotated post-operative menisci. *Skeletal Radiol*. 2017 Oct;46(10):1353–1360. <https://doi.org/10.1007/s00256-017-2695-5>
- Kirkley A, Birmingham TB, Litchfield RB et al. A randomized trial of arthroscopic surgery for osteoarthritis of the knee. *N Engl J Med*. 2008 Sep 11;359(11):1097–1107. <https://doi.org/10.1056/NEJMoa0708333>
- Kise NJ, Risberg MA, Stensrud S, Ranstam J, Engebretsen L, Roos EM. Exercise therapy versus arthroscopic partial meniscectomy for degenerative meniscal tear in middle aged patients: randomised controlled trial with two year follow-up. *BMJ*. 2016 Jul 20;354:i3740. <https://doi.org/10.1136/bmj.i3740>
- LaPrade RF, Burnett QM 2nd, Veenstra MA, Hodgman CG. The prevalence of abnormal magnetic resonance imaging findings in asymptomatic knees. With correlation of magnetic resonance imaging to arthroscopic findings in symptomatic knees. *Am J Sports Med*. 1994 Nov;22(6):739–745. <https://doi.org/10.1177/036354659402200603>
- Lee DY, Park YJ, Kim HJ, Nam DC, Park JS, Song SY, Kang DG. Arthroscopic meniscal surgery versus conservative management in patients aged 40 years and older: a meta-analysis. *Arch Orthop Trauma Surg*. 2018 Jul 4. <https://doi.org/10.1007/s00402-018-2991-0>
- Lotysch M, Mink J, Crues JV, Schwartz SA. Magnetic resonance imaging in the detection of meniscal injuries. *Magn Reson Imaging*. 1986 Jan;4(2):185. [https://doi.org/10.1016/0730-725X\(86\)91028-3](https://doi.org/10.1016/0730-725X(86)91028-3)
- Masouros SD, McDermott ID, Amis AA, Bull AM. Biomechanics of the meniscus-meniscal ligament construct of the knee. *Knee Surg Sports Traumatol Arthrosc*. 2008 Dec;16(12):1121–1132. <https://doi.org/10.1007/s00167-008-0616-9>
- McNulty AL, Guilak F. Mechanobiology of the meniscus. *J Biomech*. 2015 Jun;48(8):1469–1478. <https://doi.org/10.1016/j.jbiomech.2015.02.008>
- Rongen JJ, Rovers MM, van Tienen TG, Buma P, Hannink G. Increased risk for knee replacement surgery after arthroscopic surgery for degenerative meniscal tears: a multi-center longitudinal observational study using data from the osteoarthritis initiative. *Osteoarthritis Cartilage*. 2017 Jan;25(1):23–29. <https://doi.org/10.1016/j.joca.2016.09.013>
- Roos H, Laurén M, Adalberth T, Roos EM, Jonsson K, Lohmander LS. Knee osteoarthritis after meniscectomy: prevalence of radiographic changes after twenty-one years, compared with matched controls. *Arthritis Rheum*. 1998;41(4):687–693. [https://doi.org/10.1002/1529-0131\(199804\)41:4<687::AID-ART16>3.0.CO;2-2](https://doi.org/10.1002/1529-0131(199804)41:4<687::AID-ART16>3.0.CO;2-2)
- Rosas HG, De Smet AA. Magnetic resonance imaging of the meniscus. *Top Magn Reson Imaging*. 2009 Jun;20(3):151–173. <https://doi.org/10.1097/RMR.0b013e3181d657d1>
- Rosenberg TD, Paulos LE, Parker RD, Coward DB, Scott SM. The forty-five-degree posteroanterior flexion weight-bearing radiograph of the knee. *J Bone Joint Surg Am*. 1988 Dec;70(10):1479–1483. <https://doi.org/10.2106/00004623-198870100-00006>
- Russo A, Capasso R, Varelli C et al. MR imaging evaluation of the postoperative meniscus. *Musculoskelet Surg*. 2017 Mar;101(S1 Suppl 1):37–42. <https://doi.org/10.1007/s12306-017-0454-3>
- Sihvonen R, Paavola M, Malmivaara A et al; Finnish Degenerative Meniscal Lesion Study (FIDELITY) Group. Arthroscopic partial meniscectomy versus sham surgery for a degenerative meniscal tear. *N Engl J Med*. 2013 Dec 26;369(26):2515–2524. <https://doi.org/10.1056/NEJMoa1305189>
- Sihvonen R, Englund M, Turkiewicz A, Järvinen TLN; Finnish Degenerative Meniscal Lesion Study Group. Mechanical symptoms and arthroscopic partial meniscectomy in patients with degenerative meniscus tear. *Ann Intern Med*. 2016 Apr 05;164(7):449–455. <https://doi.org/10.7326/M15-0899>
- Smith BE, Thacker D, Crewsmith A, Hall M. Special tests for assessing meniscal tears within the knee: a systematic review and meta-analysis. *Evid Based Med*. 2015 Jun;20(3):88–97. <https://doi.org/10.1136/ebmed-2014-110160>
- Verdonk PCM, Forsyth RG, Wang J, Almqvist KF, Verdonk R, Veys EM, Verbruggen G. Characterisation of human knee meniscus cell phenotype. *Osteoarthritis Cartilage*. 2005 Jul;13(7):548–560. <https://doi.org/10.1016/j.joca.2005.01.010>