

# Epistaxis from ruptured pseudoaneurysm of the internal carotid artery

**A** 49-year-old woman with a history of nasopharyngeal cancer, who had undergone a full-course of radiotherapy 10 years ago, presented to the authors' hospital with a 1-day history of epistaxis. Physical examination showed bleeding from the nose, but no active bleeding was found via a nasoscope. Computed tomography angiography revealed extravasation of contrast medium mainly from the left petrous internal carotid artery into the left sphenoid sinus, so intra-arterial embolization of the internal carotid artery was carried out (*Figure 1*). She was discharged without any neurological deficits on the 11th day.

Nasopharyngeal cancer is a common malignancy in south Asia. Radiation-induced pseudoaneurysm of the internal carotid artery is a rare but life-threatening disease. Conventional angiography is the gold standard for diagnosis. Endovascular trapping of the internal carotid artery and pseudoaneurysm using coils, glue or detachable balloons has been reported

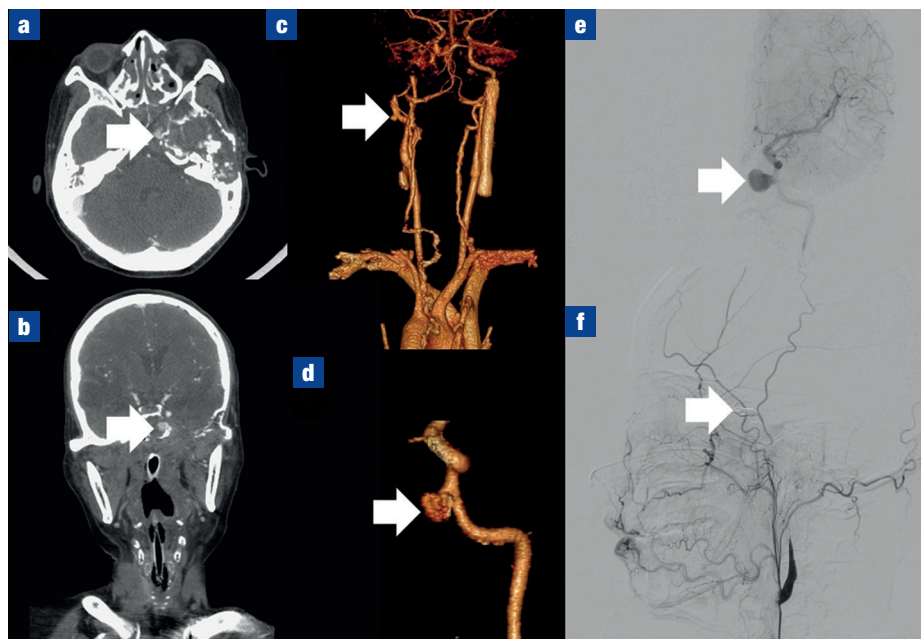
(Zussman et al, 2012), which offers immediate haemostasis (100%) and a low re-rupture rate (7%) for ruptured radiation-induced pseudoaneurysm (Mak et al, 2013; Wan et al, 2013). **BJHM**

Mak CH, Cheng KM, Cheung YL, Chan CM. Endovascular treatment of ruptured internal carotid artery pseudoaneurysms after irradiation for nasopharyngeal carcinoma patients. *Hong Kong Med J*. 2013 Jun;19(3):229–236. <https://doi.org/10.12809/hkmj133833>.

Wan WS, Lai V, Lau HY, Wong YC, Poon WL, Tan CB. Endovascular treatment paradigm of carotid blowout syndrome: review of 8-years experience. *Eur J Radiol*. 2013 Jan;82(1):95–99. <https://doi.org/10.1016/j.ejrad.2011.01.061>

Zussman B, Gonzalez LF, Dumont A et al. Endovascular management of carotid blowout. *World Neurosurg*. 2012 Jul;78(1-2):109–114. <https://doi.org/10.1016/j.wneu.2011.08.024>

**Figure 1. a.** Axial computed tomography scan showing contrast medium extravasation mainly from the left petrous part of the internal carotid artery into the left sphenoid sinus (arrow). **b.** Coronal computed tomography scan showing a blow out with active bleeding from the left petrous part of the internal carotid artery (arrow). **c.** Reconstruction image of computed tomography angiography showing pseudoaneurysm (arrow) from the left petrous part of the internal carotid artery. **d.** Magnified image of pseudoaneurysm (arrow). **e.** Digital subtraction angiography of the left internal carotid artery and common carotid artery demonstrating pseudoaneurysm from the left petrous part of the internal carotid artery (arrow). **f.** Digital subtraction angiography of the right vertebral artery showing collateral circulation to the left middle cerebral artery territory via the posterior communicating artery and intra-arterial coils (arrow).



**Dr Chin-Lung Cheng**, Resident, Department of Emergency Medicine, Kaohsiung Armed Forces General Hospital, Kaohsiung, Taiwan

**Dr Bor-Jen Lee**, Consultant, Department of Critical Care Medicine, Taichung Veterans General Hospital, Taichung, Taiwan

**Dr Wen-Hsien Chen**, Consultant, Department of Radiology, Taichung Veterans General Hospital, Taichung, Taiwan

**Dr Sung-Yuan Hu**, Consultant, Department of Emergency Medicine, Taichung Veterans General Hospital, Taichung, Taiwan

Correspondence to: Dr S-Y Hu  
([song9168@pie.com.tw](mailto:song9168@pie.com.tw))