

Massive penile metastasis of bladder cancer

A 69-year-old man was diagnosed with urinary bladder cancer based on histopathology. The cancer was located at the neck of the bladder and invaded the prostate gland. Physical examination revealed a nodule in the right corpus cavernosum. Magnetic resonance imaging showed that the lesion had restricted diffusion and contrast enhancement (**Figure 1a**). Histopathological examination revealed a penile metastasis from the bladder carcinoma. The patient was treated with radiotherapy.

A radiological check-up was performed 7 months after the initial evaluation. Magnetic resonance imaging showed that the dimension of the cavernosal mass had increased in size (**Figure 1b**). The patient died several days after the last radiological evaluation.

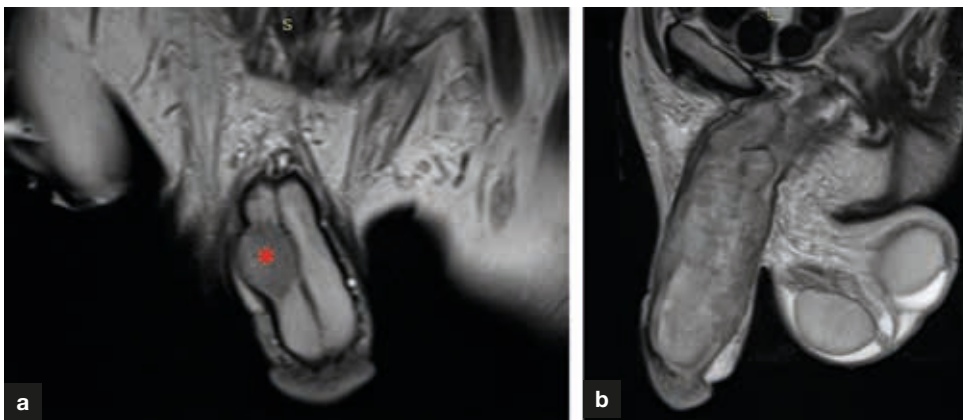


Figure 1. a. At presentation, coronal T2-weighted penile magnetic resonance scan shows a nodular lesion (asterisk) on the right corpus cavernosum. b. At follow up, sagittal T2-weighted magnetic resonance image shows a diffuse penile metastasis.

Penile metastasis is a very rare condition which generally occurs as a secondary metastasis of urogenital or gastrointestinal malignancies. Malignancies of other nearby organs can also cause penile metastasis, which generally occurs as a result of retrograde spread via vascular connections between the neighbouring organs (Mearini et al, 2012).

Author details

¹Department of Radiology, Suleyman Demirel University, Isparta, Turkey

²Department of Radiology, Ataturk University, Erzurum, Turkey

³Department of Pathology, Suleyman Demirel University, Isparta, Turkey

⁴Department of Anesthesiology, Ataturk University, Erzurum, Turkey

Reference

Mearini L, Colella R, Zucchi A et al. A review of penile metastasis. *Oncol Rev.* 2012;6(1):10–87. <https://doi.org/10.4081/oncol.2012.e10>

Veysel Ayyildiz¹

Fahri Aydin²

Sirin Baspinar³

Hayri Ogul^{2,4}

Author details can be found at the end of this article

Correspondence to:

Hayri Ogul;
drhogul@gmail.com

How to cite this article:

Ayyildiz V, Aydin F, Baspinar S, Ogul H. Massive penile metastasis of bladder cancer. *Br J Hosp Med.* 2020. <https://doi.org/10.12968/hmed.2020.0147>