

## An occult pacemaker

Zoe Awadallah<sup>1</sup>

Simon Dubrey<sup>1</sup>

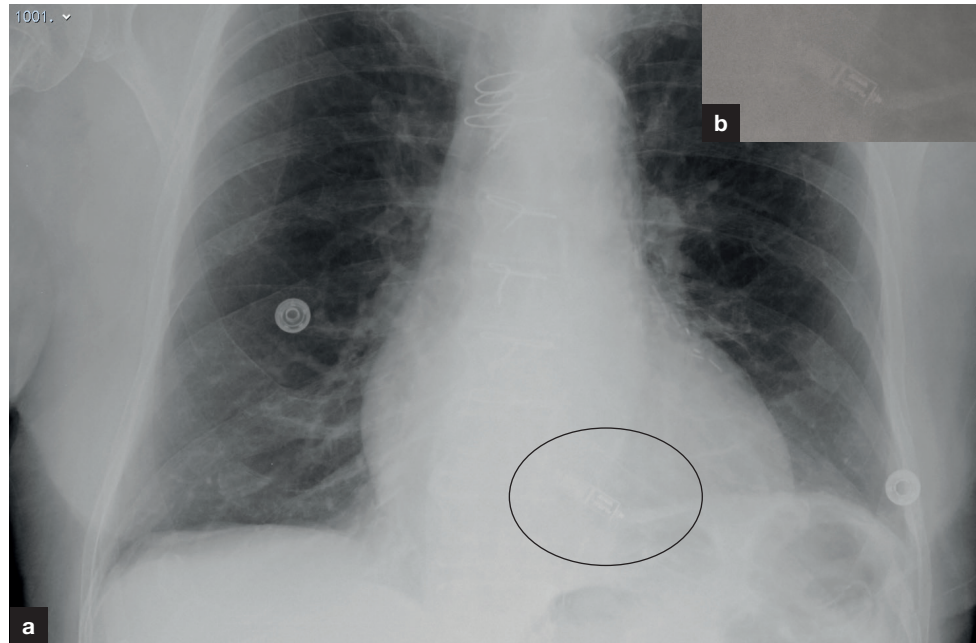
Author details can be found  
at the end of this article

Correspondence to:

Simon Dubrey;  
Simon.dubrey@nhs.net

A 91-year-old man presented with chest pain. He said that he had recently had a pacemaker fitted, although a chest X-ray did not suggest its presence within the lung fields.

A coronary angiogram revealed that the patient had an intra-cardiac pacemaker. Re-review of the chest X-ray showed a small device situated within the cardiac silhouette (**Figure 1**), compatible with an intra-cardiac pacemaker.



**Figure 1.** a. The intracardiac pacemaker is just visible within the cardiac silhouette on a normal chest radiograph. b. An enlarged image of this device is shown adjacent to the heart.

Intra-cardiac pacemakers are inserted percutaneously, through a minimally invasive transvenous approach, directly into the right ventricle.

One leadless pacemaker is currently available, the Micra (Medtronic), with work in progress to relaunch the Nanostim (Abbott) system that had early problems with battery failure and docking issues (Bhatia and El-Chami, 2018; Roberts, 2018).

An additional point, in the context of such devices being difficult to detect once implanted, is that the Micra system does not require explantation when cremation of the body is planned.

### Author details

<sup>1</sup>Department of Cardiology, Hillingdon Hospital, Uxbridge, UK

### References

- Bhatia N, El-Chami M. Leadless pacemakers: a contemporary review. *J Ger Cardiol.* 2018;15:249–253. <https://doi.org/10.11909/j.issn.1671-5411.2018.04.002>
- Roberts P. Pacing supplement: leadless pacing. *Br J Cardiol.* 2018;25(suppl 3):S30–S34. <https://doi.org/10.5837/bjc.2018.s17>

### How to cite this article:

Awadallah Z, Dubrey S.  
An occult pacemaker.  
*Br J Hosp Med.* 2021.  
<https://doi.org/10.12968/hmed.2020.0530>