A visual 'cystem' disturbance with headache

Liam Maher[1]

Bryan Renton[1]

Author details can be found at the end of this article

Correspondence to:
Bryan Renton;
bryan.renton@hse.ie

A 61-year-old man presented with a 1-day history of a mild right-sided headache which had been preceded by a transient episode of visual blurring in his left eye and dizziness. The patient had been driving the day before admission, when he noticed gradual onset of blurriness affecting his left eye and dizziness. These symptoms settled within 30 minutes but were followed shortly afterwards by a mild headache on the right side of head, with no associated symptoms, that persisted for the rest of the day.

His clinical examination was entirely normal, with no focal neurological deficit and a formal ophthalmology review revealed a normal examination. A magnetic resonance imaging scan of the brain illustrated a well-defined, rounded lesion adjacent to the foramen of Monro measuring up to 12 mm x 9 mm. This was associated with mild ventricular prominence, in keeping with a colloid cyst (Figure 1).

The patient was transferred to the neurosurgical centre and subsequently underwent right frontal craniotomy with transcortical resection of a third ventricular colloid cyst. He made an unremarkable recovery.

Author details

[1]Acute Medical Unit, University Hospital Galway, Galway, Ireland

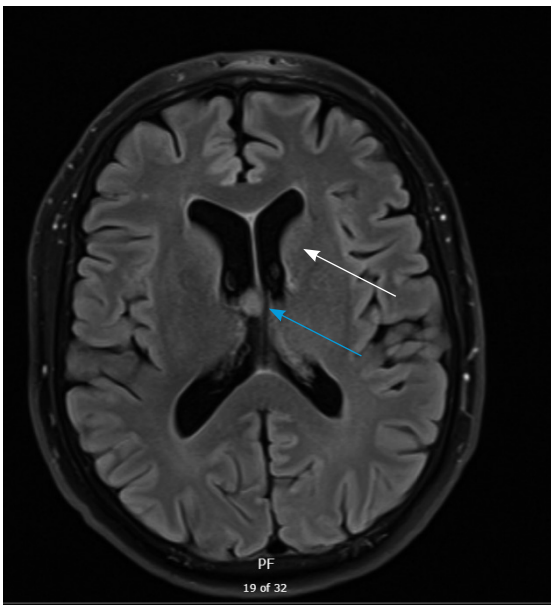

Figure 1. T2-weighted magnetic resonance imaging of the brain demonstrating a 12 mm x 9 mm colloid cyst (blue arrow) and mild ventricular prominence (white arrow).

How to cite this article:
Maher L, Renton B.
A visual 'cystem' disturbance with headache.
Br J Hosp Med. 2021.
https://doi.org/10.12968/hmed.2020.0741

© 2021 MA Healthcare Ltd