

# Concomitant *Campylobacter fetus* septic arthritis and acute gout in an older woman

Maria A Gauci<sup>1</sup>

Justine Grima<sup>1</sup>

Stephanie Attard Camilleri<sup>1</sup>

Lara Delicata<sup>1</sup>

Emanuel Farrugia<sup>1</sup>

Author details can be found at the end of this article

Correspondence to:

Maria A Gauci;  
maria-angela.grima@gov.mt

## Introduction

Acute monoarticular arthritis is a common rheumatological scenario with a vast differential diagnosis, with septic arthritis and crystal arthropathy among the most common causes. A thorough history and examination, together with appropriate investigation, will allow the clinician to differentiate between the two. Nonetheless, the presence of one of these arthritides does not exclude the other, as they may rarely coexist. A correct diagnosis should be followed by prompt initiation of appropriate treatment in order to prevent joint destruction. This article presents a case of concurrent acute gout and septic arthritis of the knee caused by the Gram-negative rod *Campylobacter fetus* in an older woman with hypertension who was taking proton pump inhibitors.

## Case report

A 77-year-old woman presented to the emergency department with a 2-week history of severe left knee pain and decreased range of motion. She did not report fever, abdominal pain or diarrhoeal illness. There was no preceding contact with animals, ingestion of undercooked meat or unpasteurised milk, trauma or joint pains. She suffered from hypertension and gastro-oesophageal reflux disease, for which she took amlodipine and omeprazole.

On examination, the patient was normotensive with a postural drop, had a temperature of 37.2°C and pulse rate of 105 beats/min. The left knee was warm and swollen with a positive patellar tap test. Active and passive knee flexion were significantly reduced, while weight-bearing was limited because of the pain.

Blood investigations showed a predominantly neutrophilic, total white cell count of 18 000 cells/mm<sup>3</sup> (reference range 4.3–11.4 cells/mm<sup>3</sup>), and a C-reactive protein level of 395 mg/litre (reference range 0–5 mg/litre). Acute kidney injury was noted with an increase in serum creatinine level to 125 mg/dl from a baseline of 80 mg/dl (reference range 45–84 mg/dl).

A radiograph of the knees depicted bilateral tricompartmental degenerative changes and a left knee suprapatellar effusion. A computed tomography scan of the affected knee revealed multiple bone erosions, joint effusion and moderate muscular atrophy (Figures 1a and b).

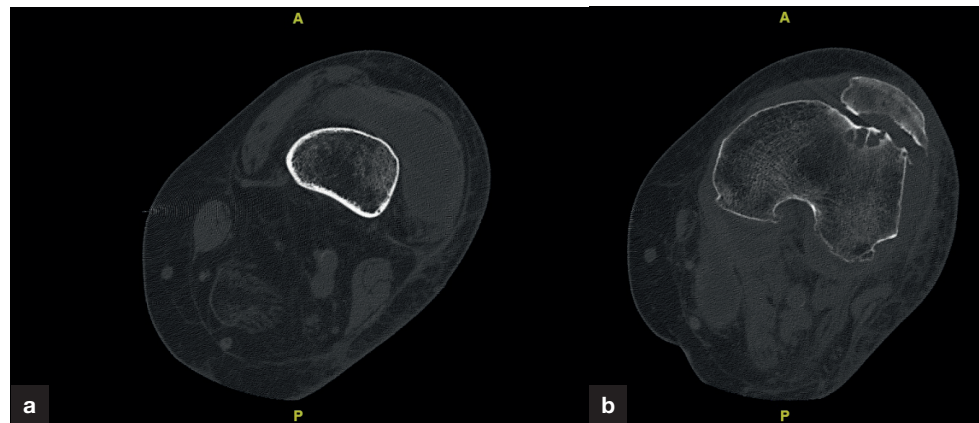
On performing left knee arthrocentesis, turbid amber fluid was obtained. When evaluated under polarised light, monosodium urate crystals were detected. On microscopy, abundant polymorphs were noted, while the Gram stain was negative.

The patient was initiated on regular analgesia, oral colchicine, empiric parenteral vancomycin and piperacillin-tazobactam. These broad-spectrum antibiotics were initiated imminently at the emergency department as the patient fulfilled the criteria for sepsis, and had the potential to deteriorate haemodynamically.

An improvement in the biochemical and clinical picture was noted over the following days. Urine and blood cultures were negative, while, to the clinician's surprise, *Campylobacter fetus* was cultivated from the knee aspirate. This was sensitive to amoxicillin, explaining the patient's significant improvement on the chosen antimicrobial therapy. On obtaining culture sensitivities, the antibiotics were switched to amoxicillin. Parenteral antibiotics were administered for a total of 2 weeks, and switched to oral for another fortnight. Left knee arthroscopy and washout was performed.

The presence of such an infrequent species in the knee aspirate led to a thorough screen for an underlying immunosuppressive disorder. This included serial glucose measurements and a normal glycosylated haemoglobin level. Serum protein electrophoresis, HIV and viral hepatitis screens were all negative. Infective endocarditis was excluded with a normal echocardiogram, while occult malignancy was ruled out following a complete clinical examination and thoracoabdominal computed tomography.

**How to cite this article:** Gauci MA, Grima J, Attard Camilleri S, Delicata L, Farrugia E. Concomitant *Campylobacter fetus* septic arthritis and acute gout in an older woman. Br J Hosp Med. 2021. <https://doi.org/10.12968/hmed.2021.0010>



**Figure 1.** Cross-sectional computed tomography of the left lower limb (a) at the level of the distal femur demonstrating a large effusion in the knee joint and (b) at the level of knee joint revealing multiple bone erosions and effusion in the knee joint, together with atrophic muscles.

## Discussion

The presentation of an acutely swollen, painful joint should prompt investigation for septic arthritis, as this is a rheumatological emergency. This can coincide with an acute crystal arthropathy in 1.5–5% of cases (Shah et al, 2007; Papanicolas et al, 2012).

In the index patient, the presence of synovial fluid monosodium urate crystals confirmed acute gout. A presumptive diagnosis of septic arthritis was also made despite a negative Gram stain, based on the clinical and biochemical picture. Despite its rapidity and high specificity, Gram stain has a false negative rate of 25–78% (Weston et al, 1999; Margaretten et al, 2007; Papanicolas et al, 2012; Stirling et al, 2014), so a negative test should not preclude this diagnosis.

Literature reviews describe the role of inflammatory markers and joint fluid white cell count in differentiating between the two arthritides. While serum C-reactive protein level and synovial leukocyte count may be raised in both scenarios, septic arthritis is more likely with values higher than 100 mg/litre and 10 000 cells/ $\mu$ l respectively (Shah et al, 2007). Ultimately, the diagnosis of a septic joint is confirmed when an organism is cultured. In the patient, the eventual detection of *C. fetus* confirmed the suspicion of septic arthritis.

Infections with this Gram-negative rod occur via the faeco-oral route and usually affect goats, cattle and sheep (Carpenter and Hubbert, 1963). A few cases of septic arthritis in man have been reported in the setting of an underlying immunosuppressive disorder or prosthetic joint (Fick et al, 1979; Cone et al, 2003; Rollot et al, 2004; Man, 2011; Meyer et al, 2012; Prendki et al, 2013). Wagenaar et al (2014) highlighted risk factors for infection with this organism that include old age, pregnancy, heart valve abnormalities, liver disease and diabetes mellitus. Moreover, they also suggested that hypochlorhydria may promote passage of *C. fetus* through the stomach mucosa, resulting in systemic infection.

This patient denied intake of undercooked meat or contact with animals. However, she was on long-term omeprazole for gastro-oesophageal reflux disease. No causes of cell-mediated or humoral immunodeficiency were identified. Occult malignancy and infective endocarditis were also ruled out. The authors postulate that her advanced age, pre-existing osteoarthritis and proton pump inhibitor usage predisposed to *C. fetus* septic arthritis.

## Conclusions

To the authors' knowledge, this is the first reported case of co-presentation of *C. fetus* septic arthritis and monosodium urate crystal-induced arthritis. The co-existence of such arthropathies is rare, but must always be borne in mind when treating an acutely inflamed joint to avoid its permanent destruction. In the setting of a negative Gram stain, the clinician must keep a very high index of suspicion and use serological and synovial fluid analyses appropriately. This report also describes the rare occurrence of *C. fetus* infection in an older woman, in the absence of underlying malignancy or immunosuppression. However, the authors postulate that advanced age and longstanding use of proton pump inhibitors may have put the patient at significant risk for such an infection.

## Learning points

- Septic arthritis and crystal arthropathy present similarly and can rarely occur simultaneously.
- A negative Gram stain does not exclude the presence of a septic joint. The clinical picture, markedly high serum inflammatory markers and synovial fluid leukocyte count are all clinical indicators of such a diagnosis.
- Osteoarthritis and gout can both predispose to septic arthritis, as demonstrated in this patient.
- *Campylobacter fetus* septic arthritis is rare and necessitates the investigation for underlying immunosuppression or malignancy.
- Advanced age and possibly chronic proton pump inhibitor use should be considered as risk factors for *C. fetus* infection.

### Author details

1 Department of Nephrology and General Medicine, Mater Dei Hospital, L-Imnsida, Malta

### Acknowledgements

The authors would like to thank Dr James Farrugia, Dr Sarah M Vella and Dr Tonio Piscopo from the Department of Infectious Diseases and General Medicine, and Mr Luke Saliba and Mr Ryan Giordimaina from the Department of Orthopaedics, Mater Dei Hospital, Malta, for their help in the management of this patient.

## References

- Carpenter CM, Hubbert WT. Vibriosis in diseases transmitted from animals to man. In: Hull TG (ed). Diseases transmitted from animals to man. Springfield: Charles C Thomas; 1963:170
- Cone LA, Dreisbach PB, Hirschberg J et al. Cellulitis and septic arthritis caused by *Campylobacter fetus* and *Campylobacter jejuni*: report of 2 cases and review of the literature. *J Clin Rheumatol*. 2003;9(6):362–369. <https://doi.org/10.1097/01.rhu.0000090261.11345.87>
- Fick RB, Jr, Isturiz R, Cadman EC. *Campylobacter fetus* septic arthritis: report of a case. *Yale J Biol Med*. 1979;52(4):339–344
- Man SM. The clinical importance of emerging *Campylobacter* species. *Nat Rev Gastroenterol Hepatol*. 2011;8(12):669–685. <https://doi.org/10.1038/nrgastro.2011.191>
- Margaretten ME, Kohlwes J, Moore D et al. Does this adult patient have septic arthritis? *JAMA*. 2007;297(13):1478–1488. <https://doi.org/10.1001/jama.297.13.1478>
- Meyer A, Theulin A, Chatelus E et al. *Campylobacter fetus* infection in three rheumatoid arthritis patients treated with rituximab. *Ann Rheum Dis*. 2012;71(6):1094–1095. <https://doi.org/10.1136/annrheumdis-2011-200719>
- Papanicolas LE, Hakendorf P, Gordon DL. Concomitant septic arthritis in crystal monoarthritis. *J Rheumatol*. 2012;39(1):157–160. <https://doi.org/10.3899/jrheum.110368>
- Prendki V, Marmor S, Zeller V et al. *Campylobacter* infection after prosthetic joint surgery. *Scand J Infect Dis*. 2013;45(9):706–710. <https://doi.org/10.3109/00365548.2013.800225>
- Rollot K, Albert JD, Werner S et al. *Campylobacter fetus* septic arthritis revealing a malignancy. *Joint Bone Spine*. 2004; 71(1):63–65. [https://doi.org/10.1016/S1297-319X\(03\)00094-0](https://doi.org/10.1016/S1297-319X(03)00094-0)
- Shah K, Spear J, Nathanson LA et al. Does the presence of crystal arthritis rule out septic arthritis? *J Emerg Med*. 2007;32(1):23–26. <https://doi.org/10.1016/j.jemermed.2006.07.019>
- Stirling P, Faroug R, Amanat S et al. False-negative rate of gram-stain microscopy for diagnosis of septic arthritis: suggestions for improvement. *Int J Microbiol*. 2014;2014:1–4. <https://doi.org/10.1155/2014/830857>
- Wagenaar JA, van Bergen MA, Blaser MJ et al. *Campylobacter fetus* infections in humans: exposure and disease. *Clin Infect Dis*. 2014;58(11):1579–1586. <https://doi.org/10.1093/cid/ciu085>
- Weston VC, Jones AC, Bradbury N et al. Clinical features and outcome of septic arthritis in a single UK Health District 1982–1991. *Ann Rheum Dis*. 1999;58(4):214–219. <https://doi.org/10.1136/ard.58.4.214>