

Olecranon fractures: applied anatomy, clinical assessment and evidence-based management

Dileep Karthikappallil¹

Thomas Cash¹

Jochen Fischer¹

Mohammad Waseem¹

Author details can be found at the end of this article

Correspondence to:

Dileep Karthikappallil;
dkarthikappallil@nhs.net

Abstract

Olecranon fractures are common injuries, making up 10% of all fractures of the upper limb. They usually result from a fall from standing height in older people, or from a direct blow in young people. The olecranon's superficial location, with poor soft tissue and muscle protection, make it liable to fracture following direct impact.

Factors such as the degree of initial force and the quality of the patient's bone result in a range of injury patterns, from simple undisplaced fractures to complex open fracture dislocations. In the context of high energy trauma, the patient should first be assessed for life-threatening injuries. A thorough history and clinical examination including neurovascular assessment should then be completed. Antero-posterior and lateral X-rays are sufficient to confirm the diagnosis. Initial management includes immobilisation in an above elbow backslab, a sling and analgesia.

Owing to the pull of the triceps muscle which attaches to the tip of the olecranon, fracture displacement is common and surgical intervention is often required, usually with good outcomes. Surgical techniques include tension band wiring, open reduction internal fixation with a pre-contoured locking plate and tension band suture fixation. Undisplaced fractures or displaced fractures in older patients can be managed conservatively with an above elbow cast for 4 weeks. This article covers applied anatomy, initial presentation, clinical assessment and evidence-based management.

Key words: Diagnosis; Management; Olecranon fracture

Submitted: 30 April 2021; **accepted following double-blind peer review:** 11 October 2021

Introduction

Olecranon fractures are common injuries, accounting for up to 10% of all upper limb fractures (Rommens et al, 2004). The mechanism of injury is usually a fall on an outstretched limb. The olecranon's superficial location, with poor soft tissue and muscle protection, makes it liable to fracture following direct impact.

Factors such as the degree of initial force and the quality of the patient's bone, result in a variety of injury patterns, ranging from simple undisplaced fractures to complex open fracture dislocations. The injury follows a bimodal age distribution, with high energy injuries classically being seen in the young and low energy injuries observed in the elderly.

Owing to the pull of the triceps muscle which attaches to the tip of the olecranon, fracture displacement is common and surgical intervention is often required, usually with good outcomes. This article covers applied anatomy, initial presentation, clinical assessment and evidence-based management.

Applied anatomy

The olecranon refers to the zone of proximal ulna from the palpable tip to the coronoid process. The olecranon has a large intra-articular surface, shaped like a deep trough and is therefore an important contributor to elbow joint stability. The elbow can be described as a complex hinge-type synovial joint consisting of three articulations: between the olecranon and the humerus (ulno-humeral joint), between the radius and the capitellum of the humerus (radio-capitellar joint) and between the proximal radius and ulna (proximal radio-ulnar joint).

How to cite this article:

Karthikappallil D, Cash T, Fischer J, Waseem M. Olecranon fractures: applied anatomy, clinical assessment and evidence-based management. *Br J Hosp Med.* 2022. <https://doi.org/10.12968/hmed.2021.0272>

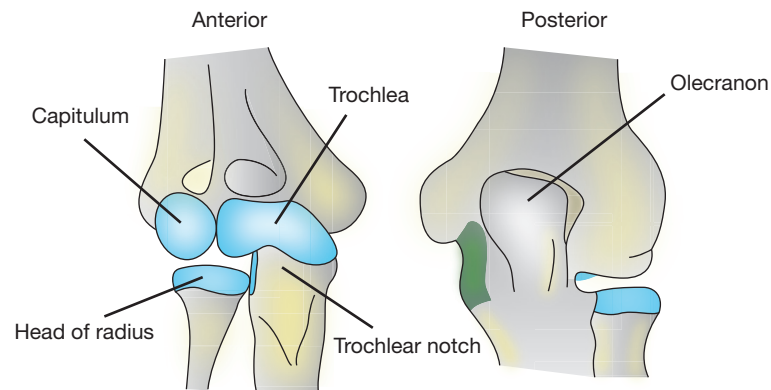


Figure 1. Anterior and posterior view of the elbow joint.

The concave semilunar notch of the olecranon articulates with the trochlea of the humerus, aiding joint stability and allowing the flexion and extension of the elbow. The olecranon acts as a lever to enable elbow extension via the triceps brachii muscle which inserts at the proximal tip, as well as a small contribution from the anconeus muscle. Both muscles are supplied by the radial nerve. Flexion of the elbow is elicited via the brachialis and biceps brachii muscles (musculocutaneous nerve) as well as the brachioradialis muscles (radial nerve).

Other important static stabilisers of the elbow joint include the medial and lateral collateral ligaments, the elbow capsule and the radio-capitellar joint. Dynamic stabilisers include the muscles which cross the elbow joint as described above. Forearm rotation (pronation and supination) occurs at the proximal radio-ulnar joint.

Knowledge of the applied anatomy, as shown in [Figure 1](#), aids understanding of the deforming forces which occur in olecranon fractures and can be used to inform clinical decision making.

Initial presentation and clinical assessment

Patients with olecranon fractures present in different ways because of the bimodal distribution of injuries. If the patient has been involved in high energy trauma, such as a fall from height or a road traffic collision, life-threatening injuries should be addressed first in accordance with the Advanced Trauma Life Support principles (ATLS Subcommittee, 2018).

The elbow should be inspected for visible deformity, bruising and skin integrity. A neurovascular assessment is then performed which includes palpating for the radial and brachial pulses, checking capillary refill time and testing the motor and sensory function of the median, radial and ulnar nerves.

Compartment syndrome is a rare complication in isolated olecranon fractures, but it may be seen in high energy upper limb injuries which have caused significant soft tissue injury.

Open fractures should be treated according to the British Orthopaedic Association guidelines for open fractures (British Orthopaedic Association and British Association of Plastic, Reconstructive and Aesthetic Surgeons, 2017). The wound should be photographed and covered with saline-soaked gauze before being immobilised in an above elbow backslab. Intravenous broad-spectrum antibiotics should be administered in line with local hospital policy and the patient's tetanus status checked. Early referral to a specialist orthopaedic centre should be considered for severe injuries which may require plastic surgical intervention in the form of skin grafts or flap coverage.

In the absence of high energy trauma, most patients with olecranon fractures present with pain localised to the posterior aspect of the elbow combined with an inability to extend the elbow. On examination, a palpable defect may be felt at the fracture site. As with all orthopaedic injuries, the joint should be examined above and below to rule out any associated injury.

Imaging

Plain X-rays are essential to confirm the diagnosis. Antero-posterior and lateral X-rays are sufficient to identify olecranon fractures. Look also for surrounding soft tissue swelling which may indicate a subtle undisplaced fracture. The lateral X-ray should be assessed for ulno-humeral instability by checking the radio-capitellar line. If a line drawn along the radial neck does not intersect the capitellum, this should alert the clinician to an unstable olecranon fracture which influences the treatment strategy.

Extra care and vigilance are required when interpreting paediatric elbow X-rays, because of the appearance and subsequent fusion of ossification centres. Typically, the olecranon ossification centre appears at the age of 9 years and fuses between 15 and 17 years of age (Waters et al, 2020). Partial closure of the olecranon ossification centre can sometimes be mistaken for a fracture. Patella cubiti is a rare variant where a sesamoid bone is seen within the distal triceps tendon (McRae and Esser, 2002). Round well-corticated edges should reassure the clinician that this is not an acute fracture.

Computed tomography scanning is not routinely required for simple transverse olecranon fractures, but may be helpful for preoperative planning in comminuted fracture patterns. This may identify an intermediate fragment which should be addressed during surgical fixation to give the best functional outcome (von Rden et al, 2018). Computed tomography is required in high energy injuries to look for associated bony injuries, including fractures of the coronoid, radial head and bony avulsion of the collateral ligaments which, if detected, would need to be addressed at the time of surgery.

Radiological classification of olecranon fractures

Multiple classification systems have been described for olecranon fractures including the Mayo, Colton, Schatzker and AO. No single classification has become ubiquitous. The Mayo classification was first described by Morrey (1993) and is outlined in [Figure 2](#). It classifies olecranon fractures into types I to III incorporating fracture displacement, stability and degree of comminution. These fracture characteristics help determine the most appropriate definitive management. Patient factors are equally important, and these are discussed below.

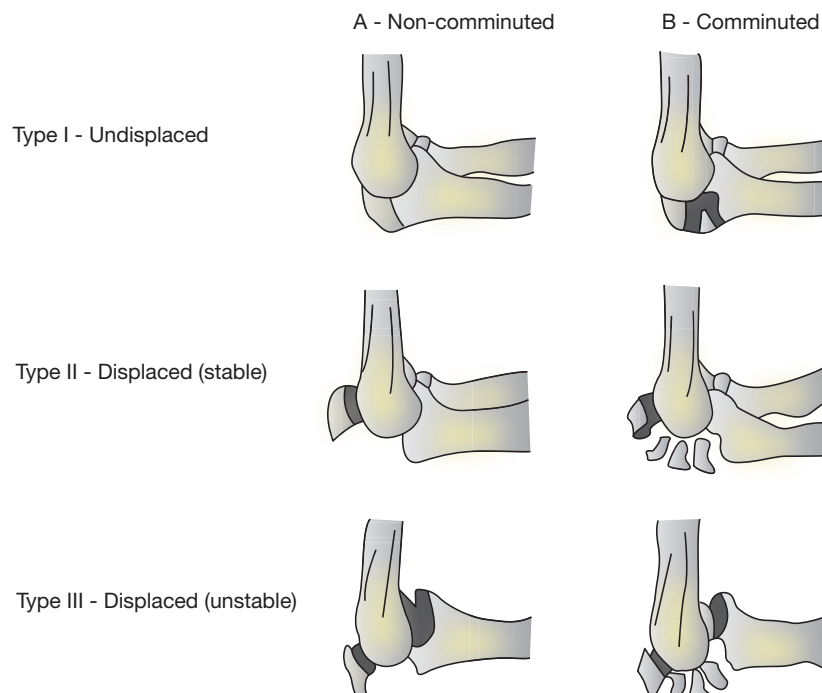


Figure 2. Mayo classification of olecranon fractures.

Management of olecranon fractures

Initial management

Once a thorough clinical assessment has been performed and X-rays obtained, the injured arm should be immobilised in an above elbow backslab and supported with a sling. Repeat X-rays should then be obtained. Patients with undisplaced fractures can be discharged from the emergency department and followed up in the fracture clinic. Patients with displaced or unstable olecranon fractures should be immobilised as above and referred to the orthopaedic on-call team for consideration of surgery. Unstable fractures are defined as fracture dislocations (Morrey, 2009) or Mayo type III injuries, where fracture fragments are displaced and the forearm does not articulate properly with the humerus. This is indicated by disruption of the radio-capitellar line on the lateral elbow X-ray.

Surgical management

The goals of surgical intervention in patients with olecranon fractures are to restore the articular surface of the ulno-humeral joint, to reestablish the function of the triceps muscle as an elbow extensor and to achieve fracture healing. Successful surgery can reduce the risk of post-traumatic arthritis and give the patient excellent long-term function. Indications for surgery are outlined in [Table 1](#). Surgical management has traditionally been achieved using one of two methods: tension band wiring or plate fixation. Both surgical techniques can be performed with the patient in the lateral position with the arm resting over a post. A sterile disposable tourniquet can be applied to maintain a bloodless field. A posterior skin incision is made over the olecranon, taking care to avoid the bursa and the ulnar nerve.

The principle of tension band wiring is to convert the distracting force of the triceps muscle into a compressive force to achieve fracture healing. The fracture is reduced and temporarily held with a reduction clamp. Two parallel Kirschner wires are passed from the tip of the olecranon, across the fracture site, to exit on the anterior cortex of the ulna. A drill hole is made in the posterior cortex of the ulna, distal to the fracture site. Cerclage wire is then passed through the drill hole, around the Kirschner wires in a figure of eight configuration and tightened. The cerclage wire ends are cut short and buried to avoid soft tissue irritation. The Kirschner wires are then bent, cut and sunk into the triceps tendon ([Figure 3](#)).

While tension band wiring works well for displaced, non-comminuted olecranon fractures (Mayo type IIA), it is not appropriate for all fracture patterns. Open reduction internal fixation using pre-contoured locking plates is more appropriate for stable displaced comminuted fractures (Mayo type IIB) and unstable displaced fractures (Mayo type III) to achieve anatomical fracture reduction (Bailey et al, 2001; Newman et al, 2009). Conventionally, most surgeons have used a single pre-contoured dorsal locking plate. The initial steps of the procedure are the same as for tension band wiring fixation. Once the fracture has been reduced anatomically and held with a reduction clamp or temporary Kirschner wires, a pre-contoured locking plate is selected and secured initially with non-locking and then locking screws ([Figure 4](#)). Care needs to be taken to ensure screws do not penetrate the elbow joint.

Several studies have demonstrated that low profile double plating of the olecranon is an acceptable alternative to dorsal plating with similar biomechanical stability (Hoelscher-Doht et al, 2021). Pre-contoured locking plates are placed on the medial and lateral column of the olecranon to achieve anatomical fracture reduction. This technique may cause less soft tissue irritation, but studies have not found a decrease in cases of metalwork removal when compared to conventional dorsal plating (Hoelscher-Doht et al, 2021).

Table 1. Indications for surgical intervention

Displaced fractures (>2 mm) with or without elbow joint subluxation (Mayo type II or III)*
Neurovascular compromise
Open fracture

* Care required if considering surgery in patients >75 years as a result of the increased complication rate

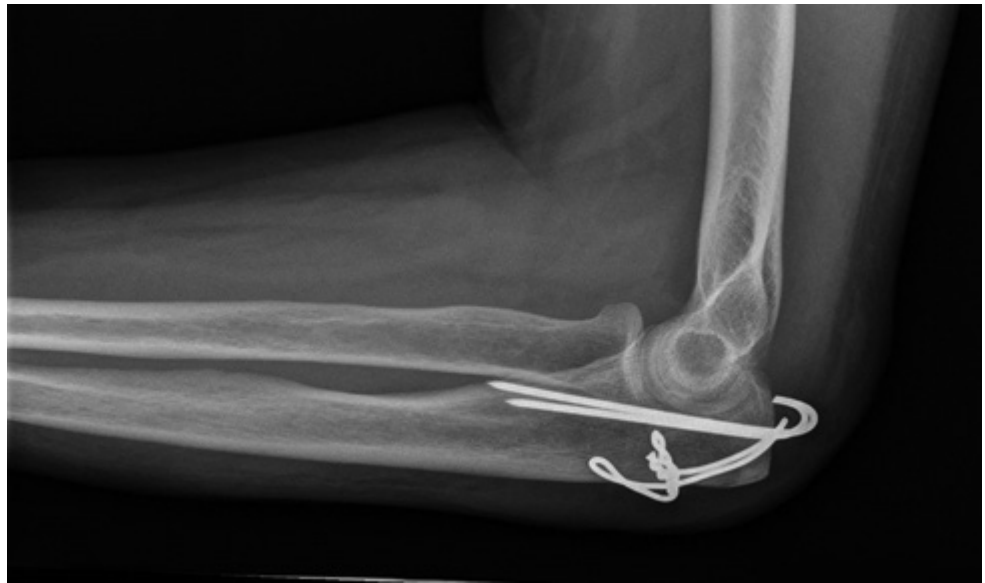

Figure 3. Lateral plain X-ray of tension band fixation of the olecranon.

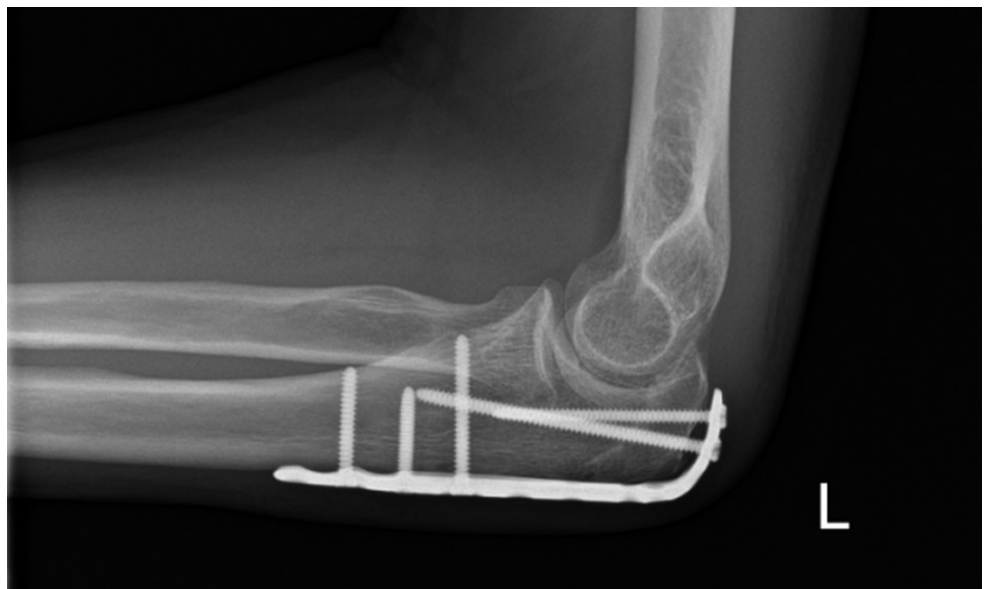

Figure 4. Lateral plain X-ray of open reduction internal fixation using locking plate.

While tension band wiring and plate fixation have different indications, several studies have directly compared tension band wiring and plate fixation specifically in patients with Mayo type IIA fractures. Duckworth et al (2017a) performed a randomised control trial of 67 patients and found no difference in patient-reported outcomes at 1-year follow up between the two treatments. These findings are corroborated by several systematic reviews (Ren et al, 2016; Rantalaiho et al, 2021). However, tension band wiring had a higher rate of metalwork removal compared to plate fixation. This is an important consideration when counselling patients about the benefits and risks of surgery.

Metalware removal is the most common complication, occurring in up to 50% in tension band wiring and 22% following plate fixation (Duckworth et al, 2017a). Other common complications of surgery include stiffness, heterotopic ossification, post-traumatic arthritis and non-union (Morrey, 1993).

Novel techniques have emerged to eliminate the need for insertion of metalwork. The suture anchor fixation method (Bateman et al, 2015) and tension band suture fixation method (Phadnis and Watts, 2017) have both shown promising results, with satisfactory radiological and clinical outcomes, but are yet to be widely adopted into clinical practice.

Conservative management

Conservative management is appropriate for undisplaced fractures. The arm should be immobilised in an above-elbow cast with the elbow in 90° of flexion for 4 weeks before starting elbow mobilisation with physiotherapy input. If there is concern about fracture displacement, a repeat X-ray should be obtained 1 week after injury.

There has been a paradigm shift in the management of older patients with displaced olecranon fractures in favour of non-operative management. This patient group is at a significantly increased risk of complications following surgery (Parkes et al, 2021). The reasons for this are multifactorial, but may include poor quality osteoporotic bone (increasing the risk of fixation failure), fragile skin (increasing the risk of wound breakdown) and comorbidities such as diabetes (increasing the risk of infection). This followed a randomised trial by Duckworth et al (2017b), which had to be stopped early owing to a high complication rate in older patients who underwent surgery. The study found no difference in patient-reported outcomes at 1 year.

Conclusions

Olecranon fractures are common upper limb injuries and have a bimodal age distribution, resulting from low energy falls in elderly patients and higher energy mechanisms in young patients. The olecranon's superficial location, with poor soft tissue and muscle protection, make it liable to fracture following direct impact.

Initial work should include a thorough history and clinical examination including a neurovascular assessment. Antero-posterior and lateral X-rays should then be obtained to confirm the diagnosis. Initial management in the emergency department involves immobilisation in an above-elbow backslab with a sling and appropriate analgesia. Undisplaced fractures can be referred to the fracture clinic, but displaced fractures require referral to the orthopaedic on call team for consideration of surgery.

Surgical management options include tension band wire fixation, open reduction internal fixation with a pre-contoured locking plate or suture fixation. Conservative management involves immobilisation in an above-elbow cast for 4 weeks. The decision-making process can be challenging, and patients should be fully informed of the intended benefits and risks of surgery. Fracture factors that help guide decision making include the degree of comminution, displacement and stability. Patient factors that should be considered include age, functional status, and number of comorbidities.

Key points

- Olecranon fractures have a bimodal distribution, commonly resulting from high energy injuries in the young and low energy injuries in older patients.
- The Mayo classification can be used to identify those patients in need of surgical intervention and help plan surgical management.
- These injuries may be treated conservatively when undisplaced or in older patients, but there are typically two main methods of operative fixation for the olecranon: tension band wiring or open reduction internal fixation with a plate.

Curriculum checklist

This article addresses the following requirements from the general internal medicine curriculum:

- Managing an acute specialty-related take
- Managing medical problems in patients in other specialties and special cases
- Managing a multidisciplinary team including effective discharge planning.

Author details

¹Department of Orthopaedics, Macclesfield District General Hospital, East Cheshire NHS Trust, Macclesfield, UK

Conflicts of interest

The authors declare that they have no conflicts of interest.

References

- ATLS Subcommittee. American College of Surgeons' Committee on Trauma. International ATLS working group. Advanced Trauma Life Support (ATLS®). Chicago: American College of Surgeons; 2018
- Bailey CS, MacDermid J, Patterson SD, King GJ. Outcome of plate fixation of olecranon fractures. *J Orthop Trauma*. 2001;15(8):542–548. <https://doi.org/10.1097/00005131-200111000-00002>.
- Bateman DK, Barlow JD, VanBeek C, Abboud JA. Suture anchor fixation of displaced olecranon fractures in the elderly: a case series and surgical technique. *J Shoulder Elbow Surg*. 2015;24(7):1090–1097. <https://doi.org/10.1016/j.jse.2015.02.017>
- British Orthopaedic Association, British Association of Plastic, Reconstructive and Aesthetic Surgeons. Open Fractures. 2017. <https://www.boa.ac.uk/asset/3B91AD0A%2D9081%2D4253%2D92F7D90E8DF0FB2C/> (accessed 4 February 2022)
- Duckworth AD, Clement ND, White TO, Court-Brown CM, McQueen MM. Plate versus tension-band wire fixation for olecranon fractures: a prospective randomized trial. *J Bone Joint Surg*. 2017a;99(15):1261–1273. <https://doi.org/10.2106/JBJS.16.00773>
- Duckworth AD, Clement ND, McEachan JE et al. Prospective randomised trial of non-operative versus operative management of olecranon fractures in the elderly. *Bone Joint J*. 2017b;99-B(7):964–972. <https://doi.org/10.1302/0301-620X.99B7.BJJ-2016-1112.R2>
- Hoelscher-Dohrt S, Kladny A-M, Paul MM et al. Low-profile double plating versus dorsal LCP in stabilization of the olecranon fractures. *Arch Orthop Trauma Surg*. 2021;141(2):245–251. <https://doi.org/10.1007/s00402-020-03473-9>
- McRae R, Esser M. *Practical Fracture Treatment*. 4th edn. London: Elsevier Limited; 2002
- Morrey BF. *The Elbow and Its Disorders*. 2nd edn. Philadelphia: Saunders; 1993
- Morrey BF. Current concepts in the management of complex elbow trauma. *The Surgeon*. 2009;7(3):151–161. [https://doi.org/10.1016/S1479-666X\(09\)80039-5](https://doi.org/10.1016/S1479-666X(09)80039-5)
- Newman SD, Mauffrey C, Krikler S. Olecranon fractures. *Injury*. 2009; 40(6):575–581. <https://doi.org/10.1016/j.injury.2008.12.013>
- Parkes J, Limb R, Quadri S et al. Complications and mortality associated with olecranon fractures in the elderly: a retrospective cohort comparison from a large level one trauma centre. *Shoulder Elbow*. 2021;175857322199486. <https://doi.org/10.1177/1758573221994860>
- Phadnis J, Watts AC. Tension band suture fixation for olecranon fractures. *Shoulder Elbow*. 2017;9(4):299–303. <https://doi.org/10.1177/1758573216687305>
- Rantalaiko IK, Miikkulainen AE, Laaksonen IE, Äärämaa VO, Laimi KA. Treatment of displaced olecranon fractures: a systematic review. *Scand J Surg*. 2021;110(1):13–21. <https://doi.org/10.1177/1457496919893599>
- Ren Y-M, Qiao H-Y, Wei Z-J et al. Efficacy and safety of tension band wiring versus plate fixation in olecranon fractures: a systematic review and meta-analysis. *J Orthop Surg Res*. 2016;11(1):137. <https://doi.org/10.1186/s13018-016-0465-z>
- Rommens P, Küchle R, Schneider RU, Reuter M. Olecranon fractures in adults: factors influencing outcome. *Injury*. 2004;35(11):1149–1157. <https://doi.org/10.1016/j.injury.2003.12.002>
- von Rüden C, Hierholzer C, Bühren V, Trentz O, Woltmann A. Role of the intermediate fragment and relevance in operative treatment of olecranon fractures. *Orthopaedic Proceedings* 93-B(SUPP_II); 2018. https://online.boneandjoint.org.uk/doi/abs/10.1302/0301-620X.93BSUPP_II.0930219e# (accessed 2 February 2022)
- Waters PM, Skaggs DL, Flynn JM. *Rockwood and Wilkins' Fractures in Children*. 9th edn. Philadelphia: Walter Kluwer; 2020