

# Endoscopic extraction of a large impacted gallstone (Bouveret syndrome with cholecystoduodenal and cholecystocolonic fistula) with a snare through the rectum

I Lyutakov<sup>1</sup>

G Jelev<sup>2</sup>

B Golemanov<sup>1</sup>

B Vladimirov<sup>1</sup>

P Penchev<sup>1</sup>

Author details can be found at the end of this article

Correspondence to:

I Lyutakov;  
ivan.lyutakov@gmail.com

## Introduction

Bouveret syndrome is a rare condition of obstruction caused by migration of a gallstone through a bilio-enteric fistula between the gallbladder and duodenum (Katsinelos et al, 2003). Bouveret syndrome can cause gallstone ileus, which is impaction of a gallstone causing intestinal obstruction. This condition is found in 0.3–0.5% of patients with cholelithiasis (Nuño-Guzmán et al, 2016). There are very few publications describing the migration of gallstones through a gastrointestinal fistula (Gibreel et al, 2018). This article presents the case of a 72-year-old woman with gastric outlet obstruction caused by an impacted gallstone in the duodenum, cholecystoduodenal fistula and two gallstones that migrated to the sigmoid colon through a cholecystocolonic fistula.

## Discussion

Bouveret syndrome is a rare condition of gallstone obstruction caused by migration of the gallstone through a bilio-enteric fistula between the gallbladder and duodenum (cholecystoduodenal fistula) (Bouveret, 1896; Negi et al, 2015). The cholecystocolonic fistula is another uncommon complication of biliary cholecystitis and occurs in 0.06–0.14% of patients with biliary disorders (Katsinelos et al, 2003; Gibreel et al, 2018). Gallstone obstruction of the colon (gallstone ileus) is an unusual mechanical intestinal obstruction caused by gallstone migration and impaction within the gastrointestinal tract. It can be detected during endoscopy and in certain situations endoscopic extraction may be possible (Nuño-Guzmán et al, 2016). This article presents an unusual case with two complications of gallstone impaction in the duodenum with migration of the stones into the sigmoid, causing obstruction. Obstruction was managed endoscopically with the stone extracted via the rectum. The gallbladder stone and the choleduodenal fistula were treated surgically. This case illustrates the possibility for reducing surgical intervention, via endoscopic extraction of the gallstone that had migrated into the sigmoid colon.

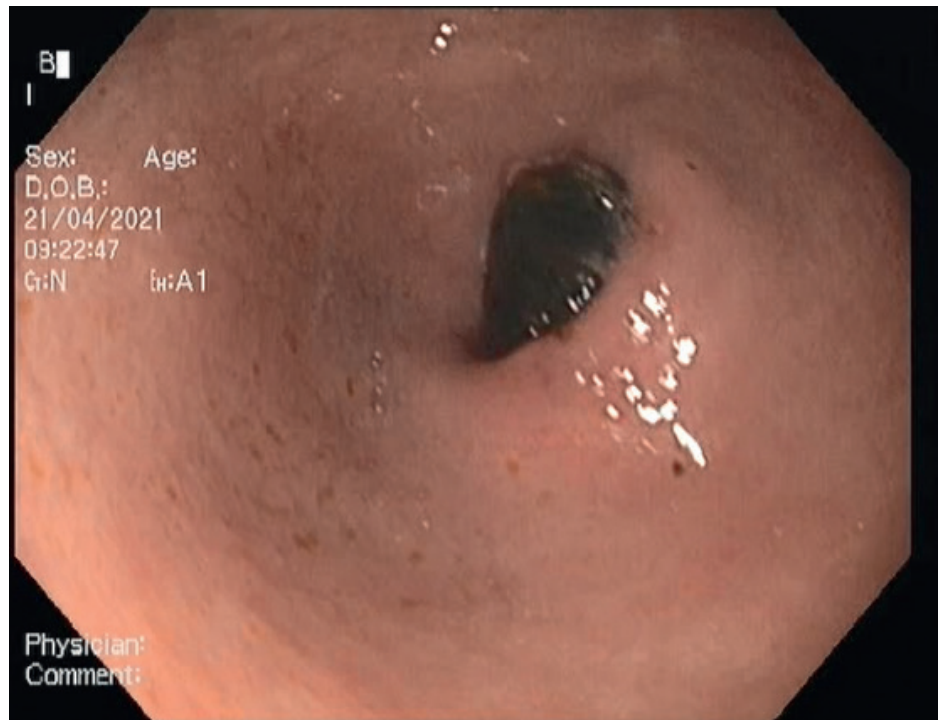
## Case report

A 72-year-old woman presented with diarrhoea, rectal tenesmus and gastric outlet obstruction caused by an impacted gallstone in the duodenum, cholecystoduodenal fistula and two gallstones that had migrated to the sigmoid colon through a cholecystocolonic fistula. Abdominal ultrasound showed one large stone in the gallbladder, no dilatation of the common bile duct and a normal liver, but there were 'non-specific' hypoechogenic changes in the sigmoid colon. Upper endoscopy showed a giant gallstone obstructing the duodenum and causing gastric outlet syndrome. It was not possible to insert an instrument around the stone (Figure 1).

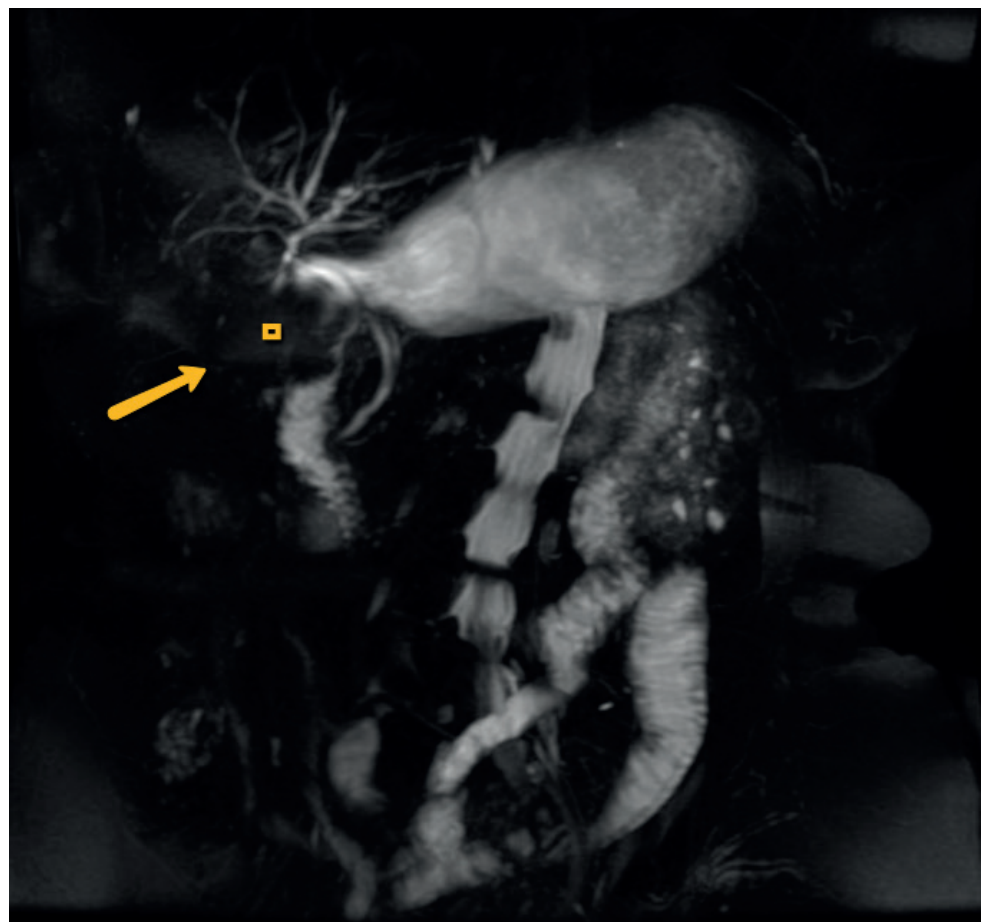
Magnetic resonance cholangiopancreatography showed a calculus impacted in the duodenum with proximal dilatation of the gut (Figure 2). A fistula communication was noted between the first part of the duodenum and the flexura coli hepatica. Colonoscopy showed a large 2x2 cm gallstone in the sigmoid colon, which was extracted successfully through the anus using a polypectomy snare (Figure 3). The ileocecal valve was reached during colonoscopy and a 4x4 cm fistula orifice was found in the ascending colon (flexura hepatica) with another gallstone obstructing the cholecysto-colonic fistula. Attempts to extract the second gallstone using different instruments were unsuccessful. The patient underwent surgical treatment which resulted in successful extraction of the second gallstone.

## How to cite this article:

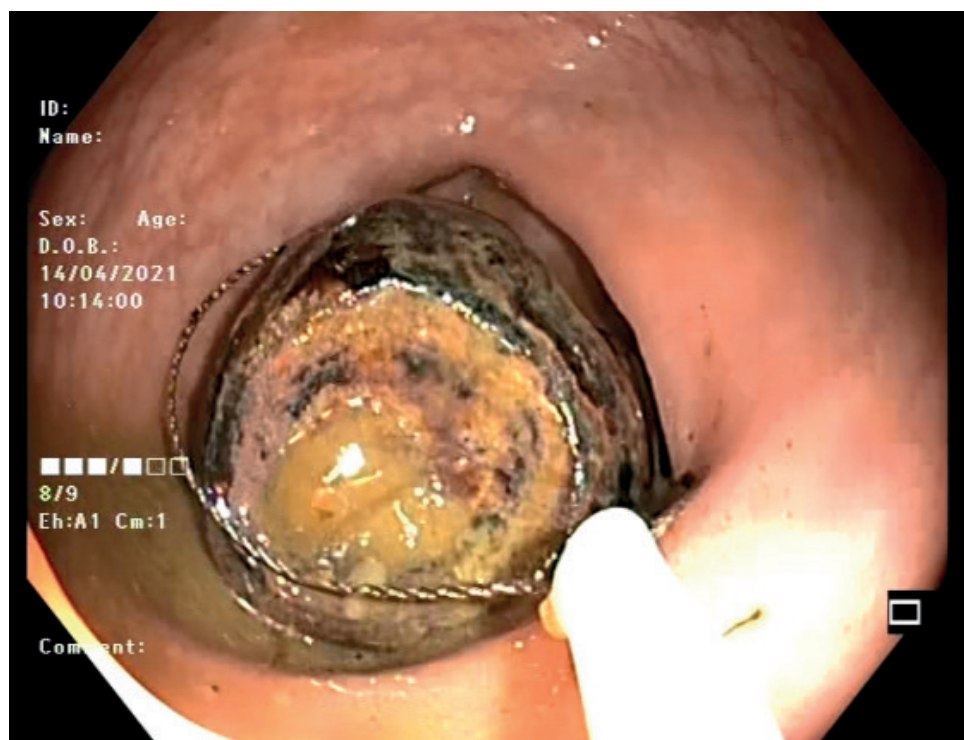
Lyutakov I, Jelev G, Golemanov B et al. Endoscopic extraction of a large impacted gallstone (Bouveret syndrome with cholecystoduodenal and cholecystocolonic fistula) with a snare through the rectum. *Br J Hosp Med.* 2022. <https://doi.org/10.12968/hmed.2021.0365>



**Figure 1.** Endoscopy showing the gallstone obstructing the duodenum and the pylorus of the stomach with gastric outlet syndrome.



**Figure 2.** Magnetic resonance cholangiopancreatography showing the gallstone obstructing the duodenum (arrow).



**Figure 3.** Large 2x2 cm gallstone impacted into the sigmoid part of the colon and extracted with a polypectomy snare.

### Learning points

- Bouveret syndrome is a rare condition of obstruction caused by migration of a gallstone.
- Magnetic resonance cholangiopancreatography is a good method for diagnosing choledochoduodenal fistula.
- Endoscopy can be used to extract a gallstone that has migrated into the colon.
- Chronic cholecystitis can cause severe complications in patients with fistula.

### Author details

<sup>1</sup>Department of Gastroenterology, University Hospital 'Tsaritsa Yoanna – ISUL', Medical University Sofia, Sofia, Bulgaria

<sup>2</sup>Department of Surgery, University Hospital 'Tsaritsa Yoanna – ISUL', Medical University Sofia, Sofia, Bulgaria

### References

- Bouveret L. Stenose du pylore adherent a la vesicule calculeuse. *Rev Med (Paris)*. 1896;16:116
- Gibreel W, Greiten LL, Alsayed A et al. Management dilemma of cholecysto-colonic fistula: case report. *Int J Surg Case Rep*. 2018;42:233–236. <https://doi.org/10.1016/j.ijscr.2017.12.017>
- Katsinelos P, Dimiropoulos S, Tsolkas P et al. Successful treatment of duodenal bulb obstruction caused by a gallstone (Bouveret's syndrome) after endoscopic mechanical lithotripsy. *Surg Endosc*. 2003;16(9):1363. <https://doi.org/10.1007/s00464-002-4200-y>
- Negi R, Chandra M, Kapur R. Bouveret syndrome: primary demonstration of cholecystoduodenal fistula on MR and MRCP study. *Indian J Radiol Imaging*. 2015;25(1):31–34. <https://doi.org/10.4103/0971-3026.150136>
- Nuño-Guzmán CM, Marín-Contreras ME, Figueroa-Sánchez M et al. Gallstone ileus, clinical presentation, diagnostic and treatment approach. *World J Gastrointest Surg*. 2016;8(1):65–76. <https://doi.org/10.4240/wjgs.v8.i1.65>